



Case report

Idiopathic retinal vasculitis, aneurysms and neuroretinitis case report



Tarek Alasil, Scott Ketner, Patrick A. Coady, Ron A. Adelman, Kristen H. Nwanyanwu*

Department of Ophthalmology and Visual Science, Yale University School of Medicine, 40 Temple Street, New Haven, CT 06510, USA

ARTICLE INFO

Article history:

Received 22 January 2016

Received in revised form

8 April 2016

Accepted 12 April 2016

Available online 14 April 2016

Keywords:

IRVAN

Idiopathic retinal vasculitis

Aneurysms and neuroretinitis

ABSTRACT

Purpose: To report a case of idiopathic retinal vasculitis, aneurysms and neuroretinitis (IRVAN) in a young woman.

Observations: A 21-year-old white female patient was referred to retina clinic with decreased vision in the left eye. On examination, best corrected visual acuity was 20/20 in the right eye and counting fingers in the left eye. Fundus examination revealed bilateral optic disc edema, peripapillary and macular exudates, retinal arterial aneurysms, and venous beading. In the left eye, there was a large focus of exudative material in the central macula. Examination of the peripheral retina was unremarkable, bilaterally. Fluorescein angiography demonstrated arterial aneurysms and venous beading in both eyes, with optic nerve activity and vascular sheathing noted on late frames in both eyes. In the left eye, there was a large central area of blockage corresponding to hard exudates surrounding a more central area of hyperfluorescence with leakage, representing retinal neovascularization. Review of systems and extensive laboratory workup were negative. The patient was diagnosed with IRVAN. She was observed, and her exam at 6-month follow-up revealed low grade inflammation for which the patient was started on oral prednisone.

Conclusions and Importance: Management of IRVAN remains challenging because of its idiopathic nature and the lack of controlled clinical trials for such a rare entity. Bilateral involvement in IRVAN is variable and close follow up is crucial.

© 2016 The Authors. Published by Elsevier Inc. This is an open access article under the CC BY-NC-ND license (<http://creativecommons.org/licenses/by-nc-nd/4.0/>).

1. Introduction

Idiopathic retinal vasculitis, aneurysms and neuroretinitis (IRVAN) is a peculiar clinical entity where retinal arteritis with aneurysmal dilatations, retinal ischemia with neovascularization, neuroretinitis, uveitis, and exudative maculopathy can result in vision loss. The disease is rare and characteristically affects young individuals. The term idiopathic refers to the absence of associations with systemic abnormalities [1–3].

Herein, we report a case of a young woman with IRVAN, and we discuss our management approach.

2. Case report

A 21-year-old woman with no significant past medical history was referred to our retina service for evaluation of blurred vision in

the left eye for the past 2 months. Patient received treatment with oral prednisone taper and oral azithromycin by an outside ophthalmologist with no improvement in her vision. On exam, best-corrected visual acuity was 20/20 in the right eye and counting fingers in the left eye. Pupils were round and reactive to light with no relative afferent papillary defect. Anterior segment exam showed no rubeosis. Old vitreous cells were noted in both eyes. Fundus examination revealed bilateral optic disc edema with multiple yellowish peripapillary exudates, arterial aneurysms, and venous beading. There was a large, discrete collection of exudative material in the central macula of the left eye (Fig. 1). Examination of the peripheral retina was unremarkable. Humphrey visual field 24-2 demonstrated enlargement of the blind spot in both eyes with central scotoma in the left eye (Fig. 1). Spectral domain optical coherence tomography (Spectralis OCT, Heidelberg, Germany) showed bilateral peripapillary edema and extensive central macular edema in the left eye (Fig. 2). Fluorescein angiography revealed arterial aneurysms and venous beading in both eyes and, in the left eye, a large central area of hypofluorescence secondary to blockage from the exudative material, with a small, more central area of hyperfluorescence with leakage, representing retinal

* Corresponding author.

E-mail addresses: tarekasil@gmail.com (T. Alasil), Scott.Ketner@yale.edu (S. Ketner), Patrick.Coady@yale.edu (P.A. Coady), Ron.Adelman@yale.edu (R.A. Adelman), K.nwanyanwu@yale.edu (K.H. Nwanyanwu).

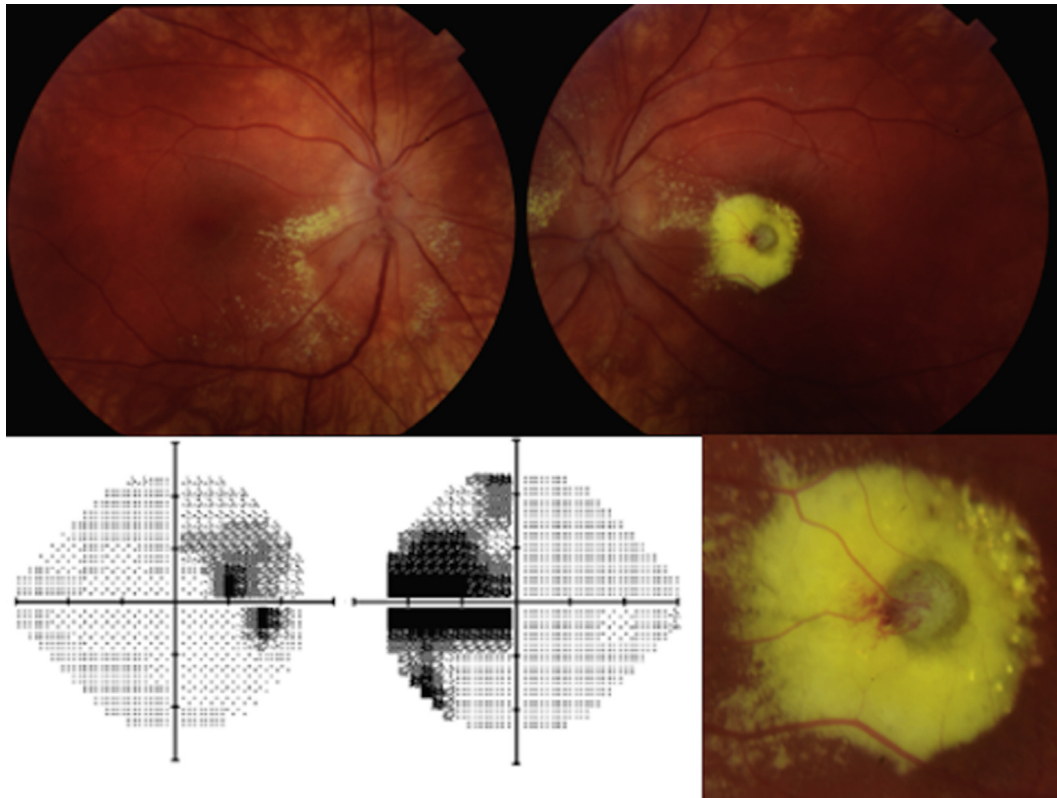


Fig. 1. Color fundus photograph of the right eye shows optic disc swelling with multiple yellowish peripapillary and macular exudates, retinal edema, aneurysmal dilatations of retinal arteries and venous beading. Color fundus photograph of the left eye shows optic nerve swelling and retinal exudates. There is a discrete collection of yellowish exudative material causing retinal swelling and elevation with aneurysmal dilatations of the adjacent retinal arterioles. Humphrey visual field 24-2 test demonstrates enlargement of the blind spot in both eyes and central scotoma in the left eye. (For interpretation of the references to color in this figure legend, the reader is referred to the web version of this article.)

neovascularization. Vascular sheathing was noted on late frames (Fig. 2).

Review of systems was unremarkable. Laboratory workup was negative, including complete blood count, sedimentation rate, C-reactive protein, angiotensin converting enzyme level, antinuclear antibodies, *Bartonella hensela*, *Borrelia burgdorferi*, *Toxoplasma gondii*, quantiferon gold, and fluorescent treponemal antibody absorption tests [Table 1].

The patient was diagnosed with IRVAN. She was observed, and her exam remained stable at the 4-month follow-up visit. At 6-month follow up visit, the patient complained of black shadow in the right eye which was preceded by mild viral prodrome symptoms. Visual acuity remained stable and old vitreous cells were again noted in both eyes. Repeat FA showed increase in arterial aneurysms in the right eye with increased vascular sheathing (Fig. 3). No peripheral neovascularization was noted. Patient was started on oral prednisone 60 mg daily with a slow taper and close follow up.

3. Discussion

IRVAN was first described by Kincaid and Schatz in 1983 [1] and further characterized by Chang et al., in 1995 [2]. It is a diagnosis of exclusion. It usually affects young healthy individuals with female predominance and usually presents in the third or fourth decade of life. The disease has a variable course [2], with visual outcomes ranging from 20/20 to No Light Perception [3]. The presence of retinal vasculitis, aneurysmal arteriolar dilatations, and neuroretinitis represent the major criteria for diagnosing IRVAN. Macular exudation, retinal neovascularization and peripheral capillary non-perfusion are the minor criteria [3].

Many treatment modalities have been used for IRVAN. Steroids—systemic, periocular, and intravitreal—have yielded limited results [3]. Systemic administration of anti-tumor necrosis factor agent infliximab has been reported effective in one instance [4]. Intravitreal injection of anti-vascular endothelial growth factor (anti-VEGF) agents bevacizumab and ranibizumab have been used successfully for macular edema [5–7], as grid laser has been [3,8], though laser photocoagulation of leaking macroaneurysms is not generally recommended because of the branch retinal artery occlusion that it causes and subsequent vision loss from ischemia in the area downstream of the lesion [3]. Multiple reports, including review of the largest number of IRVAN cases to date (44 eyes of 22 patients) by Samuel et al., indicate the importance of panretinal photocoagulation in the presence of widespread retinal ischemia to prevent neovascularization and subsequent vitreous hemorrhage and neovascular glaucoma [3,8]. Nevertheless, the treatment of IRVAN represents a challenge to the retinal specialist, because of the idiopathic nature of the disorder and the lack of controlled clinical trials in such a rare entity.

Our case illustrates the asymmetry between two eyes of a single patient that may be found in IRVAN. While the right eye was initially asymptomatic with 20/20 visual acuity, the left eye visual acuity ranged between 20/400 eccentric and counting fingers. Because the macular exudation in the left eye of our patient was so massive, central, and chronic (color photographs demonstrate the mineralization of some of the exudates on the superotemporal edge of the collection of material, Fig. 1), intravitreal injections of an anti-VEGF agent were thought unlikely to improve vision, and the patient opted for observation. Interestingly, her 6 month follow up exam revealed mild visual symptoms in her right eye and increase in arterial aneurysmal dilation and vascular sheathing after viral

Download English Version:

<https://daneshyari.com/en/article/4006582>

Download Persian Version:

<https://daneshyari.com/article/4006582>

[Daneshyari.com](https://daneshyari.com)