



ARCHIVOS DE LA SOCIEDAD ESPAÑOLA DE OFTALMOLOGÍA

www.elsevier.es/ofthalmologia



Short communication

Severe complication during strabismus surgery[☆]



J. García de Oteyza^{*}, G. García de Oteyza

Clínica García de Oteyza, Barcelona, Spain

ARTICLE INFO

Article history:

Received 13 April 2015

Accepted 13 October 2015

Available online 3 March 2016

Keywords:

Complication in strabismus surgery

Triamcinolone

Retinal artery embolization

Brown's syndrome

ABSTRACT

Clinical case: A 4-year-old patient, who presented with an immediate orbital hematoma as a result of a subtenon injection of triamcinolone in the trochlear region of the right eye on finishing a surgical procedure for Brown's syndrome. After one week, when it could be examined better, the presence of a cherry red spot was observed due to the embolization of the central artery of the retina by triamcinolone crystals.

Discussion: Triamcinolone is an anti-inflammatory drug currently used in ophthalmology for the treatment of various conditions. Although exceptional, it has been described that its use may provoke embolizations due to the entry of the steroid into the circulation.

© 2015 Sociedad Española de Oftalmología. Published by Elsevier España, S.L.U. All rights reserved.

Grave complicación en el transcurso de una cirugía de estrabismo

RESUMEN

Caso clínico: Paciente de 4 años de edad, que como consecuencia de una inyección de triamcinolona subtenoniana en la región de la tróclea del ojo derecho al finalizar una cirugía para el síndrome de Brown presenta un hematoma orbitario inmediato que al cabo de una semana, cuando se pudo explorar mejor, puso en evidencia la presencia de una mancha rojo-cereza secundaria a la embolización de la arteria central de la retina por cristales de triamcinolona.

Discusión: La triamcinolona es un antiinflamatorio de uso corriente en oftalmología para el tratamiento de afecciones variadas. Aunque excepcional, se ha descrito que su utilización puede provocar embolizaciones por entrada del esteroide en la circulación.

© 2015 Sociedad Española de Oftalmología. Publicado por Elsevier España, S.L.U. Todos los derechos reservados.

Palabras clave:

Complicación en cirugía de estrabismo

Triamcinolona

Embolización arterial retiniana

Síndrome de Brown

[☆] Please cite this article as: García de Oteyza J, García de Oteyza G. Grave complicación en el transcurso de una cirugía de estrabismo. Arch Soc Esp Oftalmol. 2016;91:198–203.

^{*} Corresponding author.

E-mail address: jgf7733@comb.cat (J. García de Oteyza).

Introduction

Strabismus surgery is not exempt of complications.¹ The literature describes a range of complications, from simple conjunctival cysts to muscular dislocation and the feared perforation or endophthalmitis.^{1,2} However and despite the broad range of described complications, the authors did not find any as that described below.

Clinic case report

A child, aged 4, brought to the practice by his parents who detected that he deviated his gaze since birth. Motor examination revealed orthophoria in primary position, downshoot in levoversion and difficulty for elevating in all positions, markedly in the field of action of the right lower oblique muscle (Fig. 1). Visual acuity of 20/20 in each eye with sphere of

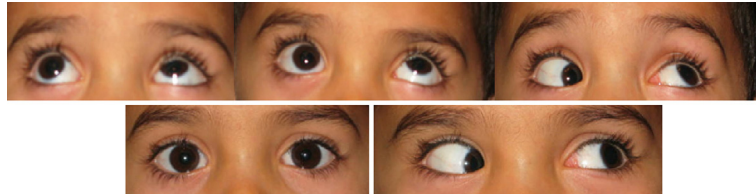

Fig. 1 – Right eye Brown syndrome.

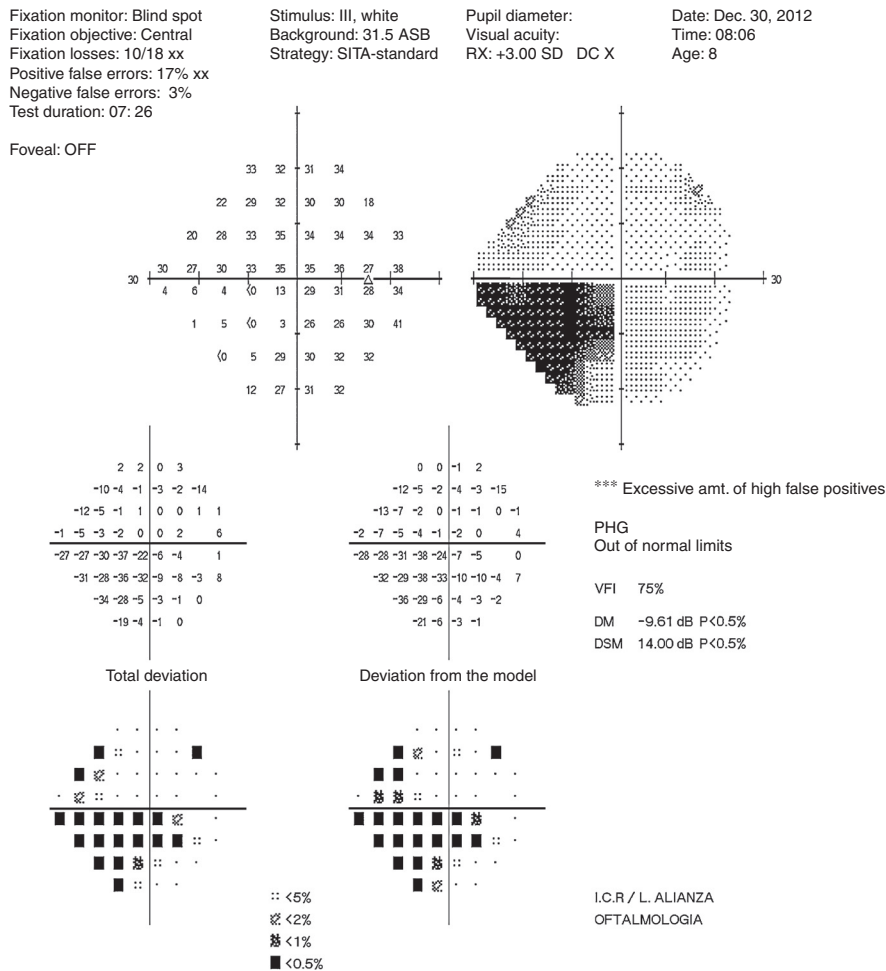


Fig. 2 – Humphrey visual field identifying quadrantanopsia.

Download English Version:

<https://daneshyari.com/en/article/4007994>

Download Persian Version:

<https://daneshyari.com/article/4007994>

[Daneshyari.com](https://daneshyari.com)