

# ARCHIVOS DE LA SOCIEDAD ESPAÑOLA DE OFTALMOLOGÍA

www.elsevier.es/ofthalmologia



## Short communication

# Neovascular membrane and pregnancy. Treatment with bevacizumab<sup>☆</sup>

I. Gómez Ledesma\*, M.Á. de Santiago Rodríguez, I. Follana Neira, F. León Garrigosa

Servicio de Oftalmología, Hospital Universitario Virgen de la Vega, Salamanca, Spain

### ARTICLE INFO

#### Article history:

Received 9 February 2011  
Accepted 12 September 2011  
Available online 16 October 2012

#### Keywords:

Bevacizumab  
Intravitreal injections  
Choroidal neovascularization  
Miscarriage  
Pregnancy

#### Palabras clave:

Bevacizumab  
Inyecciones intravítreas  
Neovascularización coroidea  
Aborto espontáneo  
Embarazo

### ABSTRACT

**Clinical case:** A female in her sixth month of pregnancy, with a history of refractive surgery, consulted due to a metamorphopsia and decrease in visual acuity in the right eye. A presumed ocular histoplasmosis syndrome (POHS) and a subfoveal choroidal neovascular membrane were observed in the funduscopy. Two monthly doses of intravitreal bevacizumab were given after the labor, but the third dose was never injected as the patient became pregnant again. She subsequently had a spontaneous miscarriage.

**Discussion:** During pregnancy treatment with intravitreal bevacizumab during pregnancy is controversial as it may increase the risk of miscarriage during the first trimester.

© 2011 Sociedad Española de Oftalmología. Published by Elsevier España, S.L. All rights reserved.

## Membrana neovascular y embarazo. Tratamiento con bevacizumab

### RESUMEN

**Caso clínico:** Mujer en el sexto mes de gestación, con antecedentes de cirugía refractiva, que consulta por metamorfopsias y disminución de la agudeza visual en el ojo derecho. En la exploración se observa una membrana neovascular coroidea subfoveal asociada al síndrome de presunta histoplasmosis ocular (SPHO). Tras el parto se realiza tratamiento con dos dosis mensuales de bevacizumab intravítreo. La tercera dosis no se realiza por nuevo embarazo, observándose posteriormente aborto espontáneo sin causa conocida.

**Discusión:** El tratamiento con bevacizumab intravítreo durante el embarazo es controvertido, ya que es posible que aumente el riesgo del aborto espontáneo durante el primer trimestre.

© 2011 Sociedad Española de Oftalmología. Publicado por Elsevier España, S.L. Todos los derechos reservados.

<sup>☆</sup> Please cite this article: Gómez Ledesma I, et al. Membrana neovascular y embarazo. Tratamiento con bevacizumab. Arch Soc Esp Oftalmol. 2012;87:297-300.

\* Corresponding author.

E-mail address: igomezledesma@yahoo.com (I. Gómez Ledesma).

## Introduction

The treatment of first choice in choroidal neovascular membranes (CNM) is performed with intravitreal injections of antiangiogenics against the vascular endothelial growth factor (VEGF). The Food and Drug Administration (FDA) has approved both ranibizumab (Lucentis®) and pegaptanib (Macugen®) in CNM associated to age-related macular degeneration. Bevacizumab (Avastin®), a humanized monoclonal antibody that links with all VEGF variants is another antiangiogenic which is gaining acceptance in the treatment for CNM.

In young patients, CNM can be associated to pathological myopia, to presumed ocular histoplasmosis (POH), to internal punctata choroidopathy, etc., and in these cases the treatment of first choice is also intravitreal antiangiogenics.

Other possible treatments for CNM are photodynamic therapy, which is authorized by the FDA for ARMD and POH. Laser photocoagulation is virtually abandoned. Bevacizumab was approved by the FDA as a systemic treatment for colon metastatic carcinoma and other metastatic tumors. The adverse effects of the intravenous administration of this drug include hypertension, arterial thromboembolism episodes and hemorrhages in multiple organs. Bevacizumab is considered to be a class C drug during pregnancy, with unknown risk because in rabbits, after an intravenous injection of bevacizumab in a dose of 1-12 times the dose for humans, in gestational days 6-18 fetal weight reduction has been observed together with teratogenic effect and increased number of abortions.<sup>1</sup>

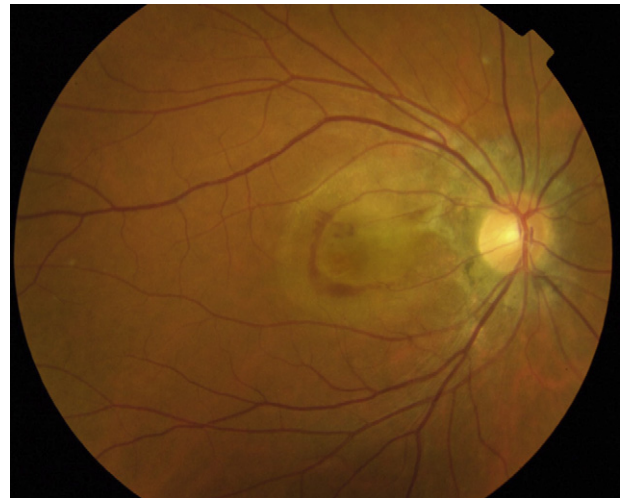
In humans, the concentrations of bevacizumab in plasma after an intravitreal injection are not known even though this has been studied in monkeys<sup>2</sup> and in rabbits.<sup>3</sup> In addition, very low concentrations have been detected in serum. Intravitreal bevacizumab has been used in prematures for treating retinopathy of prematurity. Very small systemic effects are presumed because no complications have been observed in these patients.<sup>4</sup>

## Case report

Female, 41, who visited the practice referring sudden visual acuity reduction and metamorphopsia in the right eye (RE) one month ago. Personal history includes laser in situ keratomileusis (LASIK) in both eyes 9 years ago (5 diopters of presurgery myopia in the RE). Subfoveal CNM was observed, associated to POH in the RE (Figs. 1 and 2). The patient visual acuity (VA) evolved from 0.15 to finger counting (CD) without treatment before giving birth (Fig. 3).

After delivery, two monthly intravitreal injections of bevacizumab (1.25 mg/0.05 ml) were administered in the RE. VA improved from finger counting to 0.15 one month after the first intravitreal injection and 0.2 at month 2 (Figs. 4 and 5). Subsequently, VA diminished slightly (0.15), the CNM became more compact and smaller (Fig. 6). The perilesional subretinal liquid persisted.

The patient was recommended to avoid breast-feeding the baby and avoid a new pregnancy during the treatment. However, in the assessment one month after the second dose the



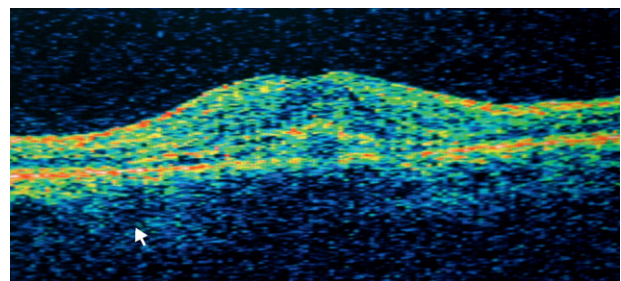
**Fig. 1 – Right eye retinograph during patient pregnancy month 6, showing subfoveal choroidal neovascular membrane (CNM) with perilesional subretinal blood and peripapillary alteration typical of the presumed ocular histoplasmosis (POH).**

patient referred a new pregnancy of about 4 weeks. Scheduled third intravitreal injection was not administered. Subsequently, the patient referred spontaneous abortion without a known cause during the second month of the pregnancy.

## Discussion

Spontaneous abortions described in the literature<sup>1</sup> occur in the fourth and fifth week of pregnancy, while in this case it was in the eighth week. As fetal angiogenesis is particularly important in the first quarter,<sup>5</sup> antiangiogenic treatments could be more sensitive during this period. No teratogenic effect has been described in pregnancies that fulfilled their term while in treatment with intravitreal bevacizumab.<sup>1</sup>

Even though in theory intravitreal bevacizumab during the third quarter could increase the risk of preeclampsia (arterial hypertension<sup>5</sup> and proteinuria have been described as



**Fig. 2 – Optic coherence tomography (OCT). It matches the previous retinograph and confirmed the existence of a choroidal neovascular membrane (CNM) in the right eye, below the neurosensory retina and above the retina pigment epithelium (RPE). The foveal thickening of the retina is noticeable.**

Download English Version:

<https://daneshyari.com/en/article/4008294>

Download Persian Version:

<https://daneshyari.com/article/4008294>

[Daneshyari.com](https://daneshyari.com)