



ARCHIVOS DE LA SOCIEDAD ESPAÑOLA DE OFTALMOLOGÍA

www.elsevier.es/ofthalmologia



Short communication

Antiangiogenic therapy in Sorsby's fundus dystrophy without a mutation in the TIMP-3 gene[☆]

S. Copete-Piqueras*, C. Cava-Valenciano, I. Flores-Moreno, A. Moreno-Valladares, V. Bautista Ruescas

Servicio de Oftalmología, Complejo Hospitalario Universitario de Albacete, Albacete, Spain

ARTICLE INFO

Article history:

Received 2 March 2011

Accepted 23 December 2011

Available online 4 August 2013

Keywords:

Sorsby's fundus dystrophy

TIMP-3

Antiangiogenic therapy

Choroidal neovascularization

Optical coherence tomography

Auto-fluorescence

ABSTRACT

Case report: The case is presented of a 32-year-old man referring to metamorphopsia and blurred vision in both eyes for 3 days. Best corrected visual acuity of 20/32 was found in the right eye and 20/25 in the left eye. Fundus examination revealed the presence of drusen-like deposits, suggestive of Sorsby's fundus dystrophy (SFD) and choroidal neovascularization (CNV) bilaterally. The patient received intravitreal ranibizumab. Visual acuity improved to 20/20 in both eyes at 6-month follow-up, and results of fundus examination showed complete regression of neovascularization. No mutations were found in the TIMP-3 gene.

Discussion: The known mutations in TIMP-3 may not be extended to all patients with SFD. The use of intravitreal ranibizumab may be considered as a therapeutic option in CNV secondary to SFD.

© 2011 Sociedad Española de Oftalmología. Published by Elsevier España, S.L. All rights reserved.

Tratamiento antiangiogénico en fondo de distrofia de Sorsby sin mutación en gen de TIMP-3

RESUMEN

Caso clínico: Varón de 32 años, con metamorfopsias y visión borrosa bilateral de tres días de evolución. Mejor agudeza visual corregida de 20/32 en OD y 20/25 en OI. La funduscopia presenta lesiones amarillentas difusas sugerentes de distrofia de Sorsby y membranas neovasculares (MNV). Recibió tratamiento con ranibizumab intravítreo, mejorando la agudeza visual a 20/20 en ambos ojos y remitiendo las MNV. No se hallaron mutaciones conocidas de TIMP-3.

Discusión: Las mutaciones conocidas en TIMP-3 pueden no estar extendidas a todos los pacientes con fondo de distrofia de Sorsby. El ranibizumab intravítreo debe considerarse para el tratamiento de MNV secundaria a esta enfermedad.

© 2011 Sociedad Española de Oftalmología. Publicado por Elsevier España, S.L. Todos los derechos reservados.

Palabras clave:

Distrofia de Sorsby

TIMP-3

Tratamiento antiangiogénico

Membrana neovascular

Tomografía de coherencia óptica

Autofluorescencia

[☆] Please cite this article as: Copete-Piqueras S, et al. Tratamiento antiangiogénico en fondo de distrofia de Sorsby sin mutación en gen de TIMP-3. Arch Soc Esp Ophthalmol. 2013;88:240-3.

* Corresponding author.

E-mail address: sergioab@hotmail.com (S. Copete-Piqueras).

Introduction

Sorsby's pseudo-inflammatory disease or pseudo-inflammatory macular dystrophy is a rare disease transmitted through dominant autosomic inheritance. It was first described in 1949 by Sorsby et al. and is characterized by the bilateral presence of yellowish lesions (pseudo-drusen) in the posterior pole and equator from early stages. It generally expresses between the fourth and fifth decade of life in the form of nyctalopia or more frequently as bilateral central visual acuity loss secondary to the development of aggressive neovascular membranes (NVM) which give rise to edema, hemorrhage and exudates in the macular area. It generally causes severe visual acuity loss due to the development of disk-shaped scars produced by NVM or the formation of retinal atrophy areas in older patients.

Sorsby's ocular fundus dystrophy has been associated to mutations in the genes which code TIMP-3 (natural tissue inhibitor of metalloproteinases type 3), the main function of which is carried out in Bruch membrane. This situation causes its deposit on said membrane, giving rise to the characteristic spots of the disease and altering proteolysis, thus increasing the risk of generating NVM and atrophy areas.

Case report

A male, 32, was referred for metamorphopsia and subjective visual acuity reduction in both eyes (BE) with onset 3 days before. The patient did not refer personal history of interest or toxic habits and was not able to describe the family history because he was adopted when he was 6 months old. The best corrected visual acuity (BCVA) was of 0.6 in RE and 0.8 in LE. No alterations in intrinsic ocular motility were found. Similarly, no alterations were found and biomicroscopy and the presence of inflammatory signs in the anterior pole were discarded. IOP was within normal limits.

Funduscopy revealed the presence of diffused yellowish deposits (pseudo-drusen) in the macular region (Figs. 1 and 2) and above all in the mid periphery (Fig. 3). Two lesions were found in each eye related to macular subretinal NVM in BE accompanied by edema, hemorrhage and exudate.

OCT confirmed the presence of subretinal liquid (SRL) surrounding the lesions and suggestive of NVM, partially preserving the foveal profile.

Angiography (Fig. 4) evidenced progressive exudation in the NVM from early stages, partially hidden by the screening effect of the hemorrhage and associated to window effect in the pseudo-drusen. Autofluorescence did not exhibit atrophy areas but the diffused yellowish deposits exhibited hyperfluorescence against the rest of the retina.

After discarding infectious pathology, bilateral treatment was established with a single injection of intravitreal ranibizumab.

The genetic study discarded known mutations in axon 5 of gene 22.12.3, in charge of encoding TIMP-3.

At month one of the treatment the patient did not refer metamorphopsia and his BCVA improved up to 0.9 in BE, with diminished presence of SRL in OCT. Accordingly, it was decided

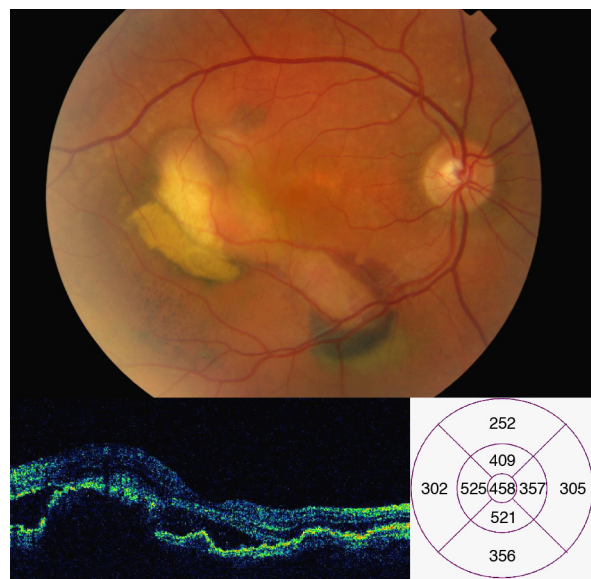


Fig. 1 – Right eye posterior pole at first exploration, showing yellowish lesions and 2 NVM that produce exudation, hemorrhage and edema. OCT confirmed the presence of subretinal liquid and a partially preserved foveal appearance.

not to administer a second treatment and maintain monthly follow-up.

At month 3 the SRL resolved completely (Fig. 5).

After 6 months follow-up the patient referred no visual symptoms and exhibited BCVA of one in BE. No new lesions or atrophy areas have appeared (Fig. 6) and OCT showed no signs of SRL or images evidencing NVM.

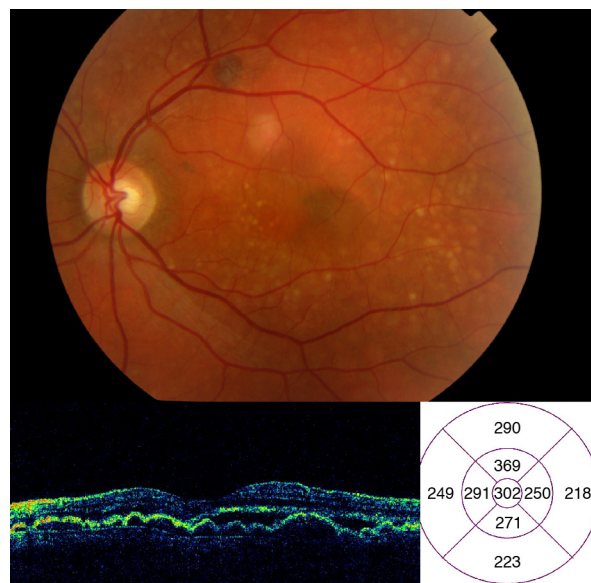


Fig. 2 – LE retinograph, in less evolved stage and with a higher number of yellowish lesions. In addition, it shows 2 lesions that impressed as NVM and had to be confirmed with angiography. OCT reveals the presence of subretinal liquid but in a smaller amount than in the RE.

Download English Version:

<https://daneshyari.com/en/article/4008443>

Download Persian Version:

<https://daneshyari.com/article/4008443>

[Daneshyari.com](https://daneshyari.com)