

ARCHIVOS DE LA SOCIEDAD ESPAÑOLA DE OFTALMOLOGÍA

www.elsevier.es/ofthalmologia



Short communication

Predictive value of optical coherence tomography on the outcome of lung adenocarcinoma with choroidal metastases[☆]

M. García-Fernández*, C. Burgueño-Montañés

Servicio de Oftalmología, Hospital Universitario Central de Asturias, Oviedo, Spain

ARTICLE INFO

Article history:

Received 12 October 2011

Accepted 25 January 2013

Available online 22 March 2014

Keywords:

Choroidal metastases

Optical coherence tomography

Lung adenocarcinoma

Neurosensory detachment

Chemotherapy

ABSTRACT

Clinical case: A 59-year-old male, with the diagnosis of lung adenocarcinoma stage IV, following palliative systemic chemotherapy treatment. He was referred to our department due to bilateral blurred vision. In the eye-fundus we observed: bilateral choroidal metastases with macular involvement, and in optical coherence tomography (OCT): neurosensory detachment in both eyes. This neurosensory detachment showed improvement with chemotherapy before the clinical and radiologic improvement.

Discussion: OCT could be a great tool in order to predict the response to systemic treatment in cases of lung adenocarcinoma associated with choroidal metastases.

© 2011 Sociedad Española de Oftalmología. Published by Elsevier España, S.L. All rights reserved.

Valor predictivo de la tomografía de coherencia óptica en la evolución del adenocarcinoma pulmonar con metástasis coroideas

RESUMEN

Caso clínico: Varón, 59 años, con adenocarcinoma pulmonar estadio IV, en tratamiento paliativo con quimioterapia sistémica. Acude a nuestro servicio por visión borrosa bilateral. En el fondo de ojo se observan metástasis coroideas bilaterales con compromiso macular, y en tomografía de coherencia óptica (OCT) desprendimiento neurosensorial en ambos ojos. Este se reduce drásticamente con el tratamiento quimioterápico, anticipándose a la mejoría clínica y radiológica del paciente.

Discusión: La OCT puede ser una buena herramienta para vaticinar la respuesta al tratamiento sistémico en casos de adenocarcinoma pulmonar asociado a metástasis coroideas.

© 2011 Sociedad Española de Oftalmología. Publicado por Elsevier España, S.L. Todos los derechos reservados.

Palabras clave:

Metástasis coroideas

Tomografía de coherencia óptica

Adenocarcinoma pulmonar

Desprendimiento neurosensorial

Quimioterapia

[☆] Please cite this article as: García-Fernández M, Burgueño-Montañés C. Valor predictivo de la tomografía de coherencia óptica en la evolución del adenocarcinoma pulmonar con metástasis coroideas. Arch Soc Esp Ophthalmol. 2014;89:38–41.

* Corresponding author.

E-mail address: migarci@hotmail.es (M. García-Fernández).

Introduction

Choroidal metastases are the most frequent malign intraocular tumors. The primary tumor which most frequently originates as ocular metastasis is breast carcinoma in females and lung carcinoma in males. They tend to locate in the posterior pole and are bilateral in 25% of cases. They can cause visual acuity loss, scotoma, metamorphopsiae and photopsiae. Approximately 25% of the patients diagnosed for the first time with disseminated breast and lung cancer (stage IV) exhibit metastases in the choroids.

Clinical case

A male, 59 years of age, visited the emergency service of our hospital due to coughing and hemoptoic expectoration beginning 2 months earlier. A chest X-ray revealed consolidation in the upper right lobe; for this reason, the patient was admitted for filiation. A thorax and abdominal computerized action tomography (CAT) was taken (Fig. 1), and aspiration with fine needle (PAAF) of the lesion with a diagnosis of stage IV lung adenocarcinoma (WHO grade: 0), with liver and spleen metastases, peri-pancreatic adenopathy as well as blastic implants in the spine.

Due to the advanced stage of the patient, palliative chemotherapy treatment was initiated within the TITAN protocol with cisplatinum 145 mg + taxotere 145 mg.

One week after beginning chemotherapy, the patient visited our practice due to bilateral blurred vision and myodesopsiae.

The ophthalmological examination evidenced a best corrected visual acuity (BCVA) of 0.25 (decimal notation) in both eyes. Anterior pole biomicroscopy and intraocular pressure were normal. Ocular fundus examination evidenced predominantly inferior leopard-skin raised choroidal masses involving the macula, compatible with bilateral choroidal metastasis (Fig. 2).

Spectral domain optic coherence tomography (OCT) (Cirrus HD-OCT, Carl Zeiss Meditec, Germany) revealed submacular hyporeflective area corresponding to neurosensory retina detachment, which was broader in the left eye (LE) as well as

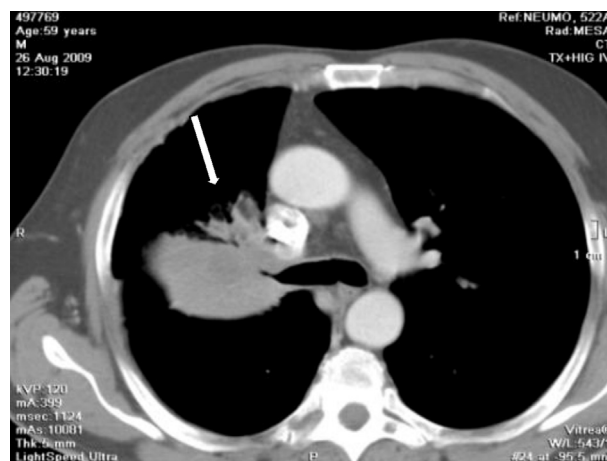


Fig. 1 – Computerized axial tomograph showing the presence of large irregular tumor mass in the upper lobe of the right lung.

irregularities in the choriocapillary retina pigment epithelium complex (RPE) in both eyes. In addition, the NDA evidenced small hyper-reflective areas inside the hyporeflective subretinal space, possibly related to tumor cells. Similarly, the right eye (RE) evidenced small intraretinal splits or separation areas, predominantly from nasal to the fovea. Also a small initial epiretinal membrane (ERM) was observed in both eyes (Fig. 3).

Two months after beginning chemotherapy, the patient visited the practice again for examination, referring subjective VA improvement.

BCVA was 0.4 in RE and 0.6 in LE. Anterior pole biomicroscopy remained unchanged. Funduscopy was similar to the previous examination and did not evidence signs of progression. However, posterior pole OCT evidenced significant improvements with neuroepithelium detachment reduction in both eyes (Fig. 4), which seemed to correlate with said VA functional improvement.

The patient concurrently visited the Oncology Service for examination, evidencing clinical and radiologic improvement (Fig. 5), and for this reason chemotherapy was continued.

Ten months after beginning the therapy the patient again visited our service, exhibiting a BCVA of 0.7 in RE and 0.8 in

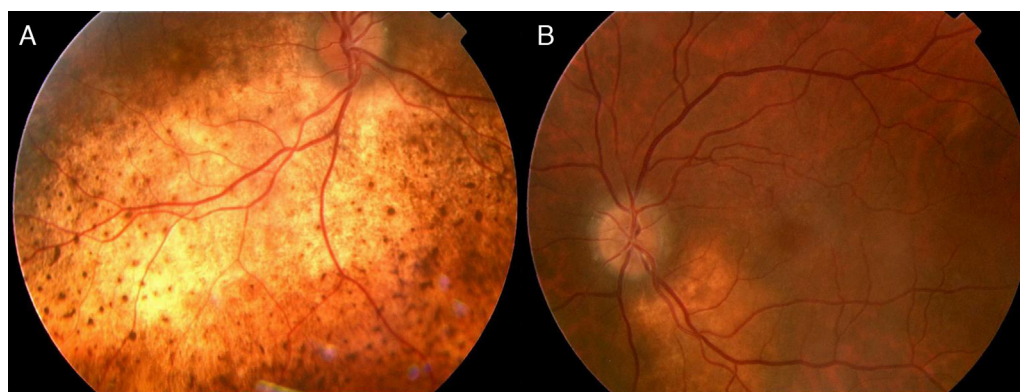


Fig. 2 – (A) Funduscopy appearance of the right eye at diagnosis, showing dotted, whitish-yellowish elevated mass, predominantly in the inferior temporal area and (B) LE funduscopy appearance at diagnosis, showing smaller nacre-like mass at the inferior temporal arcade. Both are compatible with choroidal metastasis.

Download English Version:

<https://daneshyari.com/en/article/4008537>

Download Persian Version:

<https://daneshyari.com/article/4008537>

[Daneshyari.com](https://daneshyari.com)