



## Brief communication

## Clinical characters and treatments of retinal vasoproliferative tumors

Yi-Ming Huang<sup>a, \*</sup>, Shih-Jen Chen<sup>a, b</sup><sup>a</sup> Department of Ophthalmology, Taipei Veterans General Hospital, Taipei, Taiwan, ROC<sup>b</sup> Department of Ophthalmology, School of Medicine, National Yang-Ming University, Taipei, Taiwan, ROC

## ARTICLE INFO

## Article history:

Received 2 November 2015

Received in revised form

5 April 2016

Accepted 9 April 2016

Available online 24 May 2016

## Keywords:

retinal vasoproliferative tumors

VPT

PDT

## ABSTRACT

Retinal vasoproliferative tumors (VPT) are uncommon benign vascular tumors. They mostly occur in healthy patients, but may be associated with other chorioretinal diseases. Here we report four patients with VPT at a referral center from 2006 to 2015. Three patients denied any past history and one had a history of retinal detachment surgery. VPT-related complications included epiretinal membrane (ERM) ( $n = 2$ ), cystoids macular edema ( $n = 1$ ), and lamellar hole combined with dense cataract, rigid anterior capsule and vitreous opacity ( $n = 1$ ). Treatments for VPT and comorbidities included vitrectomy (VT) and membrane peeling with tumor resection ( $n = 2$ ), a combined treatment of photodynamic therapy (PDT) and intravitreal injection (IVI) of anti-vascular endothelial growth factor (anti-VEGF) ( $n = 2$ ). Tumor shrinkage was achieved in both patients treated with PDT and IVI of anti-VEGF injection. The other two patients with ERM were successfully treated with VT and tumor resection. Visual acuity improved at least two lines in three patients, and one patient had decreased vision due to cataract formation after VT. Pathology of the resected tumor in one case revealed massive gliosis with positive stain of vascular endothelial cells and glial fibrillary acidic protein stain. Yet the peeled membrane was acellular. Possible beneficial treatments for VPT and comorbidities include PDT combined with IVI of anti-VEGF, or VT and membrane peeling with tumor resection.

Copyright © 2016, The Ophthalmologic Society of Taiwan. Published by Elsevier Taiwan LLC. This is an open access article under the CC BY-NC-ND license (<http://creativecommons.org/licenses/by-nc-nd/4.0/>).

## 1. Introduction

Retinal vasoproliferative tumors (VPT) are rare, unilateral and benign retinal vascular tumors. They are yellowish-red tumors, and are mostly located on the inferotemporal peripheral retina. Unlike the retinal hemangioblastoma, VPT rarely have dilated and inflamed feeder or drainage vessels, and they demonstrate a paucity of microvessels yet a preponderance of gliosis.<sup>1</sup>

VPT mostly occur in middle-aged patients who are healthy (primary VPT), or they may be associated with other chorioretinal diseases such as uveitis, retinitis pigmentosa, and Coats' disease. They may also occur after retinal detachment surgery (secondary VPT).<sup>2–6</sup> Most patients suffer from visual symptoms that are secondary to leakage and inflammation of this peripheral vascular tumor, such as decreased vision, floater, distortion, or photopsia.<sup>7,8</sup> Without dilating the pupil and checking the peripheral retina, the

VPT might be missed. Visual acuity (VA) varied from light perception to 6/6, depending on the complications of VPT.<sup>7,8</sup> The clinical course was generally insidious and slow but exudative retinal detachment with macula involvement or neovascular glaucoma has been reported.<sup>8,9</sup>

To the best of our knowledge, only one case of VPT has been orally presented at the annual meeting of the Taiwan Ophthalmology Society in 2013 by Chu & Wang, and another possible case of VPT has been published in one report.<sup>10</sup> In this study, we report four cases of VPT. Two patients had more than 8 years of follow-up. The clinical presentation, treatment and outcome, as well as the histopathology of the tumor are described.

## 2. Case reports

Four patients with VPT were recruited following a chart review from 2006 to 2015. Three healthy females with an average age of 49 years had primary VPT without prior ocular history or surgery. One 84-year-old male had a history of retinal detachment surgery. Initial best-corrected VA was less than 6/12 in all patients (average Snellen acuity of 6/24). After fundus examination, two patients had a yellowish-red tumor at the temporal lower periphery (primary

Conflicts of interest: All authors declare no conflicts of interest.

\* Corresponding author. Department of Ophthalmology, Taipei Veterans General Hospital, 201, Section 2, Shih-Pai Road, Taipei 112, Taiwan, ROC.

E-mail addresses: [nowaytokyo@gmail.com](mailto:nowaytokyo@gmail.com), [nowaytokyo@yahoo.com.tw](mailto:nowaytokyo@yahoo.com.tw) (Y.-M. Huang).

<http://dx.doi.org/10.1016/j.tjo.2016.04.003>

2211-5056/Copyright © 2016, The Ophthalmologic Society of Taiwan. Published by Elsevier Taiwan LLC. This is an open access article under the CC BY-NC-ND license (<http://creativecommons.org/licenses/by-nc-nd/4.0/>).

VPT), one at the nasal lower periphery (primary VPT), and one at the temporal upper periphery (secondary VPT) (Table 1).

### 2.1. Case 1

In 2006, a 41-year-old female presented with blurred vision in the left eye. The rapid and dense epiretinal membrane (ERM) was noted just 3 weeks after her first visit (Figure 1). VA also dropped from 6/7.5 to 6/60. Due to a progressive thickening of the ERM and worsening VA, we promptly performed vitrectomy (VT), membrane peeling, and external tumor resection. VA improved to 6/8.6 in 6 months after surgery and this was maintained for 6 years until the last visit.

### 2.2. Case 2

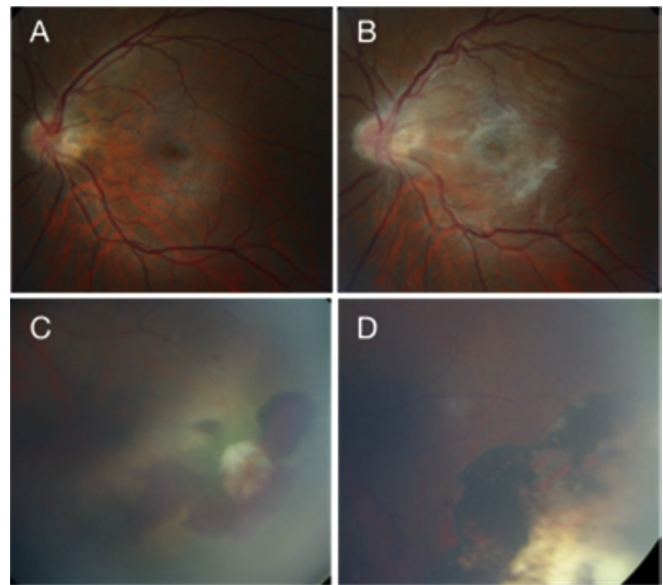
This was an 84-year-old male with a history of retinal detachment surgery and cataract surgery 3 years previously. The tumor was located at the border of an old chorioretinal scar at the temporal upper periphery on the left eye (Figure 2). Cystoid macular edema was found on optical coherence tomography (OCT). He received three intravitreal injections (IVI) of bevacizumab and two treatments of photodynamic therapy (PDT). As a result, the tumor shrank and the macular was flat. VA improved from 6/15 to 6/10 and was maintained for 6 years.

### 2.3. Case 3

Case 3 was a 58-year-old female with VA of 6/30 in her right eye. A slit-lamp examination showed a dense cataract. Indirect ophthalmoscopy revealed VPT with lipid exudate, vitreous opacity with fibrin sheet, and lamellar hole (Figure 3). She also received IVI of ranibizumab (twice) and PDT (once). We then performed phacoemulsification and intraocular lens implantation 9 months after the PDT. A very rigid and resistant anterior capsule was found during the cataract surgery. After 1 month, severe anterior capsule contraction was noted. Following neodymium-doped yttrium aluminum garnet (Nd:YAG, Lightex Inc) laser anterior capsulotomy, the VA improved to 6/10.

### 2.4. Case 4

A 48-year-old female presented with blurred vision of the right eye. VPT and ERM were diagnosed, and two treatments of IVI of



**Fig. 1.** Color fundus of Case 1 (A) at presentation; (B) rapid and dense ERM occurred after 3 weeks; (C) VPT with retinal hemorrhage and pigmented retina change; and (D) disappearance of tumor with chorioretinal scar after VT, membrane peeling, and tumor resection. ERM = epiretinal membrane; VPT = vasoproliferative tumor; VT = vitrectomy.

ranibizumab and one of PDT were carried out before the planned surgery in order to shrink the tumor. Six weeks after PDT, we performed VT, membrane peeling, and tumor resection (Figure 4). To avoid intraoperative bleeding, under general anesthesia, systolic blood pressure was controlled between 80–100 mmHg during the procedure of tumor resection. The tumor was located by indirect ophthalmoscopy and a 6 × 4 mm sclera lamellar flap was made. Diathermy was carried out on the margin of the exposed choroid under the deep scleral flap with careful cauterization to reduce bleeding, followed by resection of the choroid and the tumor with scissors, along with the deep scleral flap. The superficial scleral flap was covered back and sutured, with additional transscleral cryotherapy along the scleral flap. VT was then performed. During the VT, no posterior vitreous detachment (PVD) was found and the ERM was adherent to the posterior hyaloid membrane. After carefully isolating and removing the ERM, the underlying internal limiting membrane (ILM) was found to be intact and was subsequently

**Table 1**  
Demographic and clinical data of the four patients with VPT.

	Case			
	1	2	3	4
Age	41	84	58	48
Gender	F	M	F	F
Eye	OS	OS	OD	OD
Location	Inferotemporal	Superotemporal	Inferotemporal	Inferonasal
Previous history	Nil	RD surgery	Nil	Nil
Initial VA	6/60	6/15	6/30	6/12
Complication	ERM	Cystoid macular edema	Lamellar hole, dense cataract with rigid anterior capsule and vitreous opacity	ERM
Treatment	VT + MP + tumor resection, Phaco-IOL	PDT + IVI of bevacizumab	PDT + IVI of ranibizumab, Phaco-IOL	PDT + IVI of ranibizumab, VT + MP + tumor resection
Follow-up time	9 years	8 years	10 months	7 months
Final VA	6/8.6	6/10	6/10	6/15

ERM = epiretinal membrane; IVI = intravitreal injection; MP = membrane peeling; PDT = photodynamic therapy; Phaco-IOL = phacoemulsification and intraocular lens implantation; RD = retinal detachment; VA = visual acuity; VT = vitrectomy.

Download English Version:

<https://daneshyari.com/en/article/4033310>

Download Persian Version:

<https://daneshyari.com/article/4033310>

[Daneshyari.com](https://daneshyari.com)