

Technical Note

Endoscopic Extracapsular Capsulectomy of the Elbow: A Neurovascularly Safe Technique for High-Grade Contractures

Srinath Kamineni, F.R.C.S., Felix H. Savoie III, M.D., and Neil ElAttrache, M.D.

Abstract: Arthroscopic management of elbow contractures is rapidly becoming the primary operative form of treatment for many physicians. Safety concerns remain the primary limiting factor in its more widespread use. We use an extra-articular starting point in extremely difficult fixed contractures, and this technique is documented in this report. The ulnar nerve is initially identified and protected with a palpating finger, while a periosteal elevator is introduced through a proximal medial skin portal. A channel between the anterior humeral cortex and anterior musculature is created, and an arthroscope is introduced through a proximal lateral portal at the lateral aspect of the channel. The anterior capsule is dissected from the musculature/neurovasculature under direct vision and safely excised once the medial and lateral margins are safely identified. A useful technical tip is that retractors can be placed in auxiliary portals to deflect the muscles and fat pad to improve the ability to perform dissection under direct vision. **Key Words:** Elbow—Stiffness—Arthrofibrosis—Arthroscopy.

Elbow contractures that require operative intervention to improve range of motion are difficult problems not to be underestimated. Management by capsulotomy or capsulectomy has been described by open¹ and arthroscopic techniques.² Whereas most arthroscopic operations tend to convert an open technique into one with the use of minimally invasive equipment, the capsular procedures do not. Invariably, the elbow arthroscopist's first goal is to enter the joint capsule. However, joint spaces are not always the spaces to be visualized, as

in the cases of subacromial and scapulothoracic bursoscopy. The joint space in the elbow with up to a 45° contracture is consistently adequate for easy entry by standard arthroscopic methods. However, with higher-grade contractures, in which the capsule is abnormal in structure and contracted, the safe consistency of entering the joint cavity with standard arthroscopic techniques is diminished.³ In addition to the technical difficulty of entering and working within such a confined space, the relation of the neurovasculature to the capsule is often altered, and iatrogenic neurovascular injury is a major concern.^{4,5} Our aim was to develop a reliable technique of endoscopic anterior capsulectomy that eliminates the risk to neurologic structures in the high-grade contracted elbow not complicated by heterotopic ossification.

SURGICAL TECHNIQUE

The patient is positioned in a lateral decubitus position. The elbow, with a pneumatic tourniquet positioned but not inflated, is supported on a custom elbow holder allowing the elbow to flex under gravity to 110°. The bony landmarks of the olecranon tip, medial epicondyle, lateral epicondyle, and radiocapitellar

From the Department of Elbow, Shoulder, and Upper Limb Surgery (S.K.), and Department of Bioengineering (S.K.), Brunel University, Uxbridge, England; Department of Orthopaedics and Trauma (S.K.), Cromwell Hospital, London, England; Upper Extremity Service, Mississippi Sports Medicine and Orthopaedic Center (F.H.S.), Jackson, Mississippi, U.S.A.; Department of Orthopaedic Surgery, University of Mississippi Medical School (F.H.S.), Jackson, Mississippi, U.S.A.; and Kerlan-Jobe Orthopaedic Clinic (N.E.), Los Angeles, California, U.S.A.

Address correspondence and reprint requests to Srinath Kamineni, F.R.C.S., Department of Orthopaedics and Trauma, Cromwell Hospital, Cromwell Rd, London SW5 0TU, England. E-mail: Srinathkamineni@gmail.com

© 2007 by the Arthroscopy Association of North America
0749-8063/07/2307-4619\$32.00/0
doi:10.1016/j.arthro.2006.10.004

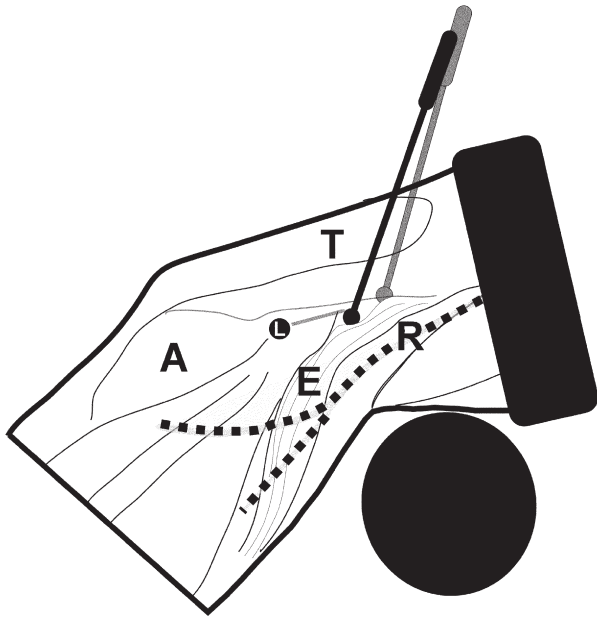


FIGURE 1. The initial skin incision is made 1 cm anterior to the midlateral line to elevate the extensor carpi radialis longus (E) and brachioradialis, thereby elevating the radial nerve (R) away from the plane of dissection. (A, anconeus; T, triceps; L, lateral epicondyle.)

joint are all marked with a marker pen. The ulnar nerve is palpated and confirmed to be in the cubital tunnel, and if a subluxating ulnar nerve is preoperatively diagnosed, the angle of flexion of subluxation is noted and the excursion of the nerve is marked. When a subluxating nerve is present, the operator should not remove his or her palpating/reducing finger from the nerve, which is maintained in the cubital tunnel and posterior to the supracondylar ridge, until the tourniquet is inflated, the proximal medial skin incision is made, and the medial instrument is introduced.⁶

An initial skin portal incision is made 1 cm anterior to the midlateral line of the arm (Fig 1), at a height, from the apex of the lateral epicondyle, of one quarter of the transepicondylar distance (Fig 2). A curved arthroscopic periosteal elevator is introduced into the portal between the skin and muscle, and the tip is immediately directed posteriorly to reach the lateral intermuscular septum. Once the elevator tip encounters the septum, a channel is created across to the medial aspect of the elbow, with the elevator tip maintained firmly on the anterior cortex of the humerus. The channel so created is bounded by the anterior humeral cortex on the deep surface and the brachioradialis/brachialis on the superficial surface. Once the elevator has passed the bone and muscle, it is passed more medially until it tents the medial skin, anteromedial to the medial supracondylar ridge. Dur-

ing this whole initial maneuver, the ulnar nerve is maintained in the cubital tunnel location by the operator's index finger. A 1-cm skin incision is made over the tented skin, the elevator is pushed through, an arthroscopic outer sleeve is introduced onto the tip of the elevator, and the conjoint unit is withdrawn to the level of the midline humerus. The arthroscopy sleeve and periosteal elevator are disengaged, and the arthroscope is introduced into the sleeve, thereby creating the proximal anteromedial viewing portal, as well as a proximal anterolateral working portal.

The proximal medial viewing portal is anterior to the plane of the supracondylar ridge but can be used to view as far as the coronoid process of the proximal ulna medially and the radial neck laterally. Once the arthroscope is introduced, a periosteal elevator and scissors are used to develop the plane between the anterior humerus/ anterior elbow capsule and the brachialis. The elevation of the brachioradialis and brachialis is performed first to create a defined anterior-lateral capsule to a distal extent at which the radial head can be palpated through the capsule with the elevator (Fig 3). Once this lateral corridor is cleared, the process is progressed medially to the medial extent of the sublime tubercle distally, again palpable with the elevator. The landmarks to ensure that the anterior capsule is completely freed are the radial head fossa proximolaterally, radial neck distolaterally, coronoid fossa proximomedially, and the medial sublime tubercle distomedially. Not extending the dissection lateral or medial to these landmarks also ensures the safety of the collateral ligaments.

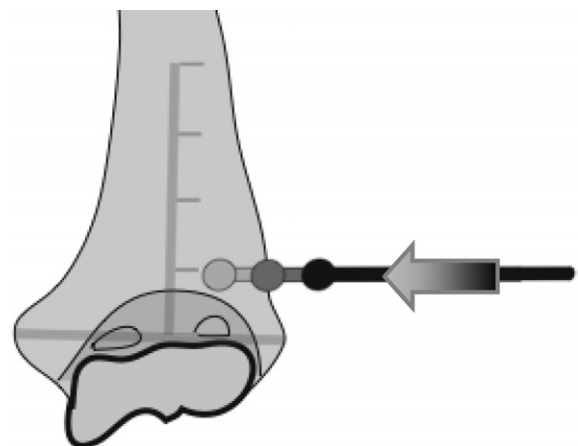


FIGURE 2. The location of the initial skin incision is one-quarter length of the transepicondylar distance, which is projected caudad from the apex of the lateral epicondyle. This level above the lateral epicondyle will ensure that the apex of the capsule is just distal to the periosteal elevator when beginning the dissection. The transepicondylar distance is depicted as a gray line.

Download English Version:

<https://daneshyari.com/en/article/4046713>

Download Persian Version:

<https://daneshyari.com/article/4046713>

[Daneshyari.com](https://daneshyari.com)