

Original article

Transfer of the rhomboid nerve to the suprascapular nerve: An anatomical feasibility study

Transfert du nerf du rhomboïde sur le nerf suprascapulaire : étude anatomique de faisabilité

J.-N. Goubier*, F. Teboul

Brachial plexus and peripheral nerve surgery institute, 92, boulevard de Courcelles, 75017 Paris, France

Received 12 April 2015; received in revised form 5 May 2015; accepted 12 May 2015

Available online 6 July 2015

Abstract

Paralysis of the suprascapular nerve, in partial injuries of the brachial plexus, most often warrants a nerve transfer. Transfer of the spinal accessory nerve to the suprascapular nerve is performed most often. We propose to directly transfer the nerve of the rhomboid muscles (branch of the dorsal scapular nerve) to the suprascapular nerve in the supraspinatus fossa. This anatomical study included 10 shoulders. Dissection of the suprascapular nerve and the branch of dorsal scapular nerve to rhomboid muscles (rhomboid nerve) was performed through a posterior approach. Once the nerves were freed, the possibility of suturing the two nerves together was evaluated. Tensionless suture of the rhomboid nerve to the suprascapular nerve was possible in all shoulders in this study. In addition, the diameter of the two nerves was macroscopically compatible: the average diameter of the rhomboid and suprascapular nerve was 2.9 and 3 mm, respectively. The diameter of the rhomboid nerve is more suitable than that of the spinal accessory nerve for a transfer to the suprascapular nerve. Moreover, the spinal accessory nerve is preserved in this technique, thereby preserving the function of the trapezius muscle, which could be used for muscle transfer if the nerve surgery fails. In addition, use of the rhomboid nerve allows the suture to be performed downstream to the suprascapular notch and avoids poor results linked to multilevel injuries of this nerve. Finally, if the posterior approach is extended laterally, associated transfer of the nerve to the long head of the triceps brachii to the axillary nerve is also possible. Rhomboid nerve transfer to the suprascapular nerve is anatomically possible. A clinical study will now be necessary to confirm this hypothesis and set out preliminary results.

© 2015 Elsevier Masson SAS. All rights reserved.

Keywords: Rhomboid nerve; Dorsal scapular nerve; Suprascapular nerve; Spinal accessory nerve; Nerve transfer; Brachial plexus

Résumé

Les paralysies du nerf suprascapulaire, dans les atteintes partielles du plexus brachial, justifient le plus souvent un transfert nerveux. Le transfert du nerf spinal accessoire sur le nerf suprascapulaire est le transfert le plus réalisé. Nous proposons, dans le cadre d'une étude anatomique, un transfert direct du nerf destiné aux muscles rhomboïdes, branche du nerf dorsal de la scapula, sur le nerf suprascapulaire dans la fosse supra-épineuse. Cette étude a été menée sur 10 épaules. Une dissection du nerf suprascapulaire et du nerf des rhomboïdes par voie postérieure a été réalisée. Une fois les nerfs libérés, la possibilité d'une suture entre les deux nerfs a été évaluée. La suture, sans tension, du nerf des rhomboïdes sur le nerf suprascapulaire a toujours été possible dans notre étude. De plus, il n'y avait pas macroscopiquement d'incohérence de diamètre entre les deux nerfs : le diamètre moyen du nerf des rhomboïdes était de 2,9 mm et celui du nerf suprascapulaire était de 3 mm. Le diamètre du nerf des rhomboïdes correspond parfaitement à celui du nerf suprascapulaire. De plus, il permet d'éviter le sacrifice du nerf spinal accessoire, conservant ainsi la fonction du muscle trapèze, alors transférable en cas d'échec de la chirurgie nerveuse. Il permettrait de plus de réaliser la suture en aval de l'incisure scapulaire (supérieure) et d'éviter les mauvais résultats liés aux lésions étagées de ce nerf. Enfin la voie d'abord postérieure permet, lorsqu'elle est prolongée latéralement, de réaliser un transfert associé du nerf du chef long du triceps brachial sur le nerf axillaire. Ce transfert du

* Corresponding author.

E-mail address: jngoubier@gmail.com (J.N. Goubier).

nerf des rhomboïdes sur le nerf suprascapulaire est anatomiquement possible. Cependant, une étude clinique sera nécessaire afin de confirmer cette hypothèse et de donner des résultats préliminaires.

© 2015 Elsevier Masson SAS. Tous droits réservés.

Mots clés : Nerf du rhomboïde ; Nerf dorsal de la scapula ; Nerf suprascapulaire ; Nerf spinal accessoire ; Transfert nerveux ; Plexus brachial

1. Introduction

Partial paralysis of the brachial plexus represents approximately 25% of plexus injuries [1]. In paralysis of the C5 and C6 roots, restoring elbow flexion and shoulder elevation is the main objective. If the roots are ruptured, one of the most used and most reliable nerve transfers remains that of the external branch of the spinal accessory nerve to the suprascapular nerve; this restores abduction and/or external rotation of the shoulder [2].

However, the difference in diameter between the spinal accessory and suprascapular nerves can reduce the quality of supraspinatus and infraspinatus muscle reinnervation [3,4]. Moreover, this transfer partially sacrifices trapezius function, a muscle fundamental to shoulder function [5]. In addition, the suprascapular nerve can be injured at several levels, from its origin to the suprascapular notch [6]. In this case, anterior transfer of the spinal accessory nerve to the suprascapular nerve is not always effective or justifies undertaking multiple surgical approaches.

Thus, we undertook an anatomical study to evaluate the possibility of performing a direct transfer of the rhomboid nerve to the suprascapular nerve in the supraspinatus fossa.

2. Materials and methods

This study was performed on 5 fresh cadavers (10 shoulders). A posterior incision was made along the spine of the scapula. The trapezius was detached close to its scapular insertion to access the supraspinatus fossa. Next, the deep aspect of the supraspinatus muscle was detached to access the suprascapular notch. The suprascapular nerve was located and then freed by sectioning the transverse scapular ligament to obtain the maximal length necessary for the subsequent suture.

The levator scapulae muscle was detached from the medial border of the scapula, and then retracted to expose the deep aspect of the dorsal scapular nerve. Once exposed, the branches to the levator scapulae muscle and the rhomboid muscle were isolated. The branch for the rhomboid muscle was freed as far as possible in the muscle and in the dorsal scapular nerve to obtain the maximum length. The branch was then sectioned close to the muscle and was brought into contact with the suprascapular nerve (Fig. 1).

The excess length when two nerves overlap was measured with a digital caliper (Cogex, France) to determine the possibility of performing a tensionless suture. In addition, the diameter of the two nerves was measured.

3. Results

In all cases, the distance between the two nerve ends (suprascapular and rhomboid nerves) was small enough that they could be brought together without placing tension on them (Fig. 2). The two nerves always had excess length available. The average excess length was 3.1 mm (range 2 to 4 mm).

The average diameter of the rhomboid nerve was 2.9 mm (range: from 2 to 4 mm) and the suprascapular nerve 3 mm (range: from 2 to 4 mm).

4. Discussion

The dorsal scapular nerve arises from the C5 and C4 roots and occasionally from the C3 and C6 roots [7,8]. In most publications, the dorsal scapular nerve is one single nerve. It penetrates the middle scalene muscle, runs on the ventral side of the levator scapulae muscle and continues to the ventral side of rhomboid muscles near the medial border of the scapula [7,8].

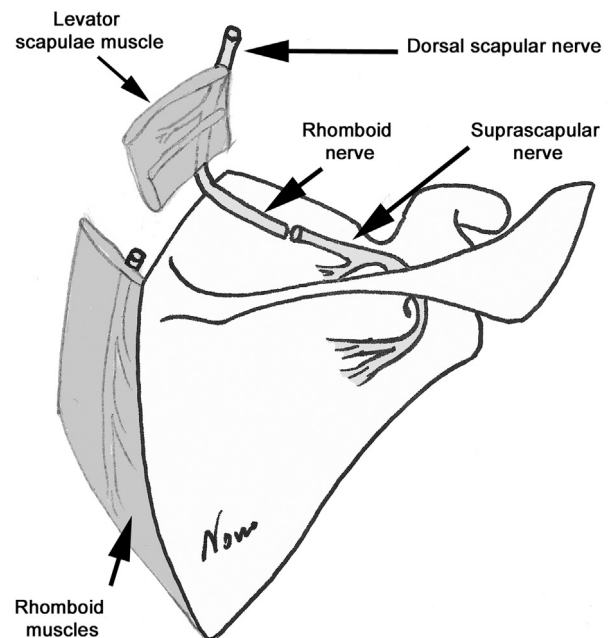


Fig. 1. Drawing that shows the principle behind transferring the nerve to the rhomboid muscles (terminal branch of the dorsal scapular nerve) to the suprascapular nerve downstream of the suprascapular notch. The levator scapulae muscle is detached from the medial border of the scapula to expose the rhomboid nerve. The rhomboid nerve is divided close to the rhomboid muscle to obtain the maximal possible length and diameter. The suprascapular nerve has been divided at the suprascapular notch and rerouted to rhomboid nerve.

Download English Version:

<https://daneshyari.com/en/article/4048652>

Download Persian Version:

<https://daneshyari.com/article/4048652>

[Daneshyari.com](https://daneshyari.com)