



## Original Article

# Ultrasonography of median nerve mobility in the diagnosis of carpal tunnel syndrome

Yi-Ho Hsieh, Jui-Tien Shih\*, Hung-Maan Lee, Yuh-Jiun Ho

Department of Orthopedics, Armed Forces Taoyuan General Hospital, Taoyuan, Taiwan

## ABSTRACT

### Keywords:

carpal tunnel syndrome  
median nerve mobility  
ultrasound

**Background:** Few studies on median nerve mobility in carpal tunnel were reported. The purpose of this study was to observe median nerve mobility in the carpal tunnel dynamically with ultrasound during wrist and fingers flexion and extension and define the abnormality between normal people and patients with carpal tunnel syndrome.

**Materials and Methods:** Thirty-two persons without symptoms of carpal tunnel syndrome and 18 patients with symptoms of carpal tunnel syndrome (10 patients confirmed by nerve conduction velocity/electromyography) were evaluated by high-resolution ultrasound (the SonoSite Titan high-resolution ultrasound; transducer: 5–10 MHz, 38-mm broadband linear array) with wrist and fingers in flexion and extension positions. The motions of median nerve and flexor tendons were observed.

**Result:** In our observation, median nerve will move from the volar side of the flexor tendons to the dorsal side of the flexor tendons smoothly through the tract between flexor pollicis longus and flexor digitorum superficialis of index when wrist and fingers flexed. In patients with carpal tunnel syndrome, the normal mobility of median nerve was absent. In 18 patients with carpal tunnel syndrome symptoms, there were 17 patients (94%) with positive findings in ultrasound examination. In 32 persons without the symptom of carpal tunnel syndrome, there were four cases with positive findings.

**Conclusions:** Median nerve has mobility in the carpal tunnel. In patients with carpal tunnel syndrome, the mobility was absent. Ultrasonography of median nerve mobility is helpful in diagnosing carpal tunnel syndrome. Its reliability and sensitivity should be further evaluated.

Copyright © 2010, Taiwan Orthopaedic Association. Published by Elsevier Taiwan LLC. All rights reserved.

## 1. Introduction

The carpal tunnel is bordered dorsally by the concave arch of the carpus and volarly by the transverse carpal ligament. Ten structures from the volar forearm pass

through the carpal tunnel—nine flexor tendons and the median nerve. The median nerve is the most superficial structure within the canal, entering the space in the midline or just radial to the midline. Carpal tunnel syndrome is the most common compressive neuropathy of

\* Corresponding author. Jui-Tien Shih, Department of Orthopedics, Armed Forces Taoyuan General Hospital, 168 Chung-Shin Road, Taoyuan, Taiwan. Tel.: +886 3 4993070; fax: +886 3 4898976.

E-mail address: [dilantin11@yahoo.com.tw](mailto:dilantin11@yahoo.com.tw) (J.-T. Shih).

the upper extremity. As a result of median nerve compression, the patient reports pain, weakness, and paresthesia in the hand and digits. The diagnosis is based on the patient's history and physical examination and is confirmed by electrodiagnostic testing. The underlying pathophysiology is not well understood (Sen et al<sup>1</sup>) and, most studies put their focus on increased carpal tunnel pressure. There are few reports about median nerve mobility in the carpal tunnel. Longitudinal excursion (Szabo et al,<sup>2</sup> Wilgis and Murphy,<sup>3</sup> Wright et al,<sup>4</sup> Dilley et al,<sup>5</sup> Hough et al,<sup>6</sup> and McLellan and Swash<sup>7</sup>) and transverse sliding (Nakamichi and Tachibana<sup>8</sup>) of the median nerve during wrist and finger flexion have been observed in several studies, but none of these authors have clearly determined how the median nerve moves within the carpal tunnel.

The purpose of this study was to observe medial nerve mobility in the carpal tunnel dynamically with ultrasound during wrist and fingers flexion and extension and define the abnormality between normal people and patients with carpal tunnel syndrome.

## 2. Material and methods

Thirty-two asymptomatic volunteers (15 men and 17 women) and 18 patients with symptoms of carpal tunnel syndrome [6 men and 12 women, 10 cases confirmed by nerve conduction velocity (NCV)/electromyography (EMG)] were evaluated by high-resolution ultrasound (the SonoSite Titan (SonoSite, Bothell, WA, USA) high-resolution ultrasound; transducer: 5–10 MHz, 38-mm broadband linear array). The age of the patients ranged from 22 to 64 years (mean, 35 years). Each participant was asked to make several attempts at active flexion of the fingers and wrist, and real-time monitoring was performed by ultrasound. The structures assessed were the median nerve, flexor tendons, and route of median nerve moving (Fig. 1).

## 3. Results

In persons without carpal tunnel syndrome symptoms, the median nerve moved smoothly from the volar side of the flexor tendons to the dorsal side of the flexor tendons

when the wrist and fingers flexed, with a route between the flexor digitorum superficialis (FDS) of index and flexor pollicis longus (FPL) (Fig. 2).

In patients with carpal tunnel syndrome, the normal mobility of the median nerve was absent when wrist and fingers flexed (Fig. 3).

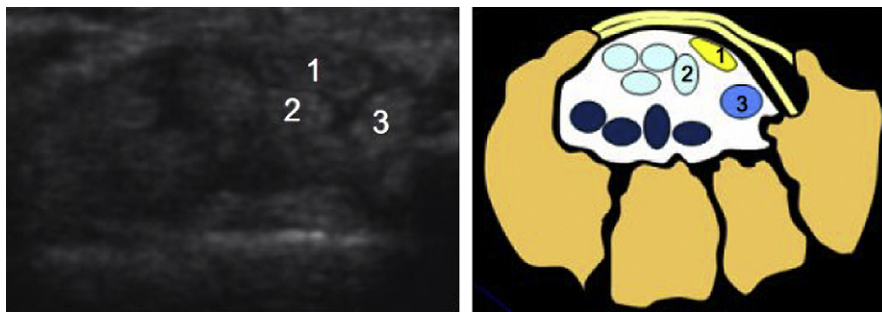
Seventeen (94%) of the 18 patients with carpal tunnel syndrome symptoms had positive findings on ultrasound examination. Four of the 32 people without symptoms of carpal tunnel syndrome had positive findings.

## 4. Discussion

The median nerve in the carpal tunnel moves longitudinally<sup>2–7</sup> and in a transverse direction (Nakamichi et al<sup>8</sup>). Jessurun et al<sup>9</sup> and Zeiss et al<sup>10</sup> evaluated the position of the median nerve by magnetic resonance imaging with different wrist flexion angles. But none of these studies mentioned the sliding mobility and route of the median nerve, which we demonstrated.

According to the sonographic findings, the mechanism of median nerve sliding may be explained as follows: with wrist and finger flexion, the FDS and FDP tendons are displaced to the volar side; increased volar compression pressure then causes the median nerve to be displaced into the newly opened space between the index FDS tendon and the FPL. Finally, the median nerve slides to the dorsal bony floor of the carpal tunnel and avoids being compressed by flexor tendons.

The mobility of the median nerve over the carpal tunnel may be a mechanism to avoid direct compression by the flexor tendons during wrist and finger flexion. In patients with carpal tunnel syndrome, decreased median nerve mobility and loss of the normal sliding route may be caused by increasing the carpal tunnel pressure and increasing median nerve diameter. The phenomenon could be dynamically observed on ultrasound. Loss of median nerve sliding ability increases pressure over the nerve compressed by the FDS and FDP tendons during wrist and finger flexion, and the clinical symptoms of carpal tunnel syndrome occur. The clinical significance of this phenomenon has been discussed in studies by McLellan and Swash<sup>7</sup> and Wilgis and Murphy.<sup>3</sup> Both studies emphasized the significance of flexor tendon longitudinal excursion as a part of the mechanism of entrapment neuropathy. Smith



**Fig. 1.** Structures inside the carpal tunnel, including the median nerve, FDS, FDP, and FPL. 1 = median nerve; 2 = FDS of index; 3 = FPL. FDS = flexor digitorum superficialis; FDP = flexor digitorum profundus; FPL = flexor pollicis longus.

Download English Version:

<https://daneshyari.com/en/article/4055486>

Download Persian Version:

<https://daneshyari.com/article/4055486>

[Daneshyari.com](https://daneshyari.com)