



## Technical Note

## Superior labral anterior-posterior (SLAP) lesion repair using the needle-catch technique and a bioabsorbable knotless suture anchor

Hsiu-Gwo Teng<sup>a</sup>, Seung-Ho Kim<sup>b,\*</sup>, Jinhyup Shin<sup>b</sup>, Jin-Hun Kwak<sup>b</sup><sup>a</sup> Department of Orthopaedic Surgery, Cathay General Hospital, Taipei, Taiwan<sup>b</sup> Department of Orthopaedic Surgery, Madi Hospital, Seoul, South Korea

## A B S T R A C T

**Keywords:**arthroscopic repair  
knotless  
needle catch  
shoulder  
superior labral anterior-posterior (SLAP)  
lesion**Purpose:** The primary objectives of surgical repair of a torn superior labrum are restoration of its anatomic position and fixation to its bony bed on the superior glenoid. This report describes a simple arthroscopic procedure that accomplishes these objectives.**Method:** In shoulder arthroscopic surgery, the procedure utilizes the “needle-catch technique” and a bioabsorbable knotless anchor, to achievement of superior labral anterior-posterior lesion repair.**Conclusion:** Arthroscopic superior labrum repair, using a bioabsorbable knotless suture anchor, is a procedure that minimizes the need for complex suture management and arthroscopic knot tying. It is easily reproducible and appears to allow for a safe and stable repair. Given the simplicity and efficacy of the “needle-catch technique”, it is likely that this procedure will prove extendable to other types of arthroscopic surgery.

Copyright © 2010, Taiwan Orthopaedic Association. Published by Elsevier Taiwan LLC. All rights reserved.

## 1. Introduction

In 1990, Snyder et al<sup>1</sup> described four types of superior labral anterior-posterior (SLAP) lesions based on the degree of involvement of the biceps tendon. Type I lesions consist of fraying and degeneration of the inner edge of the superior labrum with a firmly attached labral base and biceps anchor. In Type II tears, the labrum and biceps anchor are detached from their insertion on the superior glenoid, resulting in instability of the biceps anchor. Type III lesions consist of a bucket handle tear of the superior labrum, although the remaining portions of the labrum and biceps anchor are well attached. Type IV lesions involve a bucket handle tear of the superior labrum that extends into the biceps tendon. For Types II and IV, the currently preferred surgical approach is

to restore stability to the biceps anchor. Restoring the anatomic position of the superior labrum and securing the labrum to its bony bed on the superior glenoid are the mainstay of surgical repair of such lesions. To accomplish this, many surgeons use suture anchors.<sup>2</sup> Although suture repair with anchors is widely advocated,<sup>3,4</sup> meticulous and precise suture management is required to achieve reliable results. In experienced hands, arthroscopic knots can also provide secure fixation as the suture anchors. However, a steep learning curve is needed to master the arthroscopic knot tying, and an improper tying of the sliding knots can be a potential cause of failure and recurrent pain.

Many procedures for arthroscopic repair of the superior labrum have been described by using a variety of working arthroscopic portal. Three to five portals are generally required for such procedures.<sup>3,5–8</sup> The present report describes a simple arthroscopic technique termed the “needle-catch technique”. It utilizes a single anterior portal for suture passage and requires no specialized instrumentation for suture fixation or arthroscopic knot tying.

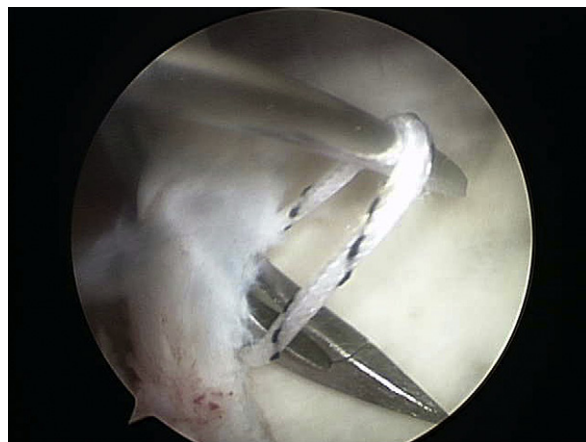\* Corresponding author. Seung-Ho Kim, Department of Orthopaedic Surgery, Madi Hospital, 192-5 Nonhyeon-dong, Gangnam-gu, Seoul 135-010, Korea. Tel.: +82 2 2056 8000; fax: +82 2 2056 8010.

E-mail address: [shk@madi.or.kr](mailto:shk@madi.or.kr) (S.-H. Kim).

## 2. Arthroscopic technique

Under general anesthesia, the patient is placed in the lateral decubitus position on the operating table with the trunk of the body tilted approximately 30° posteriorly. The arm is suspended with a longitudinal traction of 4–6 lb. Two arthroscopic portals are used: one standard posterior portal and one anterior-superior portal. The anterior-superior portal should be located precisely at the superior aspect of the rotator interval, anteriorly and slightly superior to the biceps tendon. It is considered optimal to create this portal using an outside-in technique by locating the ideal site with a spinal needle. The path of the spinal needle must approach the superior tubercle at an angle of 45°. A smooth cannula (Universal cannula; Linvatec, Largo, FL, USA) is inserted along the path of the spinal needle. The SLAP lesion is then prepared for anchor insertion after debridement of the labral edge and decortication of the glenoid rim.

A No. 2 nonabsorbable suture (FiberWire; Arthrex, Naples, FL, USA) with a penetrating suture retriever (Penetrator; Arthrex, Naples, FL, USA) is grasped and then passed via the anterior-superior portal through the labral tissue residing posteriorly to the biceps tendon (Fig. 1). One spinal needle is inserted through the skin and directed toward the FiberWire; the needle is then passed under the strand and releasing penetrator. Suspension of the FiberWire by the spinal needle is illustrated in Fig. 2 and is referred to as “needle-catch”. The penetrator is passed through the labral tissue anterior to the biceps tendon, and the FiberWire is grasped and retrieved from the anterior-superior portal (Fig. 3). A grasper, which is inserted through the anterior-superior portal, is used to retrieve the suture limb posterior to the biceps tendon such that the suture can be flipped from above the biceps to an inferior position (Fig. 4). The spear is passed through the anterior-superior portal and placed on the glenoid rim. A bone socket for positioning of the anchor is then created by drilling. Two strands of FiberWire are threaded through the distal eyelet of a bioabsorbable knotless anchor (PushLock; Arthrex, Naples, FL, USA). Tension is applied and the anchor is

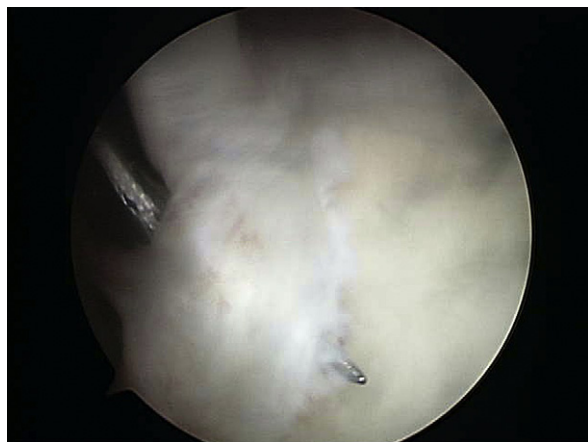

**Fig. 2.** The spinal needle is passed under the strand and releasing penetrator. Suspension of the FiberWire by the spinal needle is termed “needle-catch”.

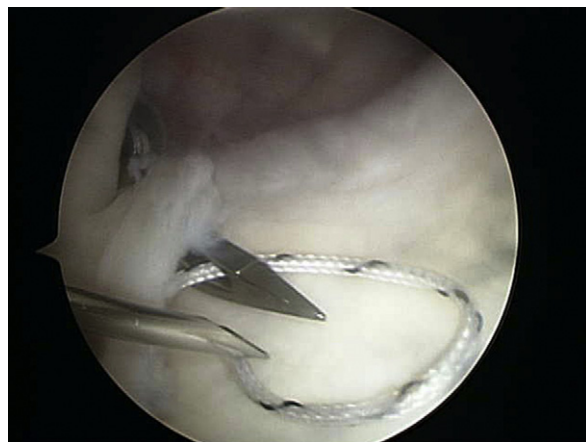
advanced into the bone socket (Fig. 5), and the suture tails are released until the anchor body contacts bone. The labral tissue should be reduced to the glenoid rim. The button on the proximal end of the driver handle is tapped to advance the anchor body. Using an open-ended suture cutter, the sutures are then cut flush to minimize the possibility of labrum irritation (Fig. 6).

## 3. Discussion

Multiple working and viewing portals are conventionally employed for arthroscopic repair of the superior labrum. In 1998, Mileski and Snyder<sup>3</sup> described use of the standard posterior, anterosuperior, and midglenoid portals for arthroscopic repair of SLAP lesions. However, other orthopedic specialists have utilized the standard posterior, anterior, anterosuperior, and anteroinferior portals for this purpose.<sup>6,8</sup> O'Brien et al<sup>7</sup> introduced the transrotator cuff approach for SLAP lesions located posterior to the biceps



**Fig. 1.** A No. 2 nonabsorbable suture with a penetrating suture retriever is grasped and then passed via the anterior-superior portal through the labral tissue residing posteriorly to the biceps tendon.



**Fig. 3.** The penetrator is passed through the labral tissue anterior to the biceps tendon, and the FiberWire is grasped and retrieved from the anterior-superior portal.

Download English Version:

<https://daneshyari.com/en/article/4055491>

Download Persian Version:

<https://daneshyari.com/article/4055491>

[Daneshyari.com](https://daneshyari.com)