

Arthroscopically Assisted Reattachment of Avulsed Triangular Fibrocartilage Complex to the Fovea of the Ulnar Head

Norimasa Iwasaki, MD, PhD, Akio Minami, MD, PhD

Triangular fibrocartilage complex (TFCC) insertion into the fovea of the distal ulna plays a crucial role in stabilizing the distal radioulnar joint. Consequently, surgical reattachment against avulsion of the foveal TFCC insertion is required to stabilize the distal radioulnar joint. However, because of technical difficulties, no arthroscopic procedure for such a lesion has currently been established. We present a new technique for arthroscopic reattachment of the avulsed TFCC into the fovea. An osseous tunnel 2.9 mm in diameter is created from the ulnar neck to the foveal surface. Under arthroscopic guidance, a nonabsorbable suture passed into a 21-gauge needle is placed into the TFCC through the osseous tunnel. The avulsed portion of the TFCC is anchored to the fovea by means of a repair suture passed through the TFCC. To achieve normal tension of the TFCC, the suture is tied onto the periosteum around the proximal entrance of the osseous tunnel. Our arthroscopic technique is relatively simple and has great advantages for progressive healing at the attachment site between the TFCC and the fovea. (*J Hand Surg* 2009;34A:1323–1326. Copyright © 2009 by the American Society for Surgery of the Hand. All rights reserved.)

Key words Arthroscopic reattachment, fovea, TFCC, wrist arthroscopy.

THE TRIANGULAR FIBROCARILAGE complex is a complex structure consisting of fibrocartilaginous and ligamentous tissues on the ulnar side of the wrist. This structure plays a crucial role in stabilizing the distal radioulnar joint (DRUJ) during forearm rotations. Trauma to or chronic disruption of the triangular fibrocartilage complex (TFCC) leads to pathologic conditions of the wrist due to DRUJ instability.

Recent biomechanical studies have clarified that the TFCC insertion into the fovea of the distal ulna has a

greater effect on DRUJ stability than that of other insertion sites.¹ Therefore, surgical reattachment against avulsion of the foveal TFCC insertion must be considered to provide stability for the DRUJ. Although open techniques for reattachment of avulsed TFCC to the fovea of the ulnar head have been introduced,^{2,3} no arthroscopic procedure has currently been developed because of technical difficulties.

Arthroscopic surgery has an advantage of accurately diagnosing and locating the lesions, which is often difficult to do in open procedures. Our aim was to suggest a technique of arthroscopic reattachment of the avulsed TFCC to the foveal region of the distal ulna.

SURGICAL TECHNIQUE

All patients had a positive ulnar fovea sign, positive provocative maneuvers described by Kleinman,⁴ and DRUJ instability. We defined DRUJ instability as an asymmetry of the constraint of the radius translation relative to the distal ulna in forearm pronation and supination.⁵ Preoperative water-excited 3-dimensional double-echo steady-state magnetic resonance coronal

From the Department of Orthopaedic Surgery, Hokkaido University School of Medicine, Sapporo, Japan.

The authors thank Dr. Yuichiro Abe for figure preparation and Dr. Tamotsu Kamishima for radiologic evaluation.

Received for publication December 3, 2007; accepted in revised form February 20, 2009.

No benefits in any form have been received or will be received related directly or indirectly to the subject of this article.

Corresponding author: Norimasa Iwasaki, MD, PhD, Department of Orthopaedic Surgery, Hokkaido University School of Medicine, Kita 15, Nishi 7, Kita-Ku, Sapporo 060-8638, Japan; e-mail: niwasaki@med.hokudai.ac.jp.

0363-5023/09/34A07-0024\$36.00/0
doi:10.1016/j.jhsa.2009.02.026

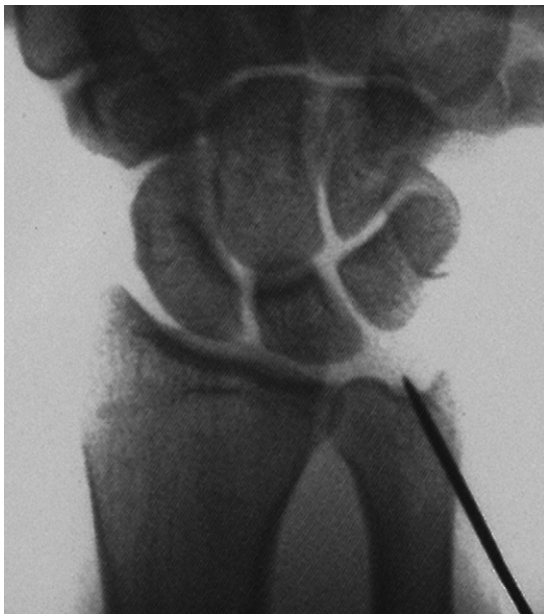


FIGURE 1: Under C-arm visualization, a guide pin is inserted from the ulnar neck to the foveal region of the ulnar head to create an osseous tunnel.

T2-weighted images showed an area of high signal intensity just distal to the fovea in all patients. Arthroscopic procedures are performed under general anesthesia with a tourniquet. A traction tower (ConMed, Largo, FL) maintains 3.2 to 4.5 kg of distraction throughout the procedure via finger traps placed on all the fingers except for the thumb. An arthroscope is introduced into the 3-4 portal using the standard technique. Outflow is established through the 6-U portal. An accessory portal includes the 6-R or 4-5 portal. The lunotriquetral interosseous ligaments and the TFCC are each inspected for wear and tear. The articular surface of the lunate and the triquetrum are also investigated. TFCC tension or resilience (trampoline effect) on ballottement with an arthroscopic probe is tested to make a diagnosis.³ The final diagnosis of avulsion of the foveal TFCC insertion is determined by a loss of the normal trampoline effect and a displacement of the TFCC in multiple directions by pulling on the TFCC using a probe.⁵

Once the diagnosis has been confirmed, a 1.5-mm (0.059-in) K-wire is used as a guide pin and percutaneously inserted from the ulnar neck to the foveal region of the ulnar head under C-arm visualization (Fig. 1). Then, a 1.5-cm incision is made around the K-wire, and the ulna is exposed between the extensor carpi ulnaris and the flexor carpi ulnaris. A 2.9-mm cannulated drill (DePuy, Warsaw, IN) is driven in just distal to the fovea over the inserted K-wire. This procedure

creates an osseous tunnel 2.9 mm in diameter from the ulnar neck to the foveal surface and debrides fibrous connective tissues at the foveal surface (Fig. 2A). Under arthroscopic guidance in the 3-4 portal, a 2-0 nonabsorbable suture (Prolene; Ethicon, Somerville, NJ) passed into a 21-gauge needle is placed into the TFCC through the osseous tunnel. Then, a 2-0 nonabsorbable suture loop is advanced into the TFCC in the same manner. The suture end is captured by the loop and delivered out of the osseous tunnel by proximally withdrawing the loop (Fig. 2A, B). Then, the 2 free ends of the repair suture are pulled through the osseous tunnel to bring the suture onto the TFCC surface. The avulsed portion of the TFCC is anchored to the fovea in this manner. Near-normal tension of the TFCC is then reconstituted by tightening both ends of the suture. With the forearm in neutral rotation, the suture is tied onto the ulnar periosteum around the proximal entrance of the osseous tunnel (Fig. 2C).

Each patient is splinted with a long-arm cast in 45° of supination for 4 weeks postoperatively. Then, a removable wrist brace is applied for an additional 2 weeks. Vigorous rehabilitation of the wrist and forearm begins at 6 weeks postoperatively.

DISCUSSION

The proximal portion of the TFCC consists of the ligamentous component, including the radioulnar ligament, which plays a crucial role in stabilizing the DRUJ during forearm rotations. Anatomic studies have emphasized that this ligament originates from the fovea as well as the base of the ulnar styloid process.⁶ In the wrist joint, the center of forearm rotation runs through the ulnar head close to the foveal region. Therefore, the foveal insertion has a greater effect on DRUJ stability during forearm rotations than the styloid insertion.¹

Sennwald et al.³ showed that an open surgical reattachment of the avulsed TFCC to its foveal insertion had promising results after a mean follow-up of 3 years. Although arthroscopic suture techniques for ulnar-sided TFCC tear (Palmer class 1B) have been reported,⁷⁻⁹ no arthroscopic procedure for the reattachment of the TFCC to the fovea has been established yet. To biologically bond the avulsed TFCC to the ulnar insertion, fibrous connective tissue at the foveal surface is debrided, and the bleeding from bone marrow is enhanced by curettage to cancellous bone. With routine arthroscopic technique, these maneuvers require direct visualization of the foveal surface by inserting the arthroscope beneath the avulsed TFCC. This makes it difficult to perform arthroscopic surgery for the avulsed TFCC from the fovea.

Download English Version:

<https://daneshyari.com/en/article/4070601>

Download Persian Version:

<https://daneshyari.com/article/4070601>

[Daneshyari.com](https://daneshyari.com)