



Available online at
ScienceDirect
www.sciencedirect.com

Elsevier Masson France
EM|consulte
www.em-consulte.com/en



Case report

Three-step sequential management for knee arthroplasty after severe ballistic injury: Two cases



Y. Herry^a, F. Boucher^{b,d}, P. Neyret^{a,d}, T. Ferry^{c,d}, S. Lustig^{a,d,*}

^a Centre Albert-Trillat, CHU Lyon Croix-Rousse, hospices civils de Lyon, 69004 Lyon, France

^b Service de chirurgie plastique, CHU Lyon Croix-Rousse, hospices civils de Lyon, 69004 Lyon, France

^c Service de maladie infectieuse, CHU Lyon Croix-Rousse, hospices civils de Lyon, 69004 Lyon, France

^d Centre de référence des infections ostéo-articulaires complexes Rhône Alpes Auvergne, hospices civils de Lyon, 69004 Lyon, France

ARTICLE INFO

Article history:

Received 11 May 2015

Accepted 25 August 2015

Keywords:

Gunshot traumatism

Ballistics

Arthroplasty

Knee

ABSTRACT

Management of knee bone loss after gunshot trauma requires a multidisciplinary approach. Two cases of knee arthroplasty after devastating ballistic trauma are reported. Treatment comprised several steps: sampling, bone resection, reinforced cement spacer, latent sepsis control, and prosthetic reconstruction. The patients showed no neurovascular disorder and had a functioning extensor mechanism. At follow-up of at least 2 years, results were satisfactory, with return to unaided walking and mean International Knee Society (IKS) score improved from 18 to 59 points. In light of these observations, knee reconstruction arthroplasty using a sequential strategy can provide satisfactory functional outcome after severe ballistic trauma.

© 2015 Elsevier Masson SAS. All rights reserved.

1. Introduction

Treatment strategy for severe ballistic trauma to the knee is not described in the literature. We have drawn up a management protocol for this situation in which severe joint destruction [1] requires surgical reconstruction [2].

A 3-step surgical strategy is implemented after the acute phase.

Step 1 comprises hardware removal and sampling. Step 2 comprises septic surgery, with bone cuts and positioning a reinforced cement antibiotic-laden spacer, as widely practiced in implant revision surgery [3,4]. Step 3 is arthroplasty, performed after an interval of time, when infection control has been achieved. Contraindications to arthroplasty comprise neurovascular disorder and extensor system tear [5]. Risk of sepsis is high [6,7], and requires bacteriological analysis, with at least 6 weeks' adapted antibiotherapy before considering implantation. The 3-step strategy was drawn up due to this major risk of infection. A second bone cut step limits risk of sepsis at implantation, delayed until samples prove sterile or antibiotherapy adapted to bacteriological findings has been initiated.

We report two cases of knee arthroplasty using the above protocol following severely destructive ballistic trauma.

2. Case reports

2.1. Patient no. 1

A 58 year-old man had a hunting accident in 2009 involving low-energy ballistic trauma [8], with Cauchois III open fracture of the distal right femur.

Initial examination found no neurovascular lesions. Emergency lavage and wound care was performed, with osteosynthesis by external fixator; the bone defect was filled with cement. Revision surgery was needed for infection at 3 months (Fig. 1).

Complete assessment was conducted before considering reconstruction surgery: MRI to check extensor system integrity, and CT-angiography to check the vascular axes. The external fixator was removed 9 months post-trauma and samples were taken (Step 1). Step 2 was implemented 6 weeks later, with bone cuts in healthy tissue (9 cm femoral and 1 cm tibial resection using a dedicated cut guide) and insertion of a nonreinforced antibiotic-laden cement spacer. Postoperative course featured thrombopenia induced by heparin, with superior vena cava and left common femoral vein thrombosis, which resolved completely. The patient was reoperated at 2 months for fracture of the spacer, which was replaced by a reinforced model (Fig. 2).

A rotating hinge reconstruction prosthesis (RHK, OSSTM, Biomet[®]) was finally implanted in November 2010, with probabilistic antibiotic-laden cement (Step 3: Fig. 3; Table 1).

* Corresponding author. Centre Albert-Trillat, CHU Lyon Croix-Rousse, hospices civils de Lyon, 69004 Lyon, France.

E-mail address: sebastien.lustig@chu-lyon.fr (S. Lustig).

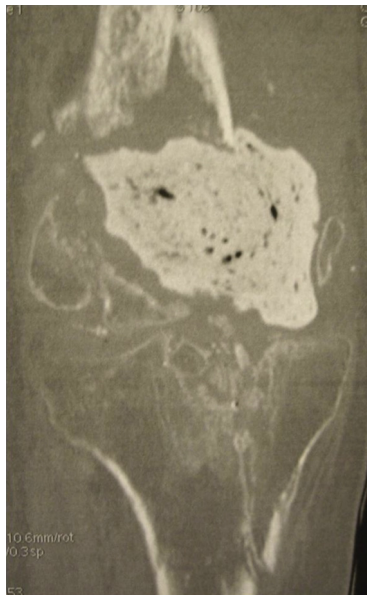


Fig. 1. CT scan: complex fracture of femur and tibia, major bone defect, cement spacer.

At 5 years' follow-up, the patient could walk without canes, with 2 cm compensation for lower-limb length discrepancy. Range of motion was 0–0–100°. International Knee Society (IKS) score was 74.

2.2. Patient no. 2

A 62 year-old male sustained a hunting accident in 2012, with Cauchoix III open fracture of the proximal left tibia.

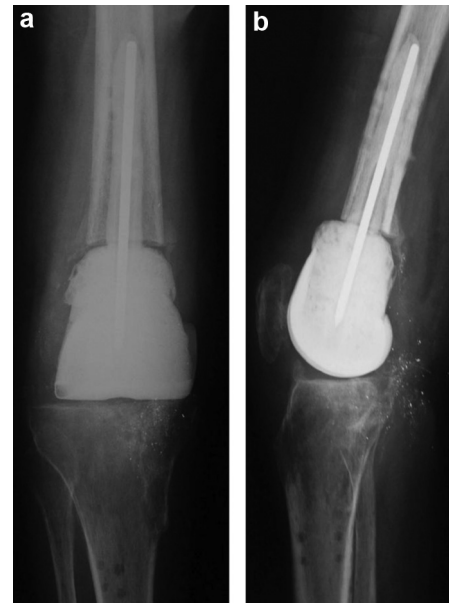


Fig. 2. a, b: AP and lateral X-ray: reinforced cement spacer to maintain limb length.

Initial work-up found no sensorimotor or vascular disorder. Emergency management comprised lavage and wound care, with osteosynthesis by external fixator and 4 screws. Negative pressure therapy was initiated due to loss of cutaneous substance on the posteromedial exit side (Fig. 4).

Bone cover was achieved by medial gastrocnemius muscle transfer.

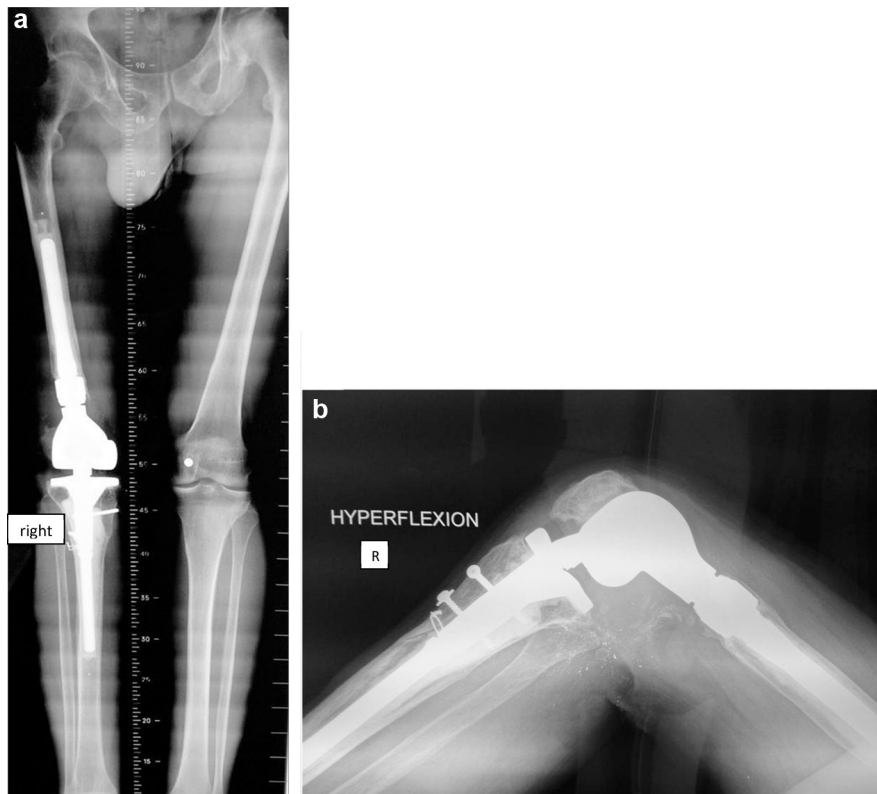


Fig. 3. a, b: AP and lateral whole-knee X-ray in maximal flexion at 5-year follow-up.

Download English Version:

<https://daneshyari.com/en/article/4080958>

Download Persian Version:

<https://daneshyari.com/article/4080958>

[Daneshyari.com](https://daneshyari.com)