



Available online at  
**ScienceDirect**  
[www.sciencedirect.com](http://www.sciencedirect.com)

Elsevier Masson France  
**EM|consulte**  
[www.em-consulte.com/en](http://www.em-consulte.com/en)



## Original article

# The ilio-inguinal approach for recent acetabular fractures: Ultrasound evaluation of the ilio-psoas muscle and complications in 24 consecutive patients



A. Lao<sup>a,b,\*</sup>, S. Putman<sup>a,b</sup>, M. Soenen<sup>a,b</sup>, H. Migaud<sup>a,b</sup>

<sup>a</sup> Université Lille Nord de France, CS 90005, 59044 Lille cedex, France

<sup>b</sup> Service d'orthopédie C, département universitaire de chirurgie orthopédique et de traumatologie, hôpital Salengro, CHRU de Lille, rue Emile-laine, 59037 Lille, France

## ARTICLE INFO

## Article history:

Accepted 11 February 2014

## Keywords:

Ilio-inguinal approach  
 Ilio-psoas muscle  
 Complications  
 Acetabular fractures

## ABSTRACT

**Introduction:** The ilio-inguinal approach is used to achieve internal fixation of acetabular fractures. Although the outcomes of this procedure have been extensively reported, information is lacking on potential complications. More specifically, the effect on the ilio-psoas muscle, whose iliac attachments are almost completely released, has not been accurately evaluated.

**Hypothesis:** Endopelvic dissection does not alter the ultrasound structure of the ilio-psoas muscle compared to the normal side at a distance from acetabular internal fixation via the ilio-inguinal approach.

**Patients and methods:** We retrospectively evaluated 26 patients who underwent internal fixation of acetabular fractures via the ilio-inguinal approach between 2006 and 2010. Two patients with multiple injuries died shortly after the procedure, leaving 24 patients with unilateral fractures for the study. In 2012, an observer who was not involved in the surgical treatment of these patients conducted an assessment (Oxford score except in the 8 patients who required revision surgery for arthroplasty and evaluation for a deficit of the lateral femoral cutaneous nerve in the full cohort). At the same time point, ultrasonography was performed to compare ilio-psoas muscle morphology on the two sides. Any other complications (vascular, nervous, or parietal) were recorded.

**Results:** Of the 24 patients, 11 (45%) experienced complications, of whom only 3 required further surgery, 2 with infections that recovered fully after lavage and 1 with a haematoma responsible for compression of the urinary bladder. The lateral femoral cutaneous nerve was injured in 8 (33%) patients, including 4 who had achieved a full recovery at last follow-up. At last follow-up, none of the 24 patients had ultrasound evidence of a significant difference in ilio-psoas muscle size at the lateral window: mean transverse diameter was  $51.8 \pm 0.8$  mm (range, 44–58 mm) on the operated side versus  $51.7 \pm 0.79$  mm (range, 44–59 mm) on the other side ( $P=0.9$ ). After a mean follow-up of 49 months (range, 31–70 months), the mean Oxford score in the 16 patients who had not required further surgery was 20.5/60 (range, 12–44).

**Discussion:** Our results show that, despite extensive endopelvic dissection, the ilio-inguinal approach has no effect on the ultrasound morphology of the ilio-psoas muscle. There is a high risk of injury to the lateral femoral cutaneous nerve that should be disclosed to the patient before the procedure. In contrast, no parietal complications were recorded. In selected patients, the Cole-Stoppa approach is an alternative that spares the lateral femoral cutaneous nerve.

**Level of evidence:** Level IV, retrospective study.

© 2014 Elsevier Masson SAS. All rights reserved.

## 1. Introduction

Emile Letournel and Robert Judet [1] standardised the surgical treatment of acetabular fractures by providing an exhaustive

radiographic description of the lesions. The ilio-inguinal approach was introduced in 1961 to treat anterior wall and column injuries, as well as selected recent cases of transverse and bicolumnar fractures [2]. This anterior approach is widely used and recognised as effective in these indications [3–7]. However, the complications are rarely reported, and most studies focus on the quality of the reduction [4–7] or on immediately life-threatening complications [8,9]. A few studies evaluated changes in muscle strength after internal

\* Corresponding author. Tel.: +33 6 10 07 99 75; fax: +33 3 20 44 66 07.  
 E-mail address: [antoinelao@hotmail.fr](mailto:antoinelao@hotmail.fr) (A. Lao).

fixation of acetabular fractures [10,11] but they had small sample sizes ( $\leq 15$  patients) and did not include an evaluation of muscle morphology. The ilio-psoas muscle is of particular interest, as most of its attachments are released during the endopelvic dissection required for the ilio-inguinal approach [10,11].

The objective of this study was to conduct an ultrasound evaluation of the ilio-psoas muscle after internal acetabular fixation via the ilio-inguinal approach. We evaluated whether this approach resulted in specific complications, with particular attention to the frequency of injury to the lateral femoral cutaneous nerve.

## 2. Material and method

### 2.1. Patients

Between 2006 and 2010, 32 patients underwent surgery via the ilio-inguinal approach. Among them, 6 required internal fixation of the pelvic ring. We excluded these 6 patients, as the injury per se may have produced muscle damage and other approaches were used concomitantly (para-symphyseal approach, lateral window). In the remaining 26 patients, the ilio-inguinal approach was used for internal fixation of the acetabulum. Two patients with multiple injuries died shortly after the procedure, leaving 24 patients for the current study.

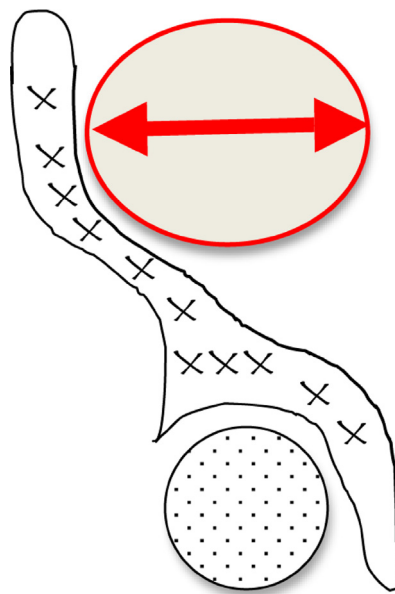
There were 8 females and 16 males with a mean age of 39.6 years (range, 24–68 years). The fractures were due to intentional defenestration in 4 patients, work-related accidents in 4 patients, unintentional falls in 2 patients, and motor vehicle accidents in 14 patients. Mean time from injury to surgery was 7.2 days (range, 3–10 days). A single senior surgeon performed all the procedures according to the seminal description by Emile Letournel [2,3] involving ilio-psoas muscle detachment from the iliac fossa of the pelvis until just above the sacro-iliac joint, as well as release of the fascia iliaca. After abundant pulsed lavage, the wound was closed on a suction drain with reattachment of the oblique muscles. None of the patients received non-steroidal anti-inflammatory drug therapy to prevent ectopic ossification formation.

Of the 24 patients, 5 had anterior column fractures, 10 bicolumnar fractures, 7 transverse fractures (including 2 with posterior wall fractures), and 2 T-shaped fractures. In 5 patients, an additional posterior approach was used for fixation of a posterior lesion via the Kocher-Langenbeck approach, during the same stage but after re-installation of the patient (2 transverse fractures with involvement of the posterior wall, 1 T-shaped fracture, and 2 bicolumnar fractures). Pelvic ring disruption (dislocation of the sacro-iliac joint or pubic symphysis) was present in 4 patients; we included these patients, as the minimal displacement of the lesions could not have caused damage to the endopelvic muscles. Ipsilateral sciatic nerve palsy was noted immediately after the injury in 2 patients.

### 2.2. Assessment methods

The same observer assessed the patients after a mean follow-up of 49 months (range, 30–71 months). Perioperative complications were recorded. The assessment included a physical examination to look for a deficit of the lateral femoral cutaneous nerve. In addition, the Oxford functional score [12] was determined in the 16 patients who had not required arthroplasty. Heterotopic ossifications were rated according to Brooker et al. [13].

Ultrasonography of the ilio-psoas muscle was performed at the level of the scar and comparatively on the uninjured side (Fig. 1). This investigation was performed in all 24 patients, including the 8 patients with arthroplasty, as this second procedure was done exclusively via the posterior approach and was therefore deemed unable to influence ilio-psoas muscle morphology. Width in the



**Fig. 1.** Method used to measure ilio-psoas muscle morphology by ultrasonography. The radius was measured in the coronal plane, at the anterior superior iliac spine, with the probe held parallel to the scar left by the ilio-inguinal approach.

coronal plane was measured and compared to the uninjured side (Fig. 2). The entire width of the ilio-psoas muscle was taken into account, including the width of the psoas muscle tendon and the belly of the iliacus muscle. The measurements were obtained by several radiologists, all of whom followed the same standardised protocol: comparative symmetric measurements performed by the same radiologist with the probe perpendicular to the axis of the body, near the cranial ventral iliac spine. The difference between the two sides was evaluated using the non-parametric Wilcoxon test with the first order risk set at 0.05.

## 3. Results

In 2 patients, infectious complications required surgical lavage and probabilistic antibiotic therapy, which was secondarily adjusted to microbiological cultures. Neither had septic recurrence after a follow-up of at least 2 years with the fixation material left in place. In another patient, a haematoma in the ilio-psoas muscle caused compression of the urinary bladder and required surgical drainage. Ectopic ossifications class IV according to Brooker et al. were noted at the posterior approach in 1 patient [13]. During the immediate postoperative period, injury to the lateral femoral cutaneous nerve was diagnosed clinically in 8 (33.3%) patients (1 T-shaped fracture, 1 anterior column fracture, 2 bicolumnar fractures, 2 transverse fractures, and 2 combined transverse/posterior wall fractures). The deficit recovered fully in 4 patients, leaving 4 (16.6%) patients with deficits at re-evaluation (1 T-shaped fracture, 1 transverse fracture, 1 bicolumnar fracture, and 1 combined transverse/posterior wall fracture).

At follow-up, none of the patients had inguinal hernias or abdominal wall dehiscence, but keloid scars were noted in 2 males. In none of the patients was the scar rated a cosmetic sequela.

In 8 (33.3%) patients, arthroplasty was performed, 36 to 48 months after internal fixation. Among them, 4 (3 bicolumnar fractures and 1 T-shaped fracture) underwent total hip replacement. Hip resurfacing arthroplasty was performed in the 4 other patients (3 bicolumnar fractures and 1 combined transverse/posterior wall fracture).

Download English Version:

<https://daneshyari.com/en/article/4081433>

Download Persian Version:

<https://daneshyari.com/article/4081433>

[Daneshyari.com](https://daneshyari.com)