



Available online at  
**ScienceDirect**  
[www.sciencedirect.com](http://www.sciencedirect.com)

Elsevier Masson France  
**EM|consulte**  
[www.em-consulte.com/en](http://www.em-consulte.com/en)



Original article – Works of GETRAUM

# Indications and technical challenges of total hip arthroplasty in the elderly after acetabular fracture



P. Jouffroy<sup>a,\*</sup>, The Bone and Joint Trauma Study Group (GETRAUM)<sup>b</sup>

<sup>a</sup> Service de chirurgie orthopédique et traumatologique, hôpital Saint-Joseph, 185, rue Raymond-Losserand, 75014 Paris, France

<sup>b</sup> 56, rue Boissonnade, 75014 Paris, France

## ARTICLE INFO

### Article history:

Accepted 13 November 2013

### Keywords:

Acetabulum  
 Fracture  
 Elderly  
 Hip replacement  
 Bone fixation

## ABSTRACT

**Introduction:** With people living longer and healthier lives, acetabular fractures in the elderly are becoming more common. But these fractures are still much less common than proximal femur fractures. Because of an insufficient number of cases, prospective studies with good statistical power have not yet been performed. Nevertheless, a collective, multicentre analysis of these injuries and their prognosis would help to define clinical practice recommendations.

**Material and methods:** As with younger subjects, the initial assessment for acetabular fractures in the elderly must be comprehensive and include detailed radiological evaluation and precise analysis of the fracture. Accurate diagnosis of the fracture type and displacement will allow the surgeon to follow a decision tree, with options ranging from functional treatment to emergency total hip arthroplasty (THA), depending on the patient's condition.

**Conclusion:** THA treatment of these fractures is challenging for the surgeon in several aspects. These include determining the waiting time before the procedure, selecting the surgical approach, problems related to any existing hardware, need for bone grafting, primary fixation of the cup, dislocation risks, and the patient's ability to recover from an extensive and often complex surgery.

**Level of proof:** Level V: expert opinion.

© 2014 Published by Elsevier Masson SAS.

## 1. Introduction

Elderly patients with an acetabular fracture must undergo the same preoperative assessments as younger patients, so that an accurate fracture diagnosis can be made. This evaluation consists of an A/P view of pelvis, an anterior oblique view and an iliac oblique view [1,2]. A computed tomography scan (CT scan) with thin slices spanning the entire pelvis, from the tip of the wings of the ilium to the bottom of both ischiums, is also performed [2,3]. The fracture is analysed using single-plane and three-dimensional (3D) reconstructions.

Over the past twenty years, many studies have shown that elderly subjects have the same fracture pattern. In most cases, the anterior wall is fractured in combination with the back of the acetabulum being opened [4,5]. With the elderly person typically falling from his/her own height onto the greater trochanter, the femoral neck's natural anteversion leads to the acetabulum opening like a set of double doors: anterior wall is displaced anterior and lateral, and back wall is displaced anterior and medial. The upper segment of the hip bone often maintains some continuity

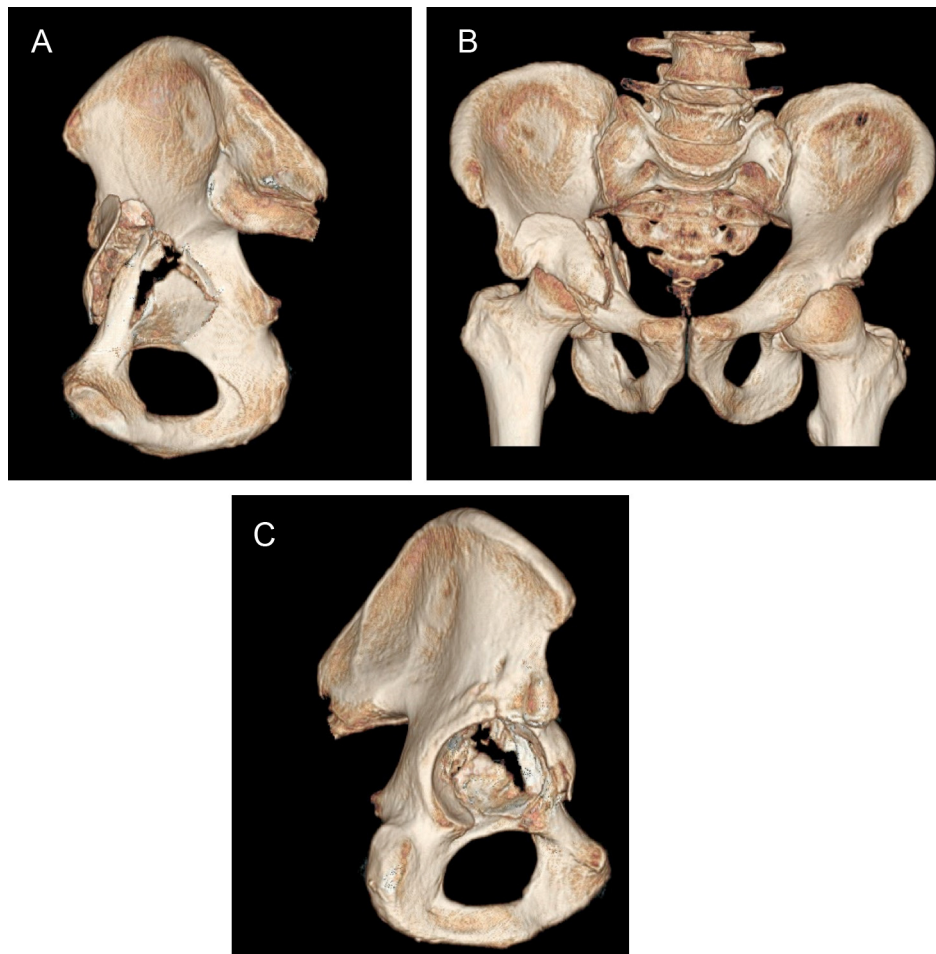
between the two (Fig. 1). These fractures cause central dislocations with the congruency between the femoral head and roof of the acetabulum being highly variable. If surgery is indicated, the anterior ilio-inguinal approach (Fig. 2) seems to be the most appropriate [4].

## 2. Decision tree

In these elderly (70+ years old) patients suffering from acetabular fractures, it is important to make the right decision at the right time and to base this decision on the patient's general condition, vitality and treatment options. Practical recommendations range from early surgery on an acute fracture to secondary arthroplasty later on after the fracture. Many surgeons who frequently treat fractures of this type believe that indications for immediate total hip arthroplasty are rare and require significant experience with pelvis surgery and hip replacement. Without this experience, some recommend waiting for bone union, which happens fairly quickly (45–90 days). All are aware that secondary arthroplasty also has significant technical challenges and that selecting which case would benefit the most from a certain treatment is difficult (magnitude of displacement, patient activity level and autonomy, comminution, associated femoral head fracture) [2–9]. Based on international publications and the work of teams experienced in

\* Corresponding author.

E-mail address: [pjouffroy@hpsj.fr](mailto:pjouffroy@hpsj.fr)



**Fig. 1.** 3D reconstruction of an acetabulum fracture that is typical of this type of injury in elderly patients.

this type of surgery (Club Bassin Cotyle in France), a decision tree has been proposed (Fig. 3).

### 3. Challenges with arthroplasty under these circumstances

#### 3.1. Waiting time before surgery

When an elderly person presents with an acetabular fracture, the surgeon is faced with several scenarios. The fracture could be nearly congruent in the vertical and horizontal planes on CT scan and there could be minimal sinking of the femoral head. In this case, neither fracture fixation nor arthroplasty surgery may be required. Functional treatment is recommended for two weeks using light traction, or immediate mobilisation so the fragments can mould themselves around the head [2,5,6,7,9,10]. Weight bearing is allowed starting on the 45th day. The fracture could be massively displaced and the hip joint in an unacceptable position. If the patient is very active and has good bone quality, early reconstruction surgery can be proposed. In these cases, the surgeon may decide to perform THA and must then choose between performing it in an emergency context or waiting. The patient's general condition and ability to tolerate the procedure are critical factors to take into account for this decision, as this surgery is difficult, extensive and haemorrhagic, especially with acute fractures. The hip must be replaced as quickly as possible so the elderly patient can regain his/her autonomy. Both local and general conditions must be balanced when selecting the right time to do surgery.

It has been suggested that the surgery should be delayed so the fractured bones have time to heal. But in cases where the fracture is painful and/or has caused non-anatomical bone alignment that is not well tolerated, this first impression should be reconsidered. THA must be performed more quickly in these cases. If the THA will be delayed until the fracture heals, rehabilitation is essential because the patient has no autonomy and proper hip mobility must be maintained [7].

#### 3.2. Approach

A priori, there are no contraindications to any of the currently used THA approaches (anterior, anterolateral or posterior) [2,5,7–10]. But trochanterotomy is the only way to perform circumferential arthrolysis. In hips that have significant migration into the pelvis, this procedure will allow the patient to regain full mobility by removing any developing osteophytes and releasing any capsule adhesions secondary to the fracture [5].

#### 3.3. Problems related to existing hardware

The choice of approach may be driven by the need to remove fixation hardware identified on CT scan that could potentially interfere with total hip arthroplasty. Nevertheless, it is best not to reuse the ilio-inguinal approach. The fibrosis between blood vessels and plate, and between the psoas, crural fascia and plate, which is in part due to the resection of the iliopectineal strip during the initial

Download English Version:

<https://daneshyari.com/en/article/4081508>

Download Persian Version:

<https://daneshyari.com/article/4081508>

[Daneshyari.com](https://daneshyari.com)