

## Case Report

## Osteoid osteoma presenting as thoracic scoliosis

Masashi Uehara, MD, Jun Takahashi, MD\*, Shugo Kuraishi, MD, Masayuki Shimizu, MD,  
Shota Ikegami, MD, Toshimasa Futatsugi, MD, Hiroyuki Kato, MD

Department of Orthopaedic Surgery, Shinshu University School of Medicine, 3-1-1 Asahi, Matsumoto-City, Nagano 390-8621, Japan

Received 11 May 2015; revised 28 July 2015; accepted 27 August 2015

**Abstract**

**BACKGROUND CONTEXT:** Osteoid osteoma of the thoracic spine is relatively uncommon and is often difficult to diagnose, especially when patients do not complain of pain.

**PURPOSE:** This study aims to describe an unusual case of scoliosis caused by osteoid osteoma of the thoracic spine that was challenging to diagnose.

**STUDY DESIGN/SETTING:** A case report of a 12-year-old girl who presented with scoliosis caused by osteoid osteoma of the thoracic spine without apparent pain was carried out.

**METHODS:** Diagnosis of the lesion was made using computed tomography (CT) and magnetic resonance imaging as well as the Scoliosis Research Society-22 (SRS-22) patient-based questionnaire.

**RESULTS:** A preoperative CT myelogram revealed a mass lesion in the lamina of the 10th thoracic vertebra that was considered to be osteoid osteoma. This diagnosis was histologically confirmed following tumor excision. The patient's spinal deformity and SRS-22 scores were both improved at 5 months postoperatively.

**CONCLUSIONS:** Osteoid osteoma of the thoracic spine may present as non-painful scoliosis. Tumor resection is effective. Clinicians should bear this uncommon lesion in mind during recommended CT examination before scoliosis surgery. © 2015 Elsevier Inc. All rights reserved.

**Keywords:**

Osteoid osteoma; Scoliosis; Spinal deformity; Tumor excision; Vertebral rotation; CT myelogram

**Introduction**

Osteoid osteoma was first described by Jaffe in 1935 [1]. It is a benign reactive bone lesion that most frequently occurs in male adolescents between 10 and 20 years of age [2,3]. The predominant cause of painful scoliosis in adolescents is osteoid osteoma of the spine [4]. Approximately 10%–25% of osteoid osteoma cases occur in the spine [5–9]: 60% of tumors are found in the lumbar spine, 27% in the cervical spine, 12% in the thoracic spine, and 2% on the sacrum. There is a very strong correlation between the neoplasm and scoliosis because two-thirds of cases manifest as painful scoliosis [10]. However, osteoid osteoma is commonly missed in a large,

albeit undetermined, number of patients [11] because the lesion is often recognized only after months or years of ineffective bracing [12].

Osteoid osteoma of the thoracic spine is relatively uncommon. It is often difficult to diagnose, especially when the patient does not complain of pain. We herein describe the clinical outcome of a girl who presented with scoliosis caused by osteoid osteoma of the thoracic spine that was detected by preoperative computed tomography (CT).

**Case report**

A 12-year-old girl was suspected to have scoliosis in a routine school health screening in May 2013. Because her condition worsened despite the use of a brace, she visited our institution for scoliosis correction surgery in April 2014. Her height was 154 cm and her weight was 40 kg at presentation. She had pervasive developmental disorders along with an expressive language impediment, although her intelligence quotient score was average. She possessed no family history of scoliosis. She complained of no additional

FDA device/drug status: Not applicable.

Author disclosures: **MU:** Nothing to disclose. **JT:** Nothing to disclose. **SK:** Nothing to disclose. **MS:** Nothing to disclose. **SI:** Nothing to disclose. **TF:** Nothing to disclose. **HK:** Nothing to disclose.

\* Corresponding author. Department of Orthopaedic Surgery, Shinshu University School of Medicine, 3-1-1 Asahi, Matsumoto-City, Nagano 390-8621, Japan. Tel.: (81) 263-37-2659; fax: (81) 263-35-8844.

E-mail address: [jtaka@shinshu-u.ac.jp](mailto:jtaka@shinshu-u.ac.jp) (J. Takahashi)

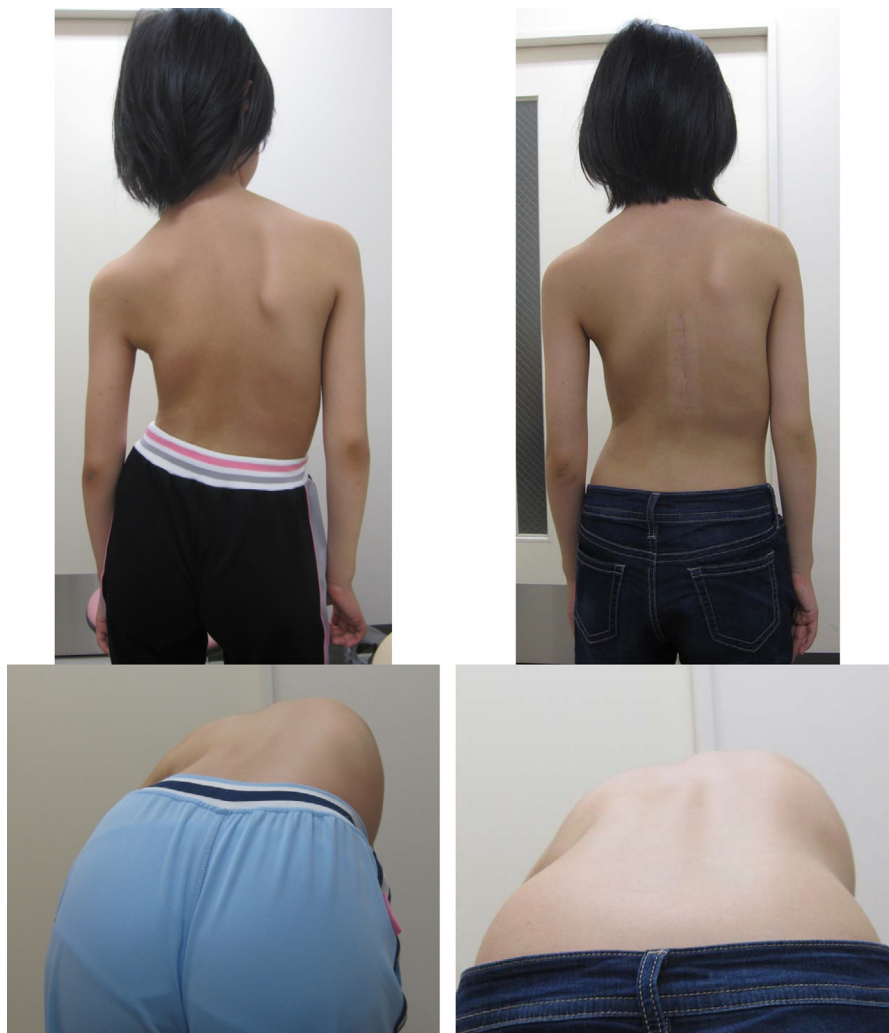


Fig. 1. (Left) Apical trunk rotation (ATR) was 19° as determined by a scoliometer. (Right) ATR had improved to 9° at 5 months postoperation.

symptoms, including back pain. Physical examination revealed right shoulder elevation. Apical trunk rotation, as determined by a scoliometer, was 19° (Fig. 1, Left). We observed no neurologic deficits. Whole spine radiographs revealed a Lenke-type 1AN curve with a Cobb angle of 45° from T5 to L2 (main thoracic) and 28° from L2 to L5 (lumbar) (Fig. 2, Left). Risser grade was 2.

Magnetic resonance imaging of the whole spine did not reveal any evidence of Arnold-Chiari malformation, syringomyelia, or dural ectasia (Fig. 3). As we had planned to perform posterior correction surgery for the patient's scoliosis, a CT examination was performed after myelography, which demonstrated a mass lesion in the lamina of the 10th thoracic vertebra with a visible nidus (Fig. 4). A re-examination of the MRI results verified this finding. The patient's Scoliosis Research Society-22 (SRS-22) patient questionnaire scores for function, pain, self-image, mental health, and subtotal were 4.5, 5.0, 2.4, 4.0, and 3.9, respectively. This enabled a revised diagnosis of osteoid osteoma, and the lesion was

surgically excised. Histologic tissue findings confirmed our diagnosis (Fig. 5).

Postoperative brace therapy improved the patient's spinal deformity. Her shoulder imbalance was diminished and her apical trunk rotation had improved to 9° at 5 months after surgery (Fig. 1, Right). At 5 months postoperatively, Cobb angle from T5 to L2 was ameliorated at 30° (Fig. 2, Right) and SRS-22 scores for function, pain, self image, mental health, subtotal, satisfaction, and total had improved to 4.8, 5.0, 3.4, 4.6, 4.5, 4.0, and 4.4, respectively.

The patient and her family have provided consent for the data in this case to be published.

## Discussion

Osteoid osteoma is a benign osteoblastic neoplasm that is characterized by a well-demarcated core of <1 cm and a distinctive surrounding zone of reactive bone formation [13]. Although the lesions may occur anywhere in the cortex or

Download English Version:

<https://daneshyari.com/en/article/4096271>

Download Persian Version:

<https://daneshyari.com/article/4096271>

[Daneshyari.com](https://daneshyari.com)