The Spine Journal 16 (2016) e209–e214

Case Report

Growing rod technique for the treatment of the traumatic spinopelvic dissociation: a technical trick

Hwan Yong Chung, MD, PhD[b], Kyung-Soo Suk, MD, PhD[a], Hwan-Mo Lee, MD, PhD[a], Hak-Sun Kim, MD, PhD[a], Woo-Chul Jung, MD[a], Seong-Hwan Moon, MD, PhD[a], Byung Ho Lee, MD, PhD[b,*]

[a]*Department of Orthopedic Surgery, Yonsei University College of Medicine, Seoul, South Korea*
[b]*Department of Orthopedic Surgery, International St. Mary's Hospital, Catholic-Kwandong University, Incheon, South Korea*

Received 18 December 2014; revised 8 September 2015; accepted 29 October 2015

Abstract

BACKGROUND CONTEXT: Traumatic spinopelvic dissociation, sometimes referred to as U-shaped sacral fracture, is a very rare high-energy trauma. The surgical management of spinopelvic dissociation includes decompression, reduction, and fixation.

PURPOSE: We report a novel surgical technique for the treatment of spinopelvic dissociation that uses growing rods and a pedicle screw system, which is often used to treat patients with early onset scoliosis.

STUDY DESIGN: This case report used a technical report of spinopelvic dissociation surgery using spinopelvic fixation and the growing rod technique.

PATIENT SAMPLE: One case was used as the patient sample.

OUTCOME MEASURE: Radiographic outcomes, including plain X-ray, three-dimensional computed tomography, and magnetic resonance imaging scan were the outcome measures.

METHODS: The radiographic outcomes were compared preoperatively, postoperatively, and at the 1-year follow-up with bony union.

RESULTS: Growing techniques improved traumatic sacral angulation, displacement, and canal encroachment, and provided sufficient structural support.

CONCLUSION: The growing rod technique for spinopelvic dissociation under intraoperative neurophysiological monitoring could be a useful alternative surgical option, especially in patients without neurologic deficit.

Keywords: Growing rod; Spinopelvic dissociation; Sacrum

Introduction

Traumatic spinopelvic dissociation, sometimes referred to as U-shaped sacral fracture, is a very rare high-energy trauma [1]. The sacrum is the mechanical nucleus of the axial skeleton, and it serves as the base for the spinal column and the keystone for the pelvic ring [1]. Surgical management of spinopelvic dissociation includes decompression, reduction, and fixation [2,3]. We report a novel surgical technique for the treatment of spinopelvic dissociation that uses growing rods and a pedicle screw system. This system is often used to treat patients with early onset scoliosis [4,5].

Case presentation (Fig. 1)

A 28-year-old woman was injured by a fall from height (10 m) that occurred because she was hallucinating under the influence of antipsychotic medication. She sustained hemothorax accompanied by flail chests, lung contusion, and hemoperitoneum caused by spleen and liver rupture. She underwent emergency operation for hemoperitoneum and received a chest tube to treat the hemothorax. She stayed in

FDA device/drug status: Not applicable.

Author disclosures: ***HYC:*** Nothing to disclose. ***KSS:*** Nothing to disclose. ***HML:*** Nothing to disclose. ***HSK:*** Nothing to disclose. ***WCJ:*** Nothing to disclose. ***SHM:*** Nothing to disclose. ***BHL:*** Nothing to disclose.

IRB status: This study received the approval of the Institutional Review Board of International St. Mary's Hospital, Catholic-Kwandong University, Incheon, Korea (IRB No. 2014773).

This study was not supported by any financial sources.

* Corresponding author: Department of Orthopedic Surgery, Incheon International St. Mary's Hospital, 291 Simgok-dong, Seo-Gu, 404-190, Incheon, South Korea. Tel.: +82 32 290 3928; fax: +82 32 290 3879.

E-mail address: 144667@daum.net (B.-H. Lee)

http://dx.doi.org/10.1016/j.spinee.2015.10.058
1529-9430/

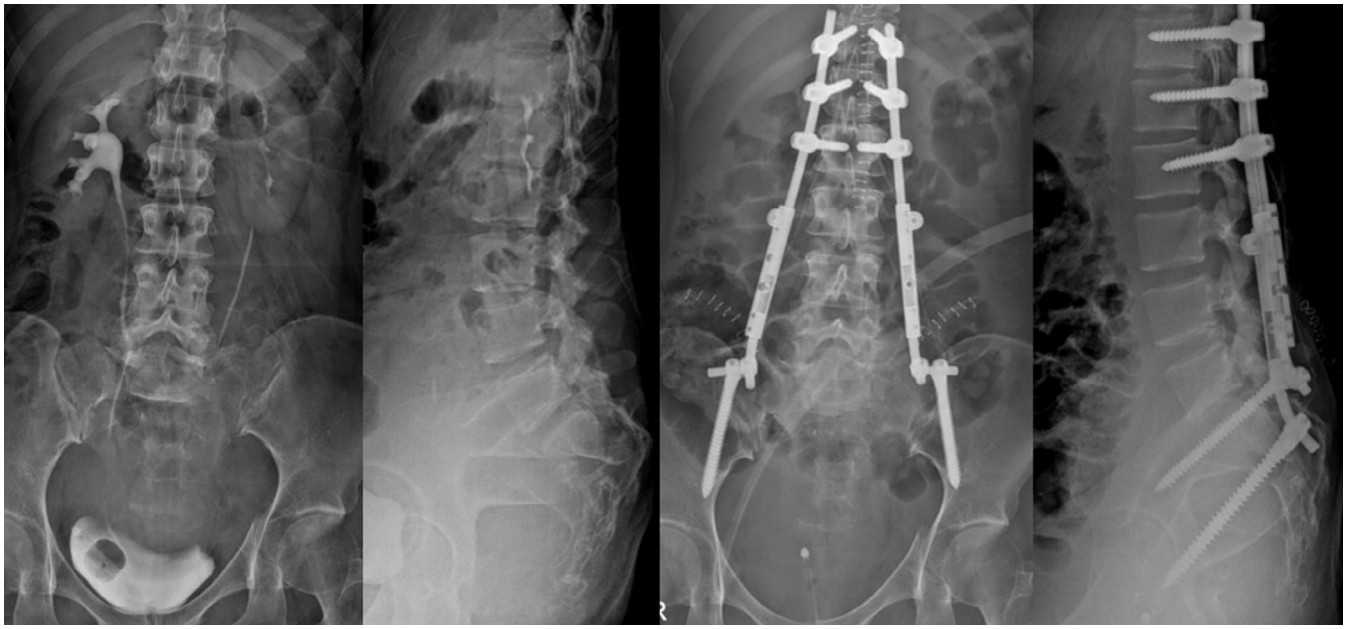

Fig. 1. Comparison between pre- and postoperative X-rays. Preoperative counterclockwise rotation and posterior angulation of the proximal sacral fragment was reduced after 3-cm lengthening of the growing rods. The bilateral L5 pedicles are visible on anterior-posterior X-rays after reduction.

the surgical intensive care unit and underwent spinopelvic surgery at 13 days post-trauma, as soon as her vital signs had stabilized. Fortunately, her motor and sensory function below the sacral fracture level was intact. The preoperative computed tomography scan showed no evidence of intraforaminal bone fragments, which could injure the nerve roots during fracture reduction [1]. Therefore, a growing rod system was selected for fracture reduction and fixation [6].

Surgical technique

After general endotracheal anesthesia, the patient was placed prone on a table (Jackson Spinal Table System, OSI, Union City, CA, USA), and all pressure points were carefully padded. The whole back and upper buttocks were prepared and draped in the usual sterile orthopedic manner.

During preoperative planning (Fig. 2),the insertion level of the proximal pedicle screws was determined on the preoperative lateral plain radiographs, giving consideration to the distal rod bending and minimal length of the growing rods (Growing rods system, GSS Medical, Seoul, Korea), preferably at the level of the thoracolumbar junction area. The fracture site demonstrated skin tenting with fluctuation from a mixture of hematoma formation and possible cerebrospinal fluid leakage.

A skin incision was made over both iliac screw entry points bilaterally and the posterior midline of the designated proximal lumbar vertebrae level longitudinally (Fig. 2). The proximal pedicle screws were inserted with a free hand technique or under guidance of the C-arm. Then, the iliac screws were inserted under guidance of the C-arm from the posterior superior iliac crest to maximize the fixation force caused



Fig. 2. Preoperative planning, the mechanism of the growing rod, and minimally invasive growing rod insertion technique. With consideration for the length of the growing rod, the designated proximal screw insertion point was marked. Rotation of the saw-tooth gear enables lengthening of the growing rod. The submuscular rod insertion technique is very helpful because it avoids opening of the fracture site, which could cause massive bleeding and possible cerebrospinal fluid (CSF) leakage from a torn dural sac. Submuscular insertion of the growing rod also leads to minimal tissue damage of the normal lumbar segments.