



## Furlow palatoplasty for previously repaired cleft palate with velopharyngeal insufficiency<sup>☆</sup>



Mosaad Abdel-Aziz<sup>a,\*</sup>, Ahmed Nassar<sup>a</sup>, Mohammed Rashed<sup>b</sup>, Nader Naguib<sup>b</sup>, Abdel-Rahman El-Tahan<sup>c</sup>

<sup>a</sup> Department of Otolaryngology, Cairo University, Egypt

<sup>b</sup> Department of Otolaryngology, Beni Suef University, Egypt

<sup>c</sup> Department of Otolaryngology, Aswan University, Egypt

### ARTICLE INFO

#### Article history:

Received 11 June 2015

Received in revised form 30 July 2015

Accepted 31 July 2015

Available online 8 August 2015

#### Keywords:

Furlow palatoplasty

Velopharyngeal insufficiency

Cleft palate

Hypernasality

### ABSTRACT

**Objective:** Velopharyngeal insufficiency (VPI) is a common complication after cleft palate repair, it may be due to lack of levator sling reconstruction and/or palatal shortening. Furlow palatoplasty has the advantages of retro-positioning of levator palati muscles and palatal lengthening. The aim of this study was to assess the efficacy of Furlow palatoplasty in the treatment of VPI in patients who undergone previous palatoplasty.

**Methods:** Twenty-three children with post-palatoplasty VPI were included in the study. Furlow technique which was not used in the primary repair, has been used as a secondary corrective surgery. Preoperative and postoperative evaluation of velopharyngeal function was performed, using auditory perceptual assessment (APA) and nasometry for speech, and flexible nasopharyngoscopy for velopharyngeal closure.

**Results:** Significant improvement of APA and nasalance score for oral and nasal sentences was achieved. Flexible nasopharyngoscopy showed complete velopharyngeal closure in 19 patients (82%) postoperatively.

**Conclusion:** Furlow palatoplasty is considered a useful treatment option for VPI in patients with previously repaired cleft palate, it improves the speech and velopharyngeal closure.

© 2015 Elsevier Ireland Ltd. All rights reserved.

## 1. Introduction

Velopharyngeal insufficiency (VPI) is the inability to completely close the velopharyngeal port during speech. The resultant leakage of air into the nasal cavity during speech can cause hypernasal vocal resonance and nasal emissions [1]. The effect of VPI on speech and resonance ranges from mild speech distortion to a catastrophic disruption of speech intelligibility, leading to social communicative problem for the patients and their families [2].

The commonest cause of VPI is the palatal cleft even after repair, the problem may be due to the incomplete lengthening of the palate, lack of levator sling reconstruction, the scar contracture of the straight line closure that may even shorten the palate, and the occurrence of palatal fistulae [3–5]. The frequency of VPI after cleft palate repair that may need secondary corrective surgery varies

in different literature between 15% and 45%. This wide range of incidence is due to the presence of different techniques for repair of cleft palate, and even the same technique may be done by different ways [6].

Furlow double-opposing Z-plasty was first used in cleft palate repair in 1978 [7], it aims to lengthen the palate through the Z-plasty effect and to prevent the longitudinal scar contracture, it also reconstructs the levator sling by displacement of levator palati muscles of both sides posteriorly overlapping each other after reorientation of their fibers from an abnormal vertical direction to a transverse one [8,9]. Long-term studies have demonstrated improved speech results and reduced rates of secondary surgery for correction of VPI on comparing the Furlow technique to other palatoplasty methods [10]. The aim of this study was to assess the efficacy of performing Furlow double opposing Z-plasty for patients presented with post-palatoplasty VPI.

## 2. Materials and methods

One hundred twenty-two patients were referred to our institutes with hypernasal speech after repair of their clefts in

<sup>☆</sup> The study was carried out in the Departments of Otolaryngology of Cairo University, Beni Suef University and Aswan University, Egypt.

\* Corresponding author at: 2 el-salam st., King Faisal, Above El-baraka bank, Giza, Cairo, Egypt. Tel.: +20 1005140161; fax: +20 225329113.

E-mail address: [mosabeez@yahoo.com](mailto:mosabeez@yahoo.com) (M. Abdel-Aziz).

the period from June 2012 to March 2014. Of these, 23 patients fulfilled the study criteria. The ages of the patients ranged from 5 to 13 years (with a mean of 8.5 years), 14 males and 9 females. The study was conducted in the Departments of Otolaryngology of Cairo University, Beni Suf University, and Aswan University. The original defects included 5 patients with bilateral complete cleft lip and palate, 9 patients with unilateral complete cleft lip and palate and 9 patients with cleft soft palate, complete clefts were repaired by 2 flap palatoplasty while incomplete clefts were repaired by Veau–Wardill–Killner technique. Patients who underwent Furlow Z-plasty or intravelar palatoplasty for repair of their clefts, who presented with palatal fistulae or other craniofacial anomalies, or who were subjected for secondary corrective velopharyngeal surgery were excluded from the study. Informed consents were obtained from the parents of the patients and the principles outlined in the Declaration of Helsinki were followed.

All patients were subjected to the following.

### 2.1. Preoperative assessment

- Otolaryngologic examination: Full ear, nose and throat, and head and neck examination was performed for detection of other associated diseases. Ear examination, including tympanometry, was performed for detection of middle ear effusion, and oral examination was performed to assess the condition of the palate.
- Auditory perceptual assessment (APA) of speech: hypernasality, nasal emission of air, weak pressure consonants were analyzed for every individual patient. Each of these parameters was graded along a 5-point scale (0–4) in which 0: normal, and 4: severely affected, with a total score of 12 on the 3 elements. The lower the score achieved on this rating scale, the less incompetence the patient demonstrates [3]. The APA data were recorded for postoperative review.
- Nasometric assessment: instrumental assessment of nasalance was done using Nasometry (Kay Elemetrics, model 6200, NJ, USA) which provides an acoustic measure of movement of the vibrational energy through the vocal tract. Nasometric data were obtained while the patients read or repeated standardized Arabic nasal and oral sentences.
- Flexible nasopharyngoscopy: to visualize the velopharyngeal port. The nasopharyngoscope was provided with a high-intensity cold light and a special endoscopic television system for videotape recording. This was accomplished using a high-resolution Karlheinz Hinze S/N 151385 endoscope (Karlheinz Hinze Optoengineering GmbH & Co., Hamburg, Germany), Storz endoscope video camera (Karl Storz GmbH & Co. KG; Tuttlingen, Germany), and Panasonic SR 500 video recorder (Osaka, Japan). The nose was decongested and anesthetized with a mixture of 4% lidocaine and 0.05% oxymetazoline hydrochloride before the procedure. Velopharyngeal closure was assessed while the patients repeating Arabic sentences loaded with high oral pressure consonants. VPI was considered in the presence of velopharyngeal gap and/or bubbles [11].

### 2.2. Operative procedure

Under general anesthesia with oral endotracheal intubation, incisions were marked and the palate was injected with 0.5% Xylocaine in adrenaline (1:100,000). The soft palate was split into 2 halves from the midline recreating a cleft soft palate. Furlow double opposing Z-plasty technique was used for repair [7,10,11].

### 2.3. Postoperative assessment

Patients were seen postoperatively at one week interval for three weeks, then monthly for at least one year. All patients have been received speech therapy one month postoperatively.

By the end of the follow up period; APA, nasometric assessment, and flexible nasopharyngoscopy were performed with recording of the same parameters that had been recorded preoperatively. Comparison of the preoperative and postoperative data was done.

### 2.4. Statistical method

Data were coded and summarized using Statistical Package for Social Sciences version 17.0 for Windows (SPSS Inc., Chicago, IL). Quantitative variables are presented as mean  $\pm$  standard deviation. Comparison of preoperative and postoperative results of auditory perceptual assessment and nasometric assessment was done using paired two-sample *t* test.  $P < 0.05$  was considered statistically significant.

## 3. Results

Twenty three children with previously repaired cleft palate were enrolled in the study, all patients were referred to our institute because of hypernasal speech after failure of speech therapy. Furlow double opposing Z-plasty was selected as the technique of palatal re-repair, all patients demonstrated the disease as an isolated deformity with no other congenital anomalies. No intraoperative complications were encountered, all patients showed complete wound healing with no dehiscence or fistulae (Fig. 1). Myringotomy with T-tubes insertion was performed bilaterally for 17 patients who demonstrated middle ear effusion.

Regarding assessment of speech, the mean preoperative baseline of APA was 7.55 ( $\pm 2.03$ ) that improved to 6.82 ( $\pm 1.81$ ) (Table 1). The difference between preoperative and postoperative scores was significant ( $P$  value = 0.001).

The preoperative nasalance score was 35.82 ( $\pm 3.70$ ) for the nasal sentences and 13.52 ( $\pm 1.62$ ) for the oral sentences, improved to 33.30

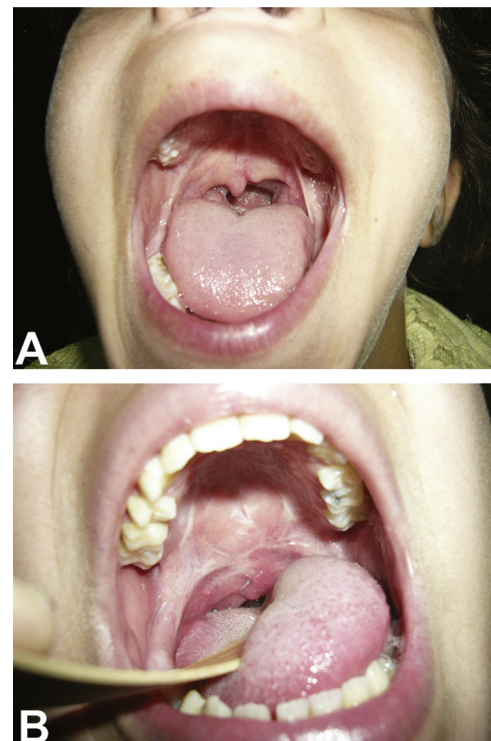


Fig. 1. (A) A preoperative view of a patient with poorly repaired short palate. (B) A postoperative view of the same patient after Furlow palatoplasty.

Download English Version:

<https://daneshyari.com/en/article/4111942>

Download Persian Version:

<https://daneshyari.com/article/4111942>

[Daneshyari.com](https://daneshyari.com)