



Percutaneous tracheotomy: Griggs technique

Sunny S. Park, MD, MPH, David Goldenberg, MD

From the Department of Surgery, Division of Otolaryngology–Head and Neck Surgery, Penn State College of Medicine, Penn State Milton S. Hershey Medical Center, Hershey, Pennsylvania.

KEYWORDS

Griggs;
Percutaneous;
Tracheotomy;
Guidewire dilator
forceps;
Bedside

The Griggs percutaneous tracheotomy is a technique that is safe and cost effective, and can be done rapidly at the bedside. The Griggs percutaneous tracheotomy is unique in its utilization of a guidewire dilator forceps. The indications for Griggs percutaneous tracheotomy are identical to those used for open tracheotomy and include prolonged intubation, pulmonary toilet, and upper airway obstruction. Fiberscopic visualization has been promoted by some to potentially decrease complications. In this article, the indications, contraindications, technique, and complications of the Griggs method will be discussed.

© 2007 Elsevier Inc. All rights reserved.

Percutaneous tracheotomy is a technique that can be performed easily and rapidly at the bedside and is particularly useful in patients in the intensive care setting. There are 3 basic techniques for the percutaneous approach to tracheotomy, all of which use a guidewire. These include the Ciaglia, translaryngeal, and Griggs dilating forceps methods. This article concentrates on the latter technique. The Griggs method was developed in 1990 and is based on Seldinger guidewire technique. The method incorporates the use of a pair of guidewire dilator forceps (GWDFs) that were created from a modified Howard–Kelly forceps (Figure 1).¹ The GWDF has an exaggerated curve that decreases the risk of damage to the posterior tracheal wall. A hole between the 2 arms of the forceps allows the insertion of the guidewire, and a narrowed and tapered tip diameter makes this forceps ideal for entering a small hole in the anterior wall of the trachea. The role of the GWDF is to enlarge the hole in the trachea so that a tracheotomy tube can be placed.

Although there is a distinct learning curve to this technique, it is easy and faster to perform when compared with the open technique.^{2,3} For this reason, some nonsurgeons are embracing this method. Also, percutaneous tracheotomy is considered to be cost effective, that is, roughly performed in the operating room.² In this article, the indications, contraindications, technique and complications of the Griggs method of percutaneous tracheotomy will be discussed.

Indications

The indications for percutaneous tracheotomy regardless of technique are identical to those for open tracheotomy, including primarily prolonged intubation with mechanical ventilation, inability to wean from ventilation, pulmonary toilet, and upper airway obstruction.^{4,5}

Contraindications

There are several contraindications for the percutaneous tracheotomy technique. An absolute contraindication is needed for emergency surgical airway. Relative contraindications include children younger than age 12, poor landmarks secondary to either body habitus, abnormal anatomy or occluding thyroid mass, positive end-expiratory pressure greater than 15 cm H₂O, coagulopathy, pulsating vessel over the tracheotomy site, limited ability to extend the cervical spine, history of difficult intubation, and infection, burn, or malignancy at the tracheotomy site.²

Of note, there is a case report of a successful use of Griggs technique for an urgent airway in which the entire procedure was performed successfully in 30 seconds.⁶

Procedure

The patient is evaluated preoperatively to assure that she/he is a suitable candidate for a percutaneous tracheotomy. The neck is palpated, and the landmarks, including the thyroid

Address reprint requests and correspondence: David Goldenberg, MD, Otolaryngology–Head and Neck Surgery, H091, Penn State Milton S. Hershey Medical Center, 500 University Drive, PO Box 850, Hershey, PA 17033-0850.

E-mail address: dgoldenberghmc@psu.edu.

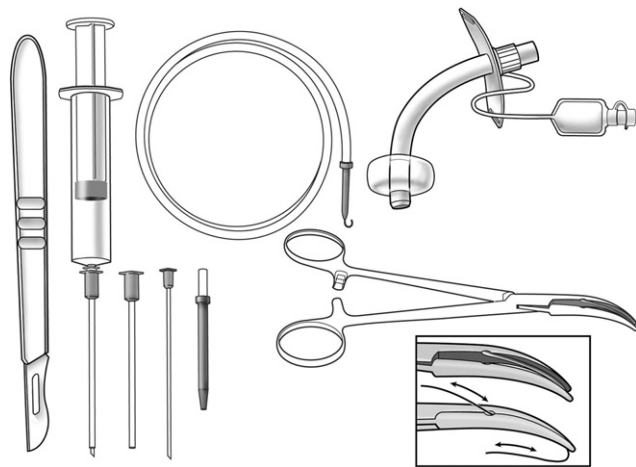


Figure 1 Griggs percutaneous tracheotomy set.

cartilage, cricoid cartilage, and sternal notch, are identified. The patient is positioned with a roll under the shoulders and the neck is extended. Local anesthesia is injected at the incision site, which is immediately below the cricoid cartilage and is 1.5 to 2.0 cm in length (Figure 2). After a skin incision, a 14-gauge needle and a cannula attached to syringe filled with fluid are inserted in the midline and advanced until withdrawal of air bubbles into the syringe confirms placement in the trachea (Figure 3A).

At this point, the cannula is advanced into the lumen of the trachea, and the needle is withdrawn. Then, the introducer is inserted into the cannula, and the J-tipped Seldinger wire is placed into trachea (Figure 3B). The cannula is removed, leaving the wire in the trachea. The dilator is passed over the guidewire through the soft tissues until the tracheal wall is felt (Figure 4). Next, the GWDF is clamped, and the guidewire is threaded through the bore at the tip (Figure 5). This is advanced through the soft tissues until resistance is felt. It is then inserted into the hole in the anterior tracheal wall. The forceps handles are raised vertically for the tip to penetrate the tracheal wall and lie lon-

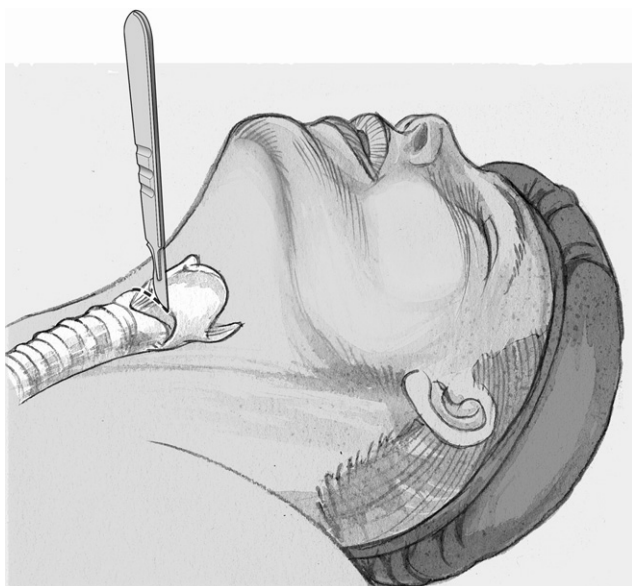


Figure 2 Make a horizontal or vertical incision (1.5-2 cm) in the skin.

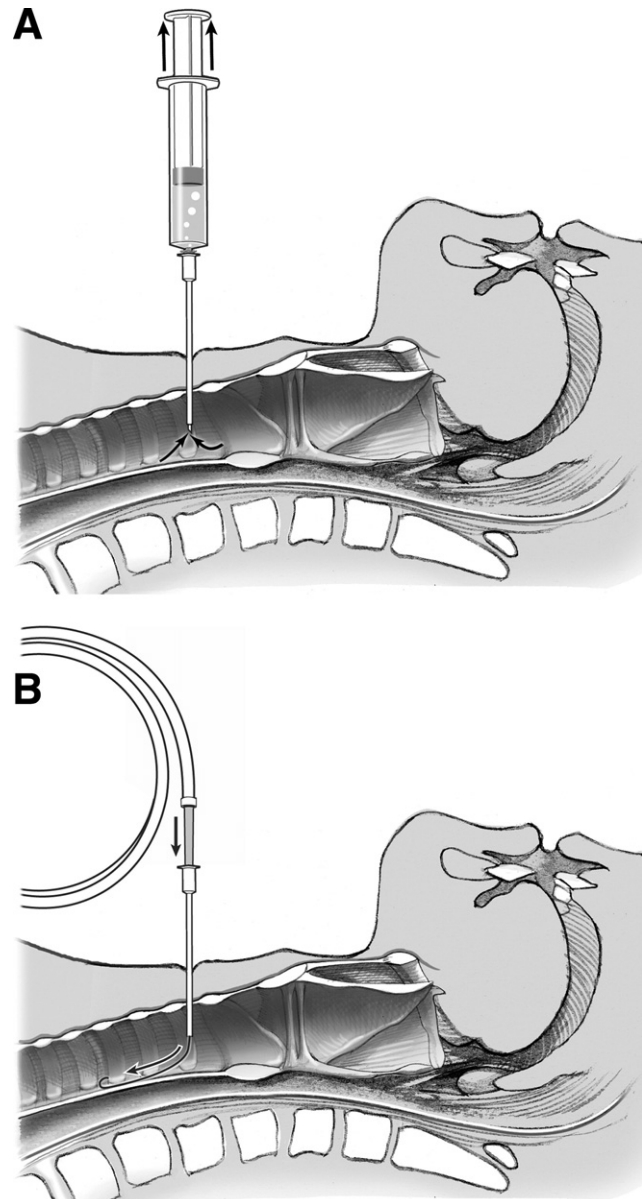


Figure 3 (A) Withdrawal of air bubbles into syringe to confirm placement in the trachea. (B) Using the introducer, feed the J-tipped guidewire into the trachea.

gitudinally in the trachea to dilate the tracheal wall adequately to place the tracheotomy tube. Then, the forceps are opened to dilate the tissues anterior to the trachea (Figure 6). Finally, the guidewire is threaded through the bore, and the obturator and tracheotomy tube are advanced into the trachea (Figure 7). The cuff is inflated appropriately and the trachea suctioned as needed. The placement of the tracheotomy tube is confirmed with the anesthesia team, and the tube is secured to the neck by placing nonabsorbable sutures and a tracheotomy tie or collar.

The simultaneous use of a bronchoscope has been advocated by many authors. A better visualization can confirm the tracheal puncture and guidewire insertion.^{7,8} In addition, tracheal wall laceration, and pretracheal or intraesophageal insertion can be avoided. Some authors say that the use of bronchoscope can shorten the duration of difficult procedures.⁹ Borm and coworkers also advocate the use of endoscopic guidance especially for inexperienced surgeons, for the placement of cannula and guidewire.¹⁰ Others add

Download English Version:

<https://daneshyari.com/en/article/4123247>

Download Persian Version:

<https://daneshyari.com/article/4123247>

[Daneshyari.com](https://daneshyari.com)