



Repeated metastasectomy in an adolescent with fibrolamellar hepatocellular carcinoma: A case report



Shaheed Merani^{a,*}, Gordon M. Lees^{a,b}

^a Division of General Surgery, Department of Surgery, 2D, Walter C Mackenzie Health Sciences Centre, University of Alberta, 8440 – 112 Street, Edmonton, Alberta, Canada, T6G 2B7

^b Division of Pediatric Surgery, Department of Surgery, 2D, Walter C Mackenzie Health Sciences Centre, University of Alberta, 8440 – 112 Street, Edmonton, Alberta, Canada, T6G 2B7

ARTICLE INFO

Article history:

Received 7 December 2015

Received in revised form

26 February 2016

Accepted 27 February 2016

Key words:

Fibrolamellar hepatocellular carcinoma

Metastasectomy

Adolescent

ABSTRACT

The fibrolamellar variant of hepatocellular carcinoma (FL-HCC) is a primary malignancy of the liver classically identified in the non-cirrhotic liver. By virtue of the non-cirrhotic liver background, patients with FL-HCC are more likely to be selected for surgical resection as primary treatment than in classic HCC. Synchronous and metachronous metastasis of FL-HCC can be treated with either resection, chemotherapy, or both. We present here an adolescent who underwent resection of a large FL-HCC following neo-adjuvant chemotherapy. The patient went on to receive surveillance and resection of five serially identified metastasis. Despite repeated aggressive metastasectomy, we observed survival in this case surpassing the median reported survival for adolescents with FL-HCC. This case supports the hypothesis proposed previously that aggressive surgical resection, including metastasectomy in the thoracic and abdominal cavity, should be offered to patients with this rare tumor.

© 2016 The Authors. Published by Elsevier Inc. This is an open access article under the CC BY-NC-ND license (<http://creativecommons.org/licenses/by-nc-nd/4.0/>).

The fibrolamellar variant of hepatocellular carcinoma (FL-HCC) is a primary malignancy of the liver classically identified in the non-cirrhotic liver. This may in part account for better prognosis in FL-HCC patients compared to HCC patients. FL-HCC differ from classic HCC in that they typically appear in non-cirrhotic liver, present at a younger age, are often not associated with elevation in AFP. Liver biopsy is more often required for the diagnosis of FL-HCC.

The management of this tumor is mirrored on established practice for classic HCC. Aggressive surgical resection is more feasible for patients with FL-HCC due to the tolerance for lower post-resection future liver remnant in the typical non-cirrhotic context, than in the class form of HCC presenting in a cirrhotic background.

The two largest and most recent case series have defined the natural history of adolescents with FL-HCC treated primarily with surgery [1,2]. The median overall survival is 52–57 months, and 5-year overall survival is 42.6%. Factors associated with favorable outcome are early PRETEXT or AJCC stage, negative regional lymph

node involvement, white race, female gender, and complete surgical resection.

While resection for metastatic deposits of FL-HCC has been advocated, there is paucity in case series or reports of any more than two metastasectomies in the same patient. Presented here is a case of a locally advanced FL-HCC in an adolescent, initially treated with neo-adjuvant chemotherapy followed by resection of the liver tumor. The patient subsequently developed serially five metachronous metastases over the course of five years that were each treated with resection at the time of identification.

1. Case

A 15-year-old boy was referred to the pediatric general surgeon with an abdominal mass and ultrasound showing a heterogenous mass arising from the liver. He was otherwise healthy. Laboratory studies revealed a normal total bilirubin (6 $\mu\text{mol/L}$) and alkaline phosphatase (184 U/L), but elevated ALT (88 U/L) and AFP 93 $\mu\text{g/L}$. Other tumor markers were within normal limits CEA (<1 $\mu\text{g/L}$) and HCG <5 U/L.

Further evaluation with triphasic CT scan (Fig. 1) demonstrated a large heterogeic hypervascular mass in the left lobe of

* Corresponding author.

E-mail address: merani@ualberta.ca (S. Merani).

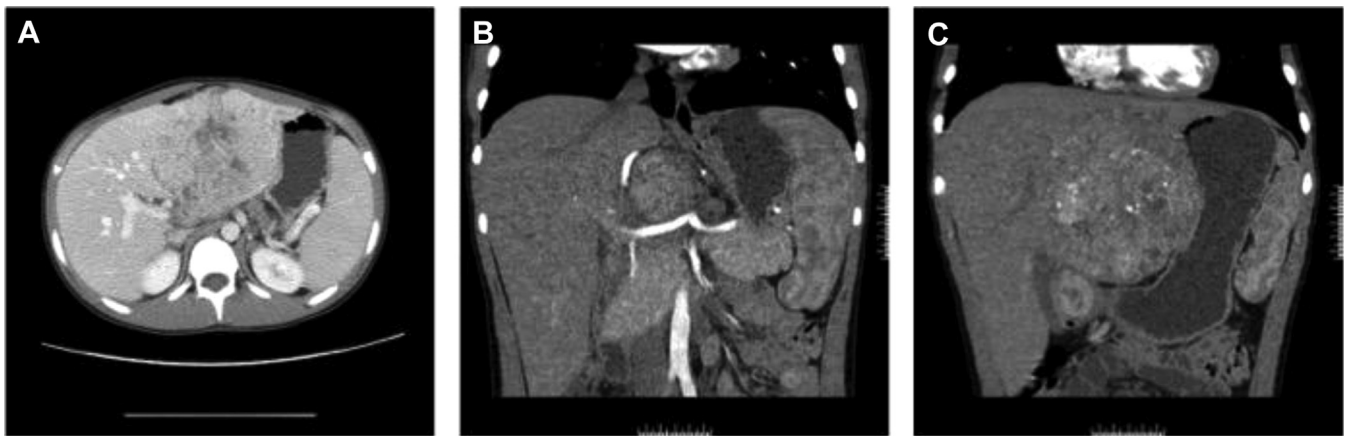


Fig. 1. Selected images from CT scan of the abdomen showing heterogeneous lesion of the left liver in axial (A) and coronal (B and C) section.

the liver, with close proximity to the common hepatic artery. The lesion contained coarse internal calcifications with central necrosis. Satellite lesion in segment 4 and enlarged hepatic hilum node. Core needle biopsy of the mass was diagnostic for FL-HCC.

After multi-disciplinary review, a three-month course of doxorubicin, cisplatin, and sorafenib was initiated; however, post-treatment imaging failed to show tumor response. Unfortunately, the patient exhibited sorafenib related skin toxicity. The patient went on to receive angiographic embolization of the tumor using Therosphere (Yttrium-90 glass particles) and accessory LHA bland embolization. Regression in tumor volume and AFP was noted at 11 months after initial diagnosis. This was followed by surgical resection including left hepatectomy (11.5 × 8 × 6 cm tumor), and resection of the celiac, gastro-hepatic, and para-aortic lymph nodes which were all identified to contain metastatic HCC. Following an uncomplicated recovery from surgery, serum AFP level was normal.

At 18 months there was an increase in the serum AFP and a mass was identified at the cardiophrenic angle on axial imaging. This was resected via left thoracotomy, and histopathology demonstrated a metastatic deposit of HCC (Fig. 2).

At 27 months following initial presentation, a mass was identified between the tail of pancreas, left adrenal gland and spleen. Resection of this metastasis was achieved with en bloc distal pancreatectomy and splenectomy (Fig. 3).

At 30 months, a recurrence was identified in the hepatoduodenal ligament, and resection preserving the portal vein, hepatic artery, and bile duct was achieved.

The patient was surveyed for an additional year and a half during which time there was no recurrence; however, at four years following initial presentation left pulmonary hilum was identified. Resection was achieved through a repeated left thoracotomy. The mass was identified to be abutting but not invading the left pulmonary artery, left main stem bronchus, and aortic arch (Fig. 4).

One year later, an anterior mediastinal mass was identified. This was surgically resected via sternotomy, and identified to be metastasis within the thymus (Fig. 5).

At 5-years from the time of initial presentation; the patient reported symptoms of abdominal pain. He was found to have an

unresectable retroperitoneal mass with association of the portal-splenic vein confluence in the head of the pancreas.

2. Discussion

FL-HCC was at first thought to be relatively indolent compared to classic HCC; however superior prognosis of FL-HCC likely secondary to resectability afforded by the non-cirrhotic patient rather than a function of tumor biology [3]. Both of the largest and most recent case series in FL-HCC support an approach including surgical resection including involved lymph nodes and metastasis as the first-line treatment of FL-HCC, reporting associated with better prognosis.

Peritoneal, lymphatic, pulmonary [4], and even pancreatic metastasectomy [5] have been described for FL-HCC; however, only one case report has documented a second metastasectomy on a single patient [6]. Kow et al. in their series have reported the overall survival of patients with metastatic FL-HCC undergoing peritoneal

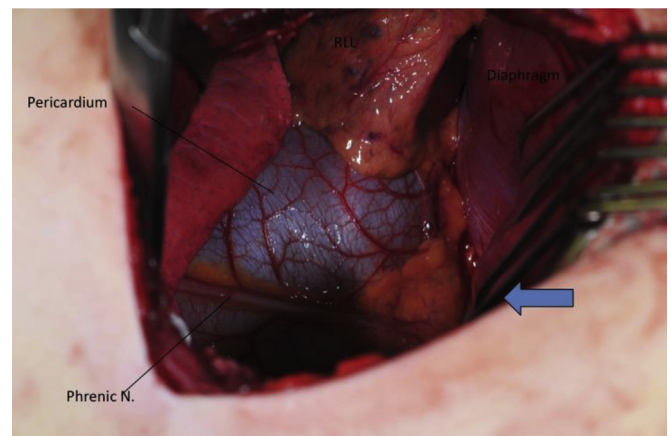


Fig. 2. Metastatic deposit in the cardiophrenic angle identified by arrow. Proximity to pericardium, phrenic nerve, and diaphragm illustrated.

Download English Version:

<https://daneshyari.com/en/article/4161106>

Download Persian Version:

<https://daneshyari.com/article/4161106>

[Daneshyari.com](https://daneshyari.com)