



Single-Incision Pediatric Endosurgery (SIPES) oophoropexy in an adolescent with Hodgkin lymphoma prior to pelvic irradiation



Aaron D. Seims*, Alpin D. Malkan, John A. Sandoval, Israel Fernandez-Pineda

Department of Surgery, St. Jude Children's Research Hospital, USA

ARTICLE INFO

Article history:

Received 15 April 2015
Received in revised form
25 April 2015
Accepted 28 April 2015

Key words:

Fertility
Oophoropexy
Pediatric
Radiation
Single-incision
SIPES

ABSTRACT

Oophoropexy for fertility preservation during pelvic irradiation dates back to the mid-1960s. For Hodgkin lymphoma (HL), this was performed during a staging laparotomy. Laparoscopic ovarian fixation has supplanted open pexy with advancements in technology and abandonment of staging laparotomies. Single-Incision Pediatric Endosurgery (SIPES) is applicable to numerous multi-port operations. Use of this technique for oophoropexy prior to pelvic irradiation, however, has not been reported. A 19 year-old with stage IVb HL involving the left iliac node basin was to receive radiotherapy and was evaluated for bilateral oophoropexy. An Olympus TriPort™ was introduced at the umbilicus, through which a 5 mm zero-degree laparoscope and a needle driver were introduced. Transabdominal passage of a ski needle through a 2 mm nick in the skin of the anterolateral wall allowed for right sided fixation of the ovaries. Operative recovery was uncomplicated, and post-operative imaging demonstrated satisfactory positioning of the gonads outside the planned radiation field. In conclusion, SIPES oophoropexy is a technically simple method for fertility preservation that offers improved cosmesis.

© 2015 The Authors. Published by Elsevier Inc. This is an open access article under the CC BY-NC-ND license (<http://creativecommons.org/licenses/by-nc-nd/4.0/>).

Cure rates for pediatric HL are excellent, and the surgeon's role is largely limited to biopsy and venous access. With rising survival rates, increasing attention is being paid to pubertal derangements and hormone dysregulation. Direct gonadotoxic effects of chemotherapy, the principal treatment for HL, also decrease reproductive potential [1–3]. Therefore, demand for specifically tailored fertility preservation options has expanded the surgeon's role in HL management. For example, ovarian transposition with oophoropexy reduces gonadal exposure to radiation.

Ovaries can be moved anterolaterally or inferiomedially. The anterolateral approach may involve separation of the fallopian tubes from the ovaries prior to lateralization [4]. This movement of the ovaries out of the radiation field has been shown to decrease exposure [5,6]. While successful return of ovarian function after transposition has been reported [7,8], surgical techniques that involve separation of the fallopian tube from the ovary may prevent unassisted conception and require in vitro fertilization. The movement of ovaries inferiorly eliminates the need to separate the

fallopian tube from the ovary, allowing oocyte preservation and the potential for unassisted pregnancy.

Oophoropexy was being performed at the time of surgical staging in 1965 at Stanford University Medical Center, where this procedure allowed retained ovarian function in two-thirds of treated women [9]. The procedure was commonly performed in the era of laparotomies for HL, but surgical staging became unnecessary as use of chemotherapy grew more widespread. As staging laparotomy frequency declined, so did that of oophoropexy. Emphasis on fertility preservation and quality of life blossomed with improved survivorship, however, leading to a resurgence of interest in oophoropexy.

Single-Incision Pediatric Endosurgery (SIPES) utilizes one multichannel access port to accomplish laparoscopic operations in children that traditionally required multiple ports. Proposed benefits of this technique include decreased pain and improved cosmesis. Publications defining applicability and safety of SIPES exist, but few report adnexal operations. Of those that do, oophoropexy is infrequently reported in the setting of ovarian torsion. In this report, we present our application of SIPES to oophoropexy in a patient with HL prior to radiation therapy. The operation was an anterolateral fixation that did not require separation of the fallopian tubes from their respective ovaries. We believe this procedure, which was performed safely and with

* Corresponding author. Room IA2309, 262 Danny Thomas Place, Memphis, TN 38105, USA. Tel.: +1 901 595 4284.

E-mail address: Aaron.Seims@STJUDE.ORG (A.D. Seims).

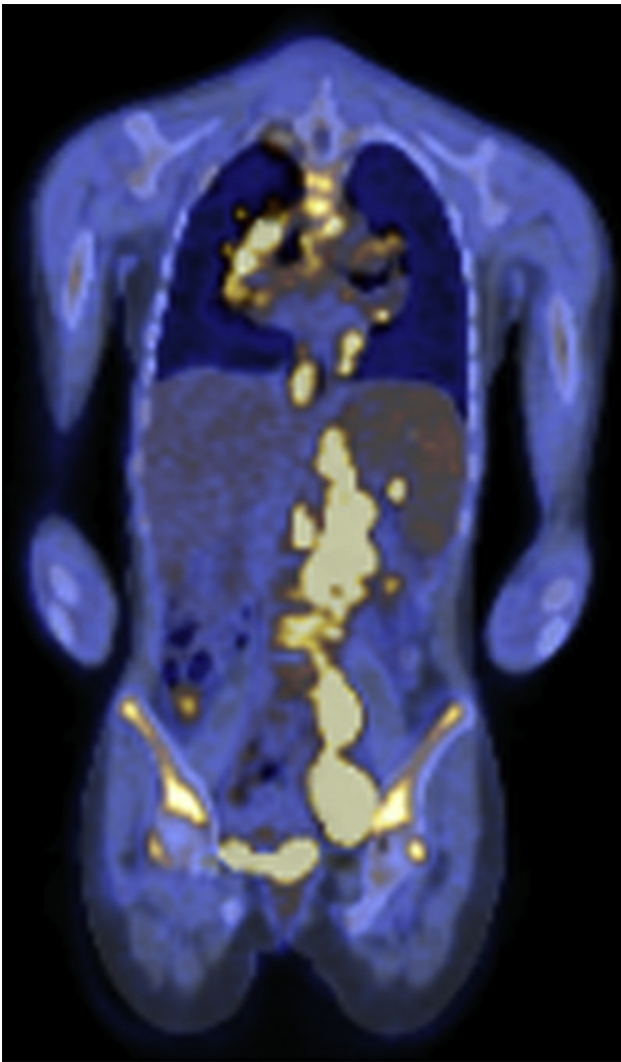


Fig. 1. PET-CT image demonstrating Hodgkin lymphoma involving the left internal iliac node basin.

good cosmetic results, is a reasonable alternative to conventional triangulated laparoscopy.

1. Materials and methods

We prepared this manuscript after having obtained Internal Review Board (IRB) approval (FWA00004775). A novel application of SIPES is described, through which both ovaries in a 19 year-old patient with stage IVb HL were fixated to the right anterolateral abdominal wall. Preoperative assessment included a positron emission tomography – computed tomography (PET-CT), and involvement of the left internal iliac node basin was identified as a target for radiation therapy (Fig. 1).

In the supine position with both arms tucked and a urinary catheter in place, the abdomen was accessed via the umbilicus. A vertical incision was made through the skin within the confines of the umbilicus. A hemostat was utilized to bluntly clear subcutaneous fat from the linea alba inferiorly and superiorly. The linea alba was then sharply incised, allowing for hemostat passage through the peritoneum. With the tip of the hemostat directed upward, the abdominal wall was elevated and the linea alba further opened over a length of 2 cm. Through this umbilical opening, the

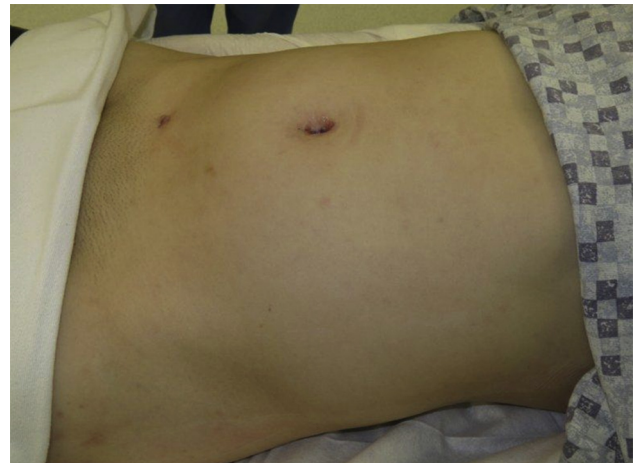

Fig. 2. Post-operative incision at the umbilicus and 2 mm skin nick in the right lower quadrant, both dressed with skin glue.

Olympus TriPort™ was deployed. Insufflation was applied and the patient was positioned in steep Trendelenburg, allowing for cephalad displacement of viscera and optimal visualization of adnexa. Using a 5 mm zero-degree laparoscope, the ovaries were inspected and an atraumatic grasper introduced to assess their mobility. While some have described a need to transect the utero-ovarian ligament to facilitate gonadal transposition, the maneuver was not necessary in this instance. Had this been necessary, it is our opinion that the ligament could have been ligated with ease using the TriPort™ alone.

The right inferior epigastric artery was identified and the anterolateral abdominal wall palpated to identify a site for fixation. A 2 mm transverse nick was made in the skin at this site. A ski needle with attached zero vicryl suture was introduced to the abdomen through the 2 mm incision. Using the atraumatic grasper and a laparoscopic needle driver, the suture was next passed through the right ovary. Finally, the suture was retrieved by passing the ski needle through the abdominal wall and 2 mm incision to a hand held needle driver. The suture was freed of its needle and secured to its other end using a hemostat. This process was repeated via the same 2 mm nick, allowing for fixation of the left ovary (video). With the ends of each suture protruding through the same right lower quadrant incision, extracorporeal knot tying was employed to fixate the gonads to the anterolateral abdominal wall. The dermis was elevated with Adson forceps, allowing the knots to be drawn deeper into the subcutaneous tissues. A topical skin adhesive was then applied to the site for closure (Fig. 2). The umbilical TriPort™ was removed and closure proceeded in the standard fashion.

2. Results

Informed consent was obtained from the patient, and an uncomplicated right anterolateral fixation procedure was performed on both ovaries. This was done utilizing SIPES. In this instance, an initial attempt was made at intracorporeal knot tying. Once the decision was made to employ transabdominal needle passage with extracorporeal knot tying, the operation proceeded in a more expeditious manner. Estimated blood loss was less than 5 mL, and the urinary catheter was removed at the end of the procedure.

Post-operatively, our patient was permitted oral intake with advancement as tolerated. While outpatient management was an option, the distance traveled by this patient made inpatient observation during the immediate post-operative period desirable. Oxycodone was available as needed for pain, and intravenous

Download English Version:

<https://daneshyari.com/en/article/4161364>

Download Persian Version:

<https://daneshyari.com/article/4161364>

[Daneshyari.com](https://daneshyari.com)