




available at [www.sciencedirect.com](http://www.sciencedirect.com)



journal homepage: <http://www.pediatr-neonatal.com>



## CASE REPORT

# Medulloblastoma Presenting With Pure Word Deafness: Report of One Case and Review of Literature

Yen-Ting Chou<sup>a</sup>, Po-Wu Liao<sup>b</sup>, Michael Che-Hung Lin<sup>c</sup>, Jih-Chyun Chou<sup>b,\*</sup>, Yung-Hsiu Lin<sup>a</sup>, Ming-Hung Lin<sup>a</sup>, Sai-Hung Tang<sup>d</sup>, Mei-Huei Chen<sup>a</sup>

<sup>a</sup> Department of Pediatrics, Cardinal Tien Hospital Yonghe Branch, New Taipei City, Taiwan

<sup>b</sup> Department of Otolaryngology, Cardinal Tien Hospital Yonghe Branch, New Taipei City, Taiwan

<sup>c</sup> Department of Radiology, Cardinal Tien Hospital Yonghe Branch, New Taipei City, Taiwan

<sup>d</sup> Department of Radiology, Cardinal Tien Hospital, New Taipei City, Taiwan

Received Mar 19, 2010; received in revised form Nov 2, 2010; accepted Nov 8, 2010

### Key Words

brain tumor;  
medulloblastoma;  
pure word deafness  
(PWD)

Pure word deafness (PWD) is a rare disorder characterized by impaired verbal comprehension sparing discrimination and recognition of nonverbal sounds with relatively normal spontaneous speech, writing, and reading comprehension. Etiologies of this syndrome are varied, and there are rare reports about brain tumor with PWD in children. We report a case of medulloblastoma presented with PWD in a 7-year-old girl. She visited our outpatient clinic because of English dictation performance deterioration. PWD was diagnosed by the otolaryngologist after examinations. Posterior fossa tumor and obstructive hydrocephalus were shown in the magnetic resonance imaging of the brain. The diagnosis of medulloblastoma was then made by pathology.

Copyright © 2011, Taiwan Pediatric Association. Published by Elsevier Taiwan LLC. All rights reserved.

## 1. Introduction

Pure word deafness (PWD) is a rare neurological syndrome characterized by defective comprehension, repetition, and

writing to dictation with preserved ability to identify nonverbal sounds. The reading comprehension, writing, and spontaneous speaking ability remain normal. It was first described by Kussmaul<sup>1</sup> in 1877 and later by Lichtheim<sup>2</sup> in 1885. Defects in auditory processing,<sup>3–6</sup> temporal resolution,<sup>5</sup> phonemic discrimination,<sup>7–9</sup> or prephonemic discrimination<sup>6</sup> have been implicated in this disease. Brain lesions involving areas dominating these neurological functions can cause PWD. PWD caused by cerebrovascular

\* Corresponding author. Department of Otolaryngology, Cardinal Tien Hospital Yonghe Branch, No. 80, Zhongxing Street, Yonghe District, New Taipei City 234, Taiwan.

E-mail address: [jcchou@mail2000.com.tw](mailto:jcchou@mail2000.com.tw) (J.-C. Chou).

accidents has been most frequently reported in the literature.<sup>10–12</sup> Epilepsy,<sup>13</sup> head injury,<sup>14</sup> neurodegenerative disease,<sup>15–17</sup> infection,<sup>18</sup> intoxication,<sup>19</sup> and complications of brain surgery<sup>20,21</sup> associated with PWD were also described. Literature reports about brain tumor presenting with PWD are rare.<sup>22,23</sup> We report the case of a 7-year-old girl in whom medulloblastoma developed with an unusual clinical presentation of PWD. Possible mechanisms of this condition are reviewed and discussed.

## 2. Case Report

This patient was a 7-year-old right-handed girl whose mother tongue was Chinese. She had had a normal psychomotor developmental milestone since childhood. She also had very good school performance and had danced ballet well before. She was brought to our otolaryngology outpatient clinic by her mother because of recent English dictation performance deterioration. She could not understand the speech in recent English dictation tests, although she could hear other noise clearly and still understood Chinese well. The onset had been sudden. A hearing problem was suspected by her parents. There was no headache, vertigo, nausea, weakness, or consciousness disturbance with the onset of symptoms. Also, transient tinnitus, lasting for 1–2 days, had been complained of 1 month before visiting our hospital.

On otolaryngology examinations, pure-tone audiometry showed bilateral low-tone sensorineural hearing loss (Figure 1). Speech reception threshold was acceptable compared with her mean hearing threshold. Speech discrimination was normal over the right side but poor over the left side. The patient could only repeat with a similar sound in which the consonant component was different from the given word in Chinese. The acoustic reflex was absent bilaterally. The diagnosis of central auditory processing disorder was made by the otolaryngologist. Then the patient was referred to a pediatric neurologist's outpatient clinic for further evaluation.

In the pediatrician's clinic, the patient was conscious and oriented. She could understand all written commands,

and naming of visual objects was normal. On neurological examinations, she had full muscle power and normal plantar reflex. The eye movement was full without nystagmus. She had symmetrical facial expression. There was neither dysmetria nor dysidiadochokinesia. Although she had a normal and stable gait in daily walking, slightly ataxic gait with left-side deviation was found during the tandem gait testing. Because of the suspicion of organic brain lesion, brain magnetic resonance imaging was arranged, and it showed a mass lesion in the cerebellum with obstructive hydrocephalus (Figure 2). The patient was then referred to a medical center for further surgical treatment. Medulloblastoma was diagnosed by pathology. The cerebrospinal fluid cytology revealed no tumor cell. Pure-tone audiometry revealed a normal result after tumor excision and ventriculoperitoneal shunt insertion. Then the girl received radiotherapy and chemotherapy for medulloblastoma.

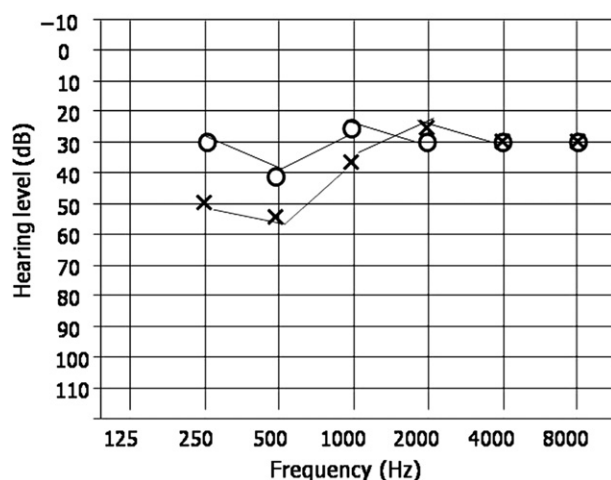
## 3. Discussion

In our patient, the pure-tone audiometric test could not account for her auditory comprehension deficits, suggesting an agnosia for sounds. When the deficit was only limited to linguistic sounds, the diagnosis of PWD was made.

PWD is an uncommon neurological disorder that manifests as auditory dysfunction, in which the integrity of the speech comprehension system is compromised selectively. On the other hand, the abilities to speak, read, and write remain normal. Cerebrovascular accidents causing PWD have been most frequently reported.<sup>10–12</sup> Brain tumor presenting with PWD is a rare condition. Papillary ependymoma, germinoma, and tentorial meningioma have been reported to be associated with PWD.<sup>22,23</sup> We postulate that our patient's word deafness was a rare initial presentation of brain tumor. To our knowledge, this is the first case report of medulloblastoma presenting with PWD in the pediatric group. That may be because of poor subjective symptom expression of the pediatric group in the early stage, leading to the family or the physician focusing on the later symptoms or signs resulting from brain tumor progression, such as increased intracranial pressure, ataxia, or other severe disabilities.

Localization of the brain lesion causing this entity has been debated. Two types of focal damage have been implicated.<sup>24</sup> The most common one is functionally isolating auditory association cortex from auditory input because of lesions in the speech-dominant hemisphere's Heschl's gyrus and related white matter.<sup>25</sup> The second is bilateral temporal area focal damage, usually involving the middle portions of the first temporal gyrus.<sup>10,25,26</sup> In addition, word deafness has also been reported after incision of the splenium in the corpus callosum<sup>27</sup> and subcortical lesions.<sup>28–30</sup> Brainstem lesions partly disconnecting the auditory cortex from the auditory nucleus and disrupting the initial auditory process has also been proposed.<sup>31</sup>

How can brain tumor cause PWD? In Karibe et al's<sup>22</sup> report, PWD was considered as a diaschisis resulting from the isolation of left temporal lobe from auditory input by means of bilateral medial geniculate bodies. Compressive effect of the tumor on the thalamocortical auditory



**Figure 1** Pure-tone audiometry showed bilateral low-tone loss, especially over the left side. O = right ear; X = left ear.

Download English Version:

<https://daneshyari.com/en/article/4175369>

Download Persian Version:

<https://daneshyari.com/article/4175369>

[Daneshyari.com](https://daneshyari.com)