



Case report

Cervical esophagotomy for foreign body extraction – Case report and comprehensive review of the literature



Patrick Heger^a, Tim F. Weber^b, Johannes Rehm^b, Anita Pathil^c, Frank Decker^d,
Peter Schemmer^{a,*}

^a Department of General, Visceral and Transplant Surgery, University Hospital Heidelberg, 69120, Germany

^b Department of Diagnostic and Interventional Radiology, University Hospital Heidelberg, 69120, Germany

^c Department of Gastroenterology, University Hospital Heidelberg, 69120, Germany

^d Department of Otolaryngology, University Hospital Heidelberg, 69120, Germany

H I G H L I G H T S

- A case of cervical esophagotomy for foreign body extraction is described.
- Systematic review of literature shows 29 patients undergoing esophagotomy.
- Complication rates after esophagotomy are justifiable.
- Cervical esophagotomy is a feasible surgical approach.
- A clinical management guideline is provided.

A R T I C L E I N F O

Article history:

Received 10 February 2016

Received in revised form

1 April 2016

Accepted 2 April 2016

Keywords:

Foreign body removal

Esophagus

Esophagotomy

Case report

A B S T R A C T

Introduction: Esophageal foreign bodies are an important and serious cause of morbidity and mortality in both children and adults. Due to the possibility of serious complications, i.e. perforation, necrosis, mediastinitis, and fistulation, rapid and accurate diagnostic measures with subsequent therapy are necessary.

Case report: We are reporting a case of a 55-year-old, mentally impaired patient that has swallowed a foreign body, which subsequently became lodged in his esophagus. Due to the fact that endoscopic removal was not possible and there was a high risk of complications such as esophageal perforation or mediastinitis in this case, we performed cervical esophagotomy and successfully extracted the foreign body. The patient showed an uneventful postoperative process and could be discharged on Day 11 after the operation.

Comprehensive review: Furthermore, we performed a systematic review of the literature to identify all studies that described a surgical approach through esophagotomy in cases of foreign body ingestion and found 11 publications describing the cases of 29 patients. These studies reported an overall complication rate of 17.2% and a mortality rate of 0%.

Conclusion: Our findings suggest that esophagotomy could be a viable approach for the extraction of foreign bodies especially in some cases when endoscopic removal was not successful and the risk of esophageal perforation is high.

© 2016 The Authors. Published by Elsevier Ltd on behalf of IJS Publishing Group Ltd. This is an open access article under the CC BY-NC-ND license (<http://creativecommons.org/licenses/by-nc-nd/4.0/>).

1. Introduction

The presence of foreign bodies in the esophagus, which mostly occurs when objects are accidentally swallowed, is an important and serious cause of morbidity and mortality in both children and adults. The symptoms may vary, depending on the size, nature, location, and the amount of time that has passed between the

* Corresponding author. Department of General, Visceral and Transplant Surgery, University Hospital Heidelberg, Im Neuenheimer Feld 110, 69120 Heidelberg, Germany.

E-mail address: peter.schemmer@med.uni-heidelberg.de (P. Schemmer).

occurrence of the accident and medical treatment [1]. Due to the possibility of serious complications, i.e. perforation, necrosis, mediastinitis, and fistulation, rapid and accurate diagnostic measures with subsequent therapy are necessary [2].

2. Case report

A 55-year-old, mentally impaired, male patient was admitted to the Gastroenterological Department at University Hospital Heidelberg complaining of dysphagia and odynophagia after supposedly having swallowed a foreign body, which subsequently became lodged in his esophagus.

The patient presented with a reduced but stable general condition breathing spontaneously with an increased heart rate of 115 bpm, and a blood pressure of 150/90 mmHg. The laboratory findings were within normal levels, particularly the infectious parameters, which showed no signs of the presence of inflammation. After taking X-rays of the chest, we performed a CT scan for further diagnostic investigation.

In the CT scan of the chest and neck region (Fig. 1), there was evidence of a mass-forming, circular lesion with predominant fluid density involving the cervical esophagus just below the upper esophageal sphincter. The esophageal wall could not be properly identified in this part of the scan. There was no clear evidence of the presence of a radiopaque foreign body and no signs of pneumomediastinum. Furthermore, there were signs of pulmonary infiltration in the left upper and lower lobes (Fig. 2). Radiological differential diagnoses included periesophageal fluid collection as a result of esophageal perforation or distention of the esophageal lumen by a large non-radiopaque foreign body.

For the removal of the foreign body, the patient was intubated and ventilated in preparation for flexible endoscopy of the esophagus. The presence of a 5-point plastic star (Fig. 3), usually containing a LED light and being part of a Christmas fairy lights, was confirmed. However, due to the object's geometry, removal with flexible endoscopy was not possible. Since the star was located in the upper esophagus at 15 cm from the alignment, another attempt to remove the star with rigid endoscopy was performed by the otolaryngologists. Unfortunately, it was not possible with one of the various instruments available to get a sufficient hold on the star for removal.

Thus, the patient was transferred to the Department of General, Visceral, and Transplant Surgery of the University Hospital Heidelberg, where surgical removal was indicated.

Based on the location of the swallowed star in the upper esophagus, it was decided to open the esophagus via the cervical approach. Briefly, a 12 cm skin incision on the left side of the

patient's neck along the leading edge of the sternocleidomastoid muscle was performed. The sternocleidomastoid muscle and omohyoid muscle, as well as the pretracheal muscles, were retracted laterally and medially to expose the carotid sheath. Preparation (dorsally down to the prevertebral fascia) was performed for exposure of the esophagus. The esophagus was encircled with a silicon band and stay sutures were placed laterally of the future longitudinal incision of the esophagus. It was possible to get a hold on the star with a Kelly clamp and the foreign body was removed in an uneventful procedure without further damage to the esophagus (Figs. 4 and 5). The esophageal wall showed no signs of perforation or notable superficial injuries. A soft nasogastric tube was inserted and the esophagotomy was closed with an interrupted suture using 4-0 PDS. A small easy-flow drain was placed in the paraesophageal area and skin closure was subsequently performed.

Postoperatively, the nasogastric tube was left in place and the patient was on parenteral nourishment with only sips of water as an oral intake for 48 hours. After that, oral feeding was slowly reestablished without complication, and the easy-flow drain was removed. The patient could be discharged on Day 11 after the operation.

3. Comprehensive review

We conducted searches of MEDLINE, the Cochrane Central Register of Controlled Trials (CENTRAL), and the Cochrane Database of Systematic Reviews (CDSR) on March 15, 2015 to identify all randomized controlled trials (RCTs), clinical trials, retrospective analyses, and case reports that deal with the use of cervical or thoracic esophagotomy to extract esophageal foreign bodies. The search terms were “foreign body”, “foreign bodies”, “esophagotomy”, and “oesophagotomy”.

We identified 62 records through our search of the databases, of which, 16 had to be removed after reading the title and abstract because they reported non-surgical or veterinarian results. 46 full-text articles were assessed for eligibility and screened for applicability. We found no RCTs, clinical trials or retrospective analyses, but there was a total number of 11 case reports [3–13] that described surgical approaches via esophagotomy in overall 29 patients with foreign body ingestion. In all of these cases, the decision for the surgical therapy was made because either one of the described complications of esophageal foreign bodies, especially perforation, was existent or attempts to extract the foreign body via flexible or rigid endoscopy were unsuccessful. In the 29 cases of cervical or thoracic esophagotomy for foreign body extraction, there were 24 uneventful healing processes, one that reported esophageal suture line dehiscence with possibly preexisting esophageal necrosis as a

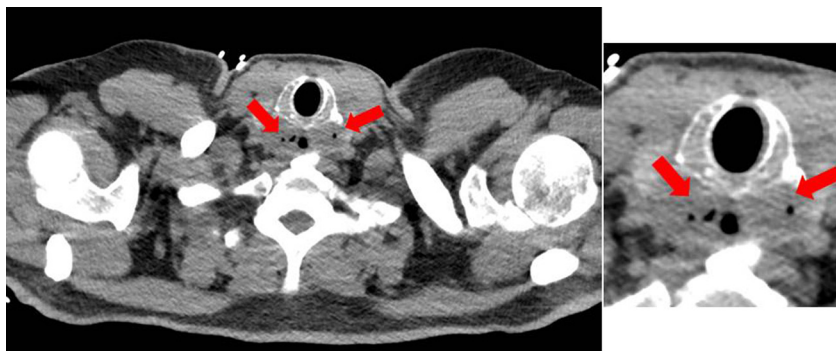


Fig. 1. Evidence of a mass-forming circular lesion with predominant fluid-density involving the cervical esophagus just below the upper esophageal sphincter. Enlargement on the right side.

Download English Version:

<https://daneshyari.com/en/article/4195178>

Download Persian Version:

<https://daneshyari.com/article/4195178>

[Daneshyari.com](https://daneshyari.com)