



Contents lists available at ScienceDirect

Annals of Medicine and Surgery

journal homepage: www.annalsjournal.com

Case report

Merkel cell carcinoma of unknown primary site; case presentation and review of the literature



Elissaios Kontis ^{a,*}, Antonios Vezakis ^a, Eirini Pantiora ^a, Sotiria Stasinopoulou ^b,
Andreas Polydorou ^a, Dionysios Voros ^a, Georgios P. Fragulidis ^a

^a 2nd Department of Surgery, Aretaieio Hospital, University of Athens, School of Medicine, Athens, Greece

^b Department of Pathology, Aretaieio Hospital, University of Athens, School of Medicine, Athens, Greece

HIGHLIGHTS

- Unknown Primary Merkel cell carcinoma is a rare NET, which usually presents with extensive lymph node involvement.
- This tumor follows a more indolent natural course than a Merkel cell carcinoma of known primary and of similar staging.
- Surgical excision with R0 resection remains a common practice in the management of unknown primary Merkel cell carcinoma.
- Adjuvant chemotherapy after R0 resection is the usual practice, despite the lack of good quality literature evidence.

ARTICLE INFO

Article history:

Received 5 August 2015

Received in revised form

20 October 2015

Accepted 21 October 2015

Keywords:

Merkel cell

Unknown primary site

Surgical management

Lymphadenopathy

ABSTRACT

Merkel cell carcinoma (MCC) is a rare skin malignancy associated with sun exposure and considered as a Neuroendocrine Tumor due to its characteristic histologic features. However there is increasing number of reports of Unknown Primary MCC's (UPMCC). Although initially UPMCC was considered a variant of known primary MCC, there is growing evidence that it could represent a different clinical entity.

We present the case of a 60 year-old male patient who was referred to our department for surgical management of lymph node disease for UPMCC. The patient had undergone excisional biopsy of an inguinal lump, which was found to be an infiltrated lymph node by MCC. The patient underwent full imaging staging including a PET/CT, which failed to identify a primary site, and revealed only intra-abdominal lymph node disease. The patient underwent extended retroperitoneal and inguinal lymph node dissection and remains free of recurrence 16 months postoperatively.

© 2015 The Authors. Published by Elsevier Ltd on behalf of IJS Publishing Group Limited. This is an open access article under the CC BY-NC-ND license (<http://creativecommons.org/licenses/by-nc-nd/4.0/>).

1. Introduction

Merkel cell carcinoma (MCC) represents a rare skin cancer associated with sun exposure affecting mainly Caucasian males over the 6th decade [1,2]. Although the origin of Merkel cell has been debated, MCC is considered a Neuroendocrine tumor (NET) due to its characteristic histopathologic appearance expressing CD56, neurofilament protein (NFP), Chromogranin A, etc [2,3]. However there is growing evidence in the literature of metastatic histologically-proven MCC with unidentified primary site.

Neuroendocrine cancers of unknown primary account for 13% off NET's [3] and the incidence of MCC of unknown primary has been estimated to be as high as 25% of all MCC [4].

We present a case of 60 year-old patient who underwent a diagnostic biopsy of an inguinal lump at his local hospital which was proven to be an infiltrated lymph node by an MCC. Following his imaging staging with CT and PET scan, which showed only abdominal lymph node disease, he was referred to our department for surgical management.

1.1. Case presentation

A 60 year-old man presented to his local hospital for investigation of an incidental finding of a bulge in the left inguinal area. His past medical history included hypertension and diabetes mellitus. This swelling was found to be an enlarged lymph node and the patient underwent excisional biopsy. On pathology examination,

List of abbreviations: MCC, Merkel cell carcinoma; NET, neuroendocrine tumor; UPMCC, unknown primary Merkel cell carcinoma; PET/CT, positron emission tomography/computed tomography; SUV, standardized uptake value; HPF, high, power field; AJCC, American Joint Committee on Cancer.

* Corresponding author.

E-mail address: kontiselissaios@gmail.com (E. Kontis).

the lymph node was found to have features of a Neuroendocrine Tumor (NET), compatible with MCC. Following the results of the biopsy the patient was referred to our hospital for further management.

Upon admission to our department, clinical examination failed to reveal any skin lesions suspicious for a primary site of MCC. The screening tests for NET with NSE and Chromogranin A were negative. A Chest, Abdomen and Pelvis CT scan, revealed enlarged aortic and iliac lymph nodes. To exclude a missed primary site or other sites of metastatic disease a PET/CT was performed. The PET/CT confirmed intra-abdominal lymph node limited disease, with increased uptake at two sites; just below the left kidney with SUV max of 6.8 and at the level of the left iliac fossa with SUV max of 8.5 (Fig. 1). Also the slides from the initial lymph node biopsy were reviewed in our department where the positive immunohistochemical stainings for CK20 and synaptophysin were confirmed as well as negativity for TTF-1 staining. Given the findings of lymph node metastatic disease in the absence of a known primary MCC or other malignancy, the diagnosis of UPMCC was established.

The patient underwent an extended retroperitoneal lymph node dissection: retroperitoneally along the aorta extending ipsilaterally to the pelvis along the left external iliac vessels, up to the level of the left internal inguinal ring. At laparotomy, from cephalad to caudal the following enlarged lymph node blocks were found: (a) just above the left renal vein, (b) just below the left renal vein, (c) beside the left external iliac vein. Also a wide excision of the overlying skin of the left inguinal area including the site of the previous biopsy along with the corresponding inguinal and femoral lymph node dissection was performed (Fig. 2).

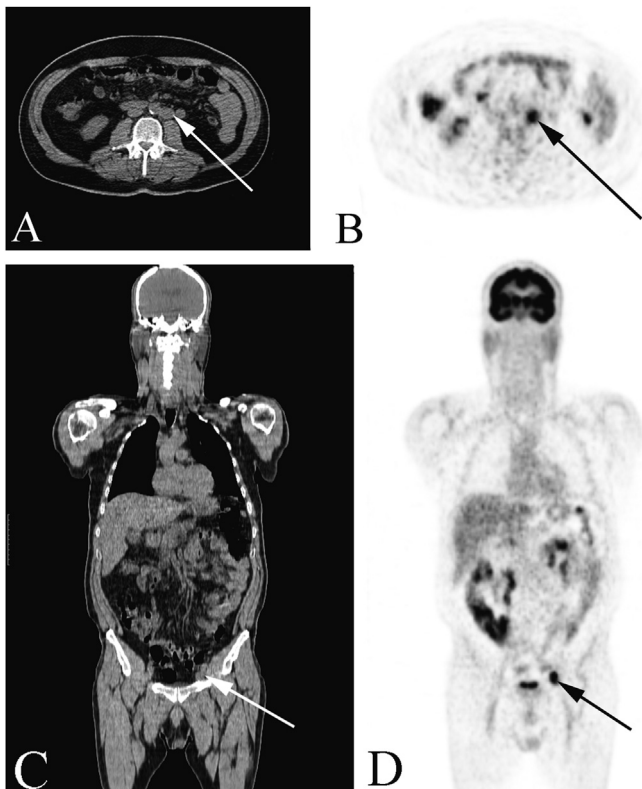


Fig. 1. Comparative view of the PET/CT images depicting the two “hot sites” with increased uptake. A. Left paraortic block at the level of the renal vein measuring approximately 26.9 mm (white arrow) and (B) the corresponding view of the PET scan (black arrow). C. Block at the left external iliac vessels measuring 27.2 mm at the level of left internal inguinal ring (white arrow) and (D) the corresponding view of the PET scan (black arrow).

On histology, 27 lymph nodes were identified within the specimen. In detail, 2 out of 5 lymph nodes from the infrarenal block and 1 out of 8 lymph nodes from the inguinal block were found infiltrated from metastatic NET. The remaining 14 lymph nodes from other sites had no histological signs of infiltration. No evidence of a primary site was found at the excised overlying skin or subcutaneous tissue. The immunohistochemical staining for CK20, CD56, synaptophysin, Chromogranin and NSE were positive with a Ki67 of 60%, while the CK7, LCA, TTF1 and CDX-2 were negative (Fig. 3A). Also there was a high mitotic index with >20 mitoses/HPF (Fig. 3B), confirming the diagnosis of UPMCC.

Postoperatively the patient has received 6 cycles of chemotherapy with cisplatin and etoposide, given the radical lymph node excision (R0) and minimal lymph node involvement in the specimen. He has been asymptomatic since and free of recurrence 16-months postoperatively on regular follow-up with bi-annual CT of the chest-abdomen and pelvis during the first year post adjuvant chemotherapy and annual CT scan thereafter.

2. Discussion

MCC of unknown primary (UPMCC) remains an aggressive NET. Since the initial report of lymph node metastatic UPMCC, in 1988 [5], the estimated total number of cases in the literature up to today remains less than 200 [6]. It follows that UPMCC remains a rare malignancy where little is known in terms of presentation, natural course and best management approach. The diagnosis of UPMCC needs to fulfill both clinical and histologic criteria; a patient presenting with clinical lymph node positive disease without a previously diagnosed or identifiable primary tumor (MCC or NET). Furthermore on immunohistochemical staining it is necessary to express the pattern of CK20 positivity along with positivity for any of the neuroendocrine markers such as, Chromogranin A, synaptophysin or neuron specific enolase (NSE) and negative TTF-1 staining [7].

The origin of MCC has been debated and both neural crest cells as well as epithelial cells have been implicated [8]. Due to the rarity of this malignancy it has not yet been delineated in the case of metastatic to lymph nodes UPMCC, if the tumor arises de novo from neural cells located within the involved lymph nodes or if the primary lesion undergoes spontaneous regression [3,9]. This matter remains of utmost importance as the natural history between

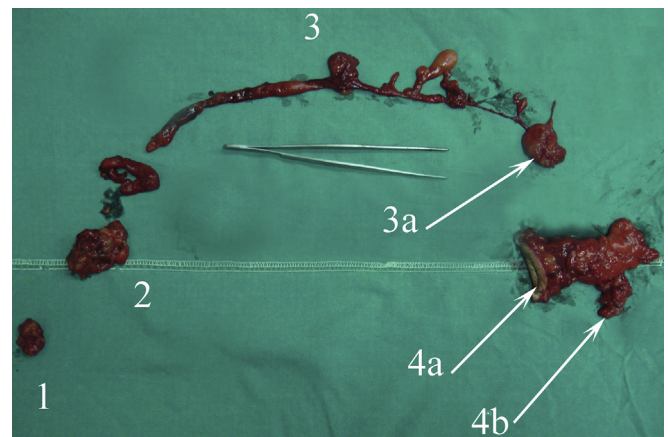


Fig. 2. Photograph of the surgical specimen aligned at its anatomical continuity; 1: Suprarenal node block, 2: Infrarenal block, 3: paraortic lymph node chain extending to the iliac vessels, 3a: external iliac lymph node block, 4a: skin overlying the previous site along with the superficial inguinal lymph nodes, extending to the femoral lymph nodes (4b).

Download English Version:

<https://daneshyari.com/en/article/4195346>

Download Persian Version:

<https://daneshyari.com/article/4195346>

[Daneshyari.com](https://daneshyari.com)