



Case report

Retroperitoneal fibrosis with periaortitis: A case report of an unusual form of presentation of granulomatosis with polyangiitis



Elizabeth Manuely González Revilla^{*}, Araceli Abad Fernandez, María Teresa Río Ramirez, Sara Calero Pardo, María Antonia Juretschke Moragues

Hospital Universitario de Getafe, Madrid, Espana

ARTICLE INFO

Article history:

Received 4 July 2015

Received in revised form

20 August 2016

Accepted 24 August 2016

Keywords:

C. ANCA-Positive periaortic vasculitis

Retroperitoneal fibrosis

ABSTRACT

Granulomatosis with polyangiitis (GPA) is the name that has been used in recent years for Wegener's granulomatosis. This condition is a systemic inflammatory disease characterised by necrotizing vasculitis that affects small and medium-sized blood vessels (capillaries, arterioles, venules and arteries). The granulomatous inflammation affects the respiratory system; it also commonly affects the kidney and can very rarely affect large vessels such as the aorta and the surrounding retroperitoneal tissue. Early diagnosis and treatment is of vital importance because of the high risk of dissection and of obstruction of retroperitoneal structures.

We present the case of a 74-year-old man with a past history of infrarenal abdominal aortic aneurysm. He consulted for abdominal pain. Cavitating pulmonary nodules and retroperitoneal fibrosis with periaortic alterations were detected on computed tomography. Laboratory investigations revealed that the patient was positive for cytoplasmic antineutrophil cytoplasmic antibodies (c-ANCA) and necrotizing granulomas were observed on biopsies of the lung lesions and retroperitoneal tissue. The patient was diagnosed with GPA and treatment was started with glucocorticoids and immunosuppressive agents, which led to a significant clinical and radiological improvement over the following months.

© 2016 The Authors. Published by Elsevier Ltd. This is an open access article under the CC BY-NC-ND license (<http://creativecommons.org/licenses/by-nc-nd/4.0/>).

1. Introduction

Granulomatosis with polyangiitis (GPA) is defined as a systemic disease characterised by necrotizing granulomatous vasculitis that affects small and medium-sized blood vessels such as arterioles, capillaries, venules and arteries. The condition was previously known as Wegener's granulomatosis. It is a rare disease, with a prevalence of 25–160 cases per million population and an incidence of 0.4 cases per 100,000 population/year. It is more common in men of Caucasian origin aged over 40 years, although it can appear at any age. The principal feature of the disease is involvement of the respiratory apparatus, affected from the outset in more than 90% of cases, with the kidney also being affected during the course of the disease. Other structures, such as the retroperitoneal tissue or large vessels, including the aorta, are rarely involved, and these changes are therefore liable to be missed during clinical evaluation; this is important because of the high associated risk of

dissection or the obstruction of local structures by the granulomatous inflammation. We present a case of GPA with classic nasal, upper airways and lung involvement associated with alterations of the aorta and retroperitoneal fibrosis. We describe the initial presentation of the disease in this patient and its clinical course after diagnosis and the initiation of medical treatment.

2. Case description

The patient was a 74-year-old man with a past history of hypertension and dyslipidemia. He had a cumulative smoking index of 60 pack-years, though he had stopped smoking four years earlier when he underwent aortobifemoral bypass surgery for an infrarenal abdominal aortic aneurysm. No occupational exposure to asbestos. He attended the hospital for a 30-day history of continuous pain over the right renal angle, radiating to the contralateral renal angle, associated with dark urine. He was afebrile and presented no other symptoms. On admission, the patient was haemodynamically stable and physical examination was unremarkable; there were no signs of peritoneal irritation and percussion over the renal angle was negative bilaterally. Blood tests

^{*} Corresponding author.

E-mail address: elizabethmanuely@gmail.com (E.M. González Revilla).

and routine urinalysis detected a small rise in the acute phase reactants and a deterioration in renal function (C-reactive protein [CRP], 91 mg/L; procalcitonin, 0.24 ng/dl; creatinine, 1.47 mg/dl). Given the patient's history of surgery for vascular disease, abdominal computed tomography (CT) was performed; this revealed the presence of a concentric soft tissue mass around the infrarenal abdominal aorta associated with left-sided ureterohydronephrosis, in addition to multiple pulmonary nodules and a bilateral pleural effusion (Fig. 1A).

Based on these findings and a suspected septic complication of the aortobifemoral graft, empirical antibiotic therapy was started with meropenem and vancomycin, after performing blood and urine cultures, all of which were negative. On fibre-optic bronchoscopy, the glottis was normal and no significant lesions were observed in the trachea, carina or bronchial systems. The only abnormality observed was a thickened and oedematous mucosa in the lower lobes and right upper lobe. The microbiology samples were negative for fungi, bacterial gram stain and culture, Ziehl-Neelsen stain, polymerase chain reaction and culture for mycobacteria. A bronchial biopsy was taken and showed signs of acute suppurative and chronic granulomatous inflammation with tissue eosinophilia, but there were no signs of malignancy. Immunological studies were positive for antinuclear antibodies (1/80), anti-neutrophil cytoplasmic antibodies (ANCA) (1/20) and anti-proteinase 3 (PR3) antibodies, 38.0 IU/ml (normal range, 0.0–2.0 IU/ml).

No vegetations or intracavitary thrombi were observed on transoesophageal echocardiography. Positron emission tomography-CT (PET-CT) revealed a pathological increase in glucose metabolism in the pulmonary nodules (SUVmax, 6.92), as well as an intense pathological increase in glucose metabolism in the retroperitoneal soft tissue mass surrounding the infrarenal abdominal aorta down to the level of the bifurcation, with an SUVmax of 6.3. (Fig. 2). Tomography of the paranasal sinuses performed for a two-week history of bloodstained nasal discharge revealed polypoid thickening of the mucosa of both maxillary sinuses, obliteration of both semilunar hiatuses and a lesion occupying the most inferior part of the frontal sinus, causing obliteration of the sinus ostia. The pathology report of a biopsy taken from the septum of the left nasal fossa described extensive erosive changes, squamous metaplasia and a dense mixed inflammatory infiltrate. As these findings were non-specific a biopsy was taken from the retroperitoneal tissue. Histology revealed acute suppurative and chronic inflammation with necrotizing

granulomas and areas suggestive of vasculitis, but no bacterial or mycobacterial growth (see Fig. 3).

Renal function improved significantly after the creation of a nephrostomy to resolve the ureterohydronephrosis caused by external compression. Studies of the urinary sediment were normal throughout the diagnostic workup. The urinary sediment was normal and cultures were negative.

Based on these results, we made a diagnosis of GPA with pulmonary and periaortic involvement, associated with retroperitoneal fibrosis. Immunosuppressive therapy was therefore prescribed with glucocorticoids, 1 mg/kg for 3 days, and methotrexate, 20 mg per week, and this led to a clinical and radiological improvement. One month after starting treatment we observed a radiological improvement with a marked reduction in the size of all the multicentric nodular pulmonary lesions and of the concentric soft-tissue cuff around the infrarenal abdominal aorta (Fig. 1B). There was a simultaneous improvement in the severity of epistaxis and the abdominal pain resolved and did not recur after treatment. In addition, the acute phase reactants normalised (CRP, <2.9 mg/dl) during the weeks after the initiation of immunosuppressive therapy.

3. Discussion

We have described the case of a patient in whom the first symptom of granulomatosis with polyangiitis was abdominal pain, caused by periaortic retroperitoneal fibrosis with the compression of local structures. As this alteration is relatively rare, a lack of diagnostic suspicion can delay the initiation of treatment and allow the disease to progress. Retroperitoneal fibrosis and periaortic involvement are very rare in granulomatosis with polyangiitis. The incidence of retroperitoneal fibrosis is 0.1 per 100,000 population/year and a prevalence of 1.4 per 100,000 population; 70% of cases are idiopathic [1] and the association with smoking and exposure to asbestos is described as a strong risk factor [18]. Early diagnosis and treatment is of vital importance due to the high risk of dissection and of obstruction of retroperitoneal structures.[2].

In idiopathic retroperitoneal fibrosis; the retroperitoneal tissue consisted of a fibrous component and a chronic inflammatory infiltrate with the former characterised by myofibroblasts within a type-I collagen matrix [19]. In our case, the histology revealed acute suppurative and chronic inflammation with necrotizing granulomas and areas suggestive of vasculitis; which justifies the association with the other systemic manifestations of granulomatosis

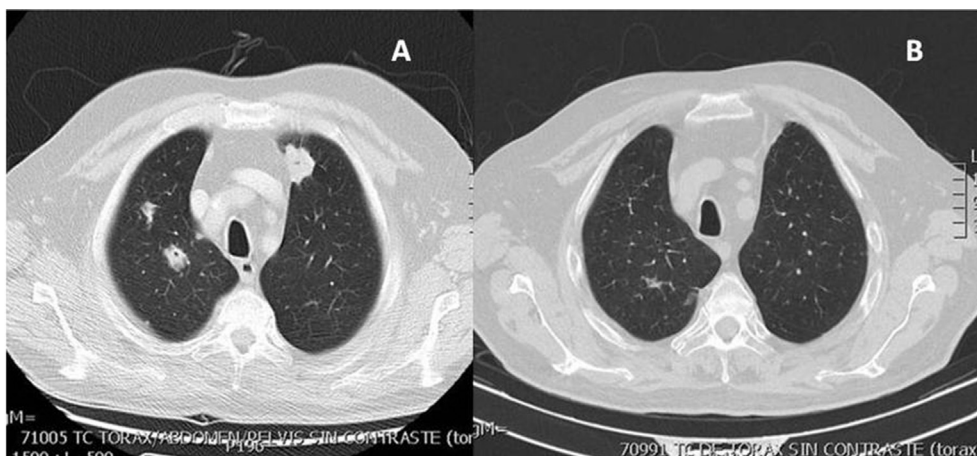


Fig. 1. A, Multiple bilateral cavitating pulmonary lesions. B, Image 3 months after treatment: there is a reduction in the overall size of the nodular pulmonary lesions, with residual millimetric changes.

Download English Version:

<https://daneshyari.com/en/article/4212589>

Download Persian Version:

<https://daneshyari.com/article/4212589>

[Daneshyari.com](https://daneshyari.com)