



Case report

Common variable immunodeficiency diagnosed during the treatment of bronchial asthma: Unusual cause of wheezing



Tomohiro Akaba^a, Mitsuko Kondo^a, Midori Toriyama^a, Ayako Kubo^a, Kaori Hara^a, Takeshi Yamada^a, Kentaro Yoshinaga^b, Jun Tamaoki^{a,*}

^a First Department of Medicine, Tokyo Women's Medical University, Tokyo, Japan

^b Department of Hematology, Tokyo Women's Medical University, Tokyo, Japan

ARTICLE INFO

Article history:

Received 28 May 2015

Received in revised form

7 July 2015

Accepted 8 July 2015

Keywords:

Primary immunodeficiency

Common variable immunodeficiency

Bronchial asthma

Wheezes

Airway infection

Hypogammaglobulinemia

ABSTRACT

Common variable immunodeficiency (CVID) is the most frequent primary immunodeficiency in adults and children. We herein report a case of CVID, who was misdiagnosed with asthma due to wheezing episodes and relatively late onset. A 51-year-old woman had suffered from recurrent upper and lower airway infection for recent 2 years. She repeated wheezing attacks and was treated as asthma exacerbation triggered by infection. She was referred to our hospital for investigation and treatment. Lung function tests showed no reversibility of FEV₁ by β -adrenergic agonist, but the increase of V₅₀/V₂₅. Chest CT showed slight to moderate bronchial wall thickening and bronchiectasis. After that, she suffered from pneumonia with wheezing attacks twice a month, and immunodeficiency was strongly suspected. Her blood tests showed marked decreases of all classes of immunoglobulin and nearly lack of memory B cells, NKT cells and plasmacytoid dendritic cells. She was diagnosed with CVID, and was treated with replacement of gammaglobulin. Thereafter, her wheezing episodes with infection were remarkably improved. Because the delay of diagnosis with CVID likely causes poor mortality and morbidity, a possibility of CVID should be considered in patients with frequent asthma-like symptoms due to recurrent airway infection.

© 2015 The Authors. Published by Elsevier Ltd. This is an open access article under the CC BY-NC-ND license (<http://creativecommons.org/licenses/by-nc-nd/4.0/>).

1. Introduction

Common variable immunodeficiency (CVID) is the most frequent cause of primary immunodeficiency characterized by hypogammaglobulinemia, recurrent infection and poor response to vaccination [1–4]. The diagnosis of CVID tends to be delayed compared to other primary immunodeficiencies, because some cases are late onset. Besides, episodic airway infection causes airway remodeling and secondary to bronchial wall thickening or bronchiectasis. Therefore, there may be a risk of misdiagnosing as bronchial asthma or other chronic pulmonary disease. We herein report a case of CVID who had been treated as bronchial asthma because of wheezing attacks.

2. Case report

A 51-year-old woman had suffered from recurrent airway infection and otitis media for recent two years. At first, she visited primary care clinic and she was diagnosed with asthma attack. After that, wheezing episodes recurred and she had been treated with antibiotics and oral glucocorticoid as well as bronchodilators. In addition, she received a pneumococcal polysaccharide vaccine (Pneumovax[®]) to prevent recurrent airway infection. Despite of these procedures, she repeated wheezing episodes and she was referred to our hospital for further investigation and treatment. She had no past medical history, no smoking history and no allergies. No notable family history of immunodeficiency was detected. As she was working as a child minder, she had a risk of frequent sick contact. Lung function tests showed no reversibility of FEV₁ by the β -adrenergic agonist salbutamol, but V₅₀/V₂₅ in flow-volume curve was elevated to 4.55, suggesting the existence of peripheral airway

* Corresponding author.

E-mail address: jtamaoki@chi.twmu.ac.jp (J. Tamaoki).

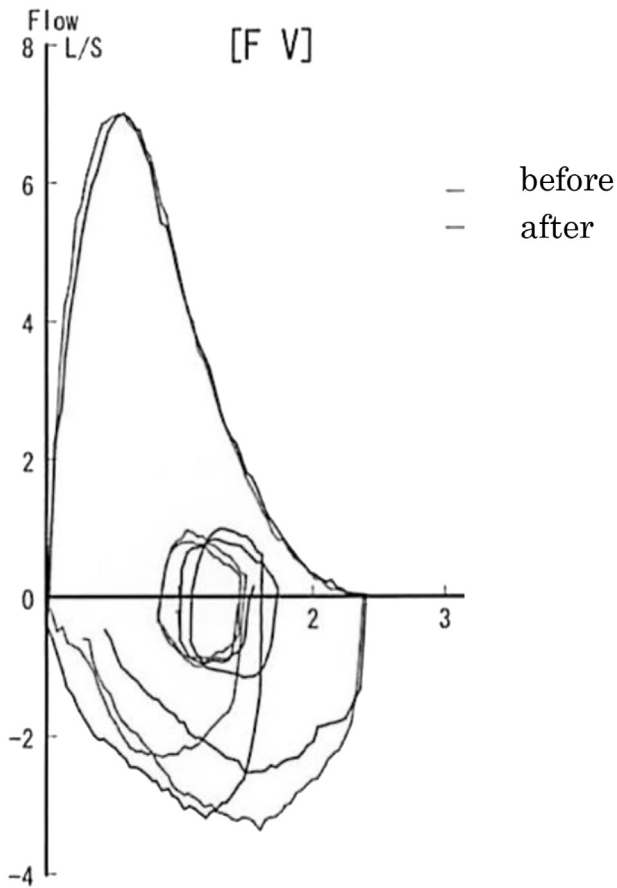


Fig. 1. Flow-volume curve was almost overlapped before and after inhalation of β_2 -stimulant. It revealed no reversibility after inhalation. Although both %VC and FEV 1% were within normal limit, the flow-volume curve was convex downward and the level of V_{50}/V_{25} was increased.

obstruction (Fig. 1). Chest CT showed slight to moderate bronchial wall thickening and bronchiectasis, and she was given a combination of the inhaled corticosteroid (ICS) budesonide and the long-acting β -adrenergic agonist formoterol. After that, she visited our hospital because of fever of 39 °C and wet cough, and she was immediately hospitalized. Auscultation of the lungs showed wheezes and coarse crackles. On laboratory findings, white blood cell count increased to 12350/ μ L (neutrophil 83.1%, eosinophil 0.3%). The level of C reactive protein was elevated at 1.77 mg/dL. In chest CT taken on admission, infiltrative shadow in right lower lobe and centrilobular nodular shadow in left upper lobe accompanied by bronchial wall thickening and bronchiectasis were noted (Fig. 2A, B). Splenomegaly was also observed (Fig. 2C). Because she was positive for urine pneumococcal antigen, she was diagnosed with pneumococcal pneumonia. Ceftriaxone was given and her symptoms were promptly improved. Fractional expiratory nitric oxide (FeNO) level (13 ppb) was low, and there was no eosinophilia in sputum and blood. Because the diagnosis of her asthma was unlikely and treatment with ICS could increase the risk of infection, ICS was discontinued and she was then followed at our outpatient department.

One month after discharge, her pneumonia and wheezing reoccurred and she was emergently admitted. Because of recurrent upper and lower airway infection and poor response to vaccination,

immunodeficiency was strongly suspected. Then, all of immunoglobulin levels revealed to be markedly decreased (Table 1). Besides, nearly lack of memory B cells, NKT cells and plasmacytoid dendritic cells which play an important role in the defense against viral infection were also found from immunological analysis of peripheral lymphocyte by flow cytometry. Differential diagnosis was excluded from bone marrow examination, negative findings for immunodeficiency viruses and no use of immunosuppressive drugs, and she was finally diagnosed with CVID. After the diagnosis, antibiotic prophylaxis and immunoglobulin replacement therapy were initiated. Thereafter, wheezing episodes disappeared and the frequency and severity of airway infection were remarkably decreased, although the slight peripheral airway obstruction in lung function tests was not changed.

3. Discussion

The course of this patient provides two important clinical suggestions. This case had been treated with corticosteroid according to the diagnosis of bronchial asthma for a long time despite severe immunocompromised condition. First, a large majority of cases of CVID are diagnosed from childhood to 30-year-old. However, in this case, she was diagnosed at 51-year-old, which is abnormally older compared with usual cases. Second, CVID should be considered as differential diagnosis if immunodeficiency is suspected from clinical course. Wheezing is generally observed in obstructive conditions of the airways such as asthma, bronchiolitis, chronic obstructive pulmonary disease and pulmonary edema. This case was initially diagnosed with bronchial asthma, because bronchial wall thickening and bronchiectasis were supposed to be airway remodeling in difficult asthma. However, the lung function tests only showed slight peripheral airway obstruction. Therefore, the cause of wheezing episodes in our case may be associated with airway narrowing with sputum and airway inflammation derived from recurrent airway infection. Furthermore, this patient had very low IgE and low exhaled NO, which should have been a clue that the patient didn't have asthma. Maarschalk-Ellerbroek et al. [5] reported that significant pulmonary abnormalities in CVID were detected in over 50% consisting of airway abnormalities in 30% and intestinal lung disease in 34%. Lung involvement distributes to patient's mortality and morbidity for CVID [6,7]. So it is important to detect as soon as possible. Although CVID is descriptive term for a heterogeneous group of patients with a primary antibody deficiency syndrome, some cases show not only memory B cell dysfunction but also other immunodeficiency. Similarly in this case, the patient showed marked decreases in all classes of immunoglobulin and memory B cells, NKT cells, and plasmacytoid dendritic cells. Because it has recently been shown that both B cell and T cell dysfunction in CVID increases the risk of infection and prevalence of malignancy [8], this case needs an intensive follow-up.

Replacement immunoglobulin is the standard treatment for patients with CVID. Recommended target trough level of serum IgG is around 500–700 mg/dL in recent published guidelines and literature [9,10]. These data are not based on strong evidence and the doses of immunoglobulin should be selected individually to keep a patient free of bacterial infections. It is recommended for the cases with complication (i.e. splenomegaly or bronchiectasis) to keep higher trough level of IgG [11], and the level in this case was set as 500 mg/dL. After the immunoglobulin replacement therapy, the degree of frequency and severity of infection as well as wheezing episodes were decreased, but higher IgG level might be favorable in this case because of complication with splenomegaly and bronchiectasis.

Download English Version:

<https://daneshyari.com/en/article/4212608>

Download Persian Version:

<https://daneshyari.com/article/4212608>

[Daneshyari.com](https://daneshyari.com)