



## Case report

## A 22-year-old man with pleural tuberculosis associated hydropneumothorax: Case report and literature review

Lauren A. Sharan <sup>a</sup>, Thea P. Price <sup>b</sup>, Boyd Hehn <sup>c</sup>, David Manoff <sup>c</sup>, Scott W. Cowan <sup>d,\*</sup><sup>a</sup> Sidney Kimmel Medical College, Thomas Jefferson University, Philadelphia, PA, USA<sup>b</sup> Department of Surgery, Thomas Jefferson University, Philadelphia, PA, USA<sup>c</sup> Department of Medicine, Division of Pulmonary and Critical Care Medicine, Thomas Jefferson University, Philadelphia, PA, USA<sup>d</sup> Department of Surgery, Division of Thoracic Surgery, Thomas Jefferson University, Philadelphia, PA, USA

## ARTICLE INFO

## Article history:

Received 21 October 2015

Received in revised form

23 March 2016

Accepted 23 March 2016

## Keywords:

Tuberculosis

Pleural effusion

Pleural tuberculosis

Fibrinolytic therapy

## ABSTRACT

A 22-year-old Asian male presented with fever, non-productive cough, right-sided pleuritic chest pain and was found to have a large right hydropneumothorax. A chest tube was placed. Pleural fluid analysis revealed a lymphocytic predominant exudate and he was subsequently started on four-drug daily anti-tuberculosis therapy (isoniazid, ethambutol, rifampin, pyrazinamide). Pleural biopsy revealed acid-fast bacilli. Given his persistent pleural effusion, he was given four doses of intrapleural tissue plasminogen activator (tPA) and dornase alpha (DNase) via his chest tube over a period of 6 days resulting in clinical and radiologic improvement. Pleural biopsy and pleural fluid culture specimens later revealed *Mycobacterium tuberculosis*. Intrapleural tPA-DNase therapy has demonstrated improved resolution of infections and shortened hospitalizations for parapneumonic infectious effusions. However, there is little literature on the use of intrapleural fibrinolytics specifically for pleural tuberculosis associated effusions. Furthermore, the American Thoracic Society does not comment on therapeutic thoracentesis or intrapleural fibrinolytic therapy in their recommendations for treatment of pleural tuberculosis. In our case of pleural TB-associated hydropneumothorax, the use of intrapleural tPA-DNase therapy facilitated pleural fluid drainage and resulted in near-complete resolution of the effusion.

© 2016 The Authors. Published by Elsevier Ltd. This is an open access article under the CC BY-NC-ND license (<http://creativecommons.org/licenses/by-nc-nd/4.0/>).

## 1. Introduction

Pleural tuberculosis (TB) is rare. The most recent epidemiologic study in 2003 reported 14,874 US TB cases of which 20.4% were exclusively extra-pulmonary. Of these patients, 18.5% reported pleura as the major site of disease. From 1993 to 2003, pleural TB comprised only 3.9% of all US TB cases [1]. Globally there is significant geographical variation, for example the incidence in Spain is nearly six times that of the US [2].

Little published data exists about the management of pleural TB associated effusions. We report a case of an Asian male with a large hydropneumothorax found to have acid-fast bacilli (AFB) on pleural

biopsy and ultimately *Mycobacterium tuberculosis* in pleural biopsy and fluid cultures.

## 2. Case report

A 22 year-old Asian male smoker presented with ten days of non-productive cough, subjective fevers, night sweats, right-sided pleuritic chest pain and increasing dyspnea. One week prior to presentation, he was empirically treated for pneumonia with levofloxacin without improvement. The patient was an exchange student from China whose last visit home was two months prior to presentation to our facility. Both of the patient's parents had been diagnosed with TB before his birth with unclear treatment status.

The patient's physical exam was remarkable for decreased right-sided breath sounds. Vital signs were: temperature, 98.4 °F; heart rate, 102/min, regular; BP, 102/58 mm Hg; respiratory rate, 28/min; oxygen saturation, 95% on room air.

Chest radiograph (CXR) showed a large right hydropneumothorax and right upper lobe infiltrate with scarring (Fig. 1).

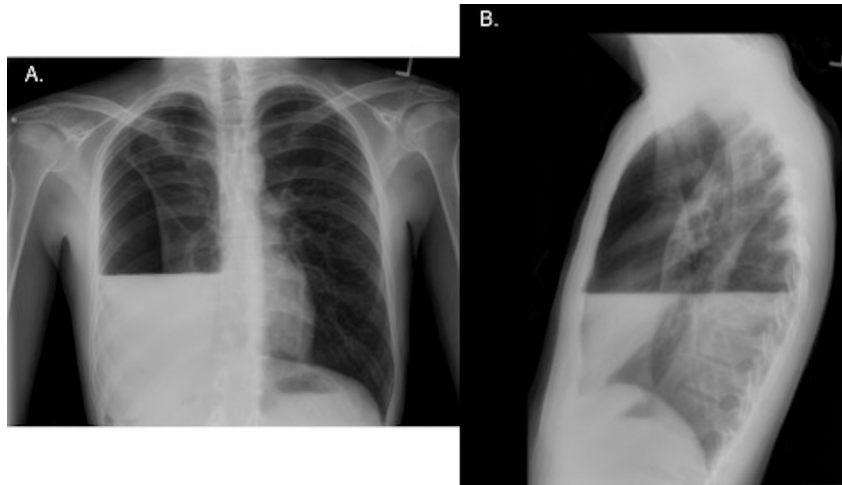
**Abbreviations:** TB, tuberculosis; CT, chest tube; AFB, acid fast bacilli; HD, hospital day; CXR, chest radiograph; ADA, adenosine deaminase; INH, isoniazid; EMB, ethambutol; RIF, rifampin; PZA, pyrazinamide.

\* Corresponding author. Thoracic Surgery, Thomas Jefferson University Hospital, 1025 Walnut Street, Suite 607, Philadelphia, PA 19107, USA.

E-mail address: [Scott.Cowan@jefferson.edu](mailto:Scott.Cowan@jefferson.edu) (S.W. Cowan).

<http://dx.doi.org/10.1016/j.rmcr.2016.03.010>

2213-0071/© 2016 The Authors. Published by Elsevier Ltd. This is an open access article under the CC BY-NC-ND license (<http://creativecommons.org/licenses/by-nc-nd/4.0/>).



**Fig. 1.** Initial chest radiographs of patient upon presentation. A, Posteroanterior view showing large right hydropneumothorax. B, Lateral view showing hydropneumothorax.

A right-sided 32 French chest tube (CT) was placed in the emergency department (Fig. 2A). A chest computed tomography scan showed tree-in-bud nodularity in the right upper lobe, possible consolidation in the right lower lobe and calcified hilar lymphadenopathy. Additionally, there were foci of gas in the right-sided hydropneumothorax which could have represented a loculated component. Due to imaging findings suggesting prior granulomatous infection and patient history, there was high suspicion for TB and on airborne precautions were instituted.

A pleural drainage catheter was placed into the hydro-pneumothorax. Analysis of the pleural fluid obtained from this procedure revealed: pH, 7.70; glucose, 11 mg/dL; protein, 4.5 g/L; LDH, 1458 units/L; WBC, 1340 cells/ $\mu$ L (64% lymphocytes); RBC, 4000 cells/ $\mu$ L; adenosine deaminase (ADA), 57.5 units/L. Additionally, serum protein was 5.6 g/L.

Throughout his hospitalization, the patient had multiple AFB smears and cultures performed (2 concentrated sputum, 2 pleural fluid, 1 bronchoalveolar lavage), which were negative. A pleural biopsy demonstrated 1+ AFB on smear and necrotizing granulomatous inflammation. The patient was started on an anti-tuberculosis regimen (isoniazid (INH) 300 mg, ethambutol (EMB) 800 mg, rifampin (RIF) 450 mg and pyrazinamide (PZA) 1000 mg) because of his findings of a lymphocyte predominant exudative pleural effusion, AFB positive pleural biopsy with necrotizing granulomatous inflammation and history of exposure to TB.

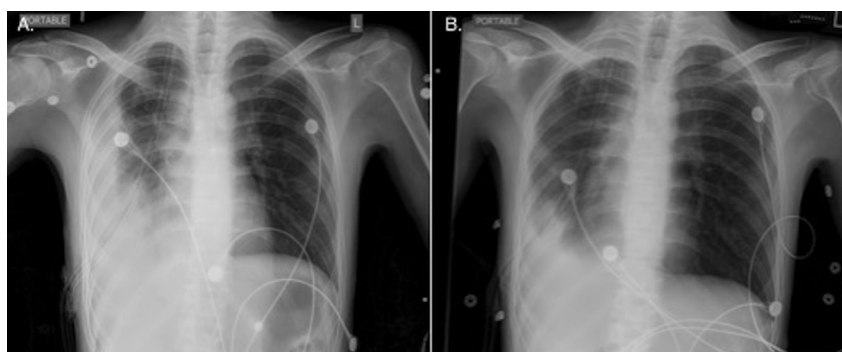
Given the persistent pleural effusion, he was given four doses of tissue plasminogen activator (tPA) and dornase alfa (DNase) instilled via the chest tube over a period of 6 days resulting in

improved drainage and clinical and radiologic improvement (Table 1, Fig. 2B). Fibrinolytic therapy was terminated at the point of near complete resolution of the pleural effusion as evidenced by CXR. The chest tube was removed and the patient was discharged on hospital day 13. Two weeks after discharge, a follow-up CXR demonstrated a persistent small right-sided effusion, however; the patient was asymptomatic (Fig. 3). Ultimately, the pleural fluid and biopsy cultures were positive for *Mycobacterium tuberculosis*.

### 3. Discussion

Tuberculous pleuritis should be considered in patients with a lymphocyte-predominant exudative effusion. The etiology of an effusion can be difficult to classify and often requires both pleural fluid analysis and clinical correlation [3]. Our patient had a pleural fluid protein/serum protein ratio of 0.80 and elevated pleural fluid LDH indicating an exudate. Low pleural fluid glucose (40 mg/dL) narrowed our differential to rheumatoid pleurisy, empyema, malignancy, lupus pleuritis or tuberculous pleurisy [4]. In this patient, serum protein >4 g/dL made tuberculous pleural effusion more likely [5]. Our patient's pleural fluid did not show the typical pH of <7.30 as seen in most tuberculous effusions [6]. In one meta-analysis, the average pH for tuberculous effusions was 7.18 [7]. The pleural fluid ADA value was found to be elevated at 57.5 U/L. The ADA assay has a sensitivity of 92% and a specificity of 90 for diagnosing TB pleurisy [8].

The best diagnostic approach to suspected tuberculous pleuritis is debated. The yield of pleural fluid smears is 10% and of pleural



**Fig. 2.** Chest radiographs showing resolution of the hydropneumothorax. A, Following chest tube placement. B, Day 4 after chest tube placement.

Download English Version:

<https://daneshyari.com/en/article/4212658>

Download Persian Version:

<https://daneshyari.com/article/4212658>

[Daneshyari.com](https://daneshyari.com)