



Case report

Minocycline-induced acute eosinophilic pneumonia: A case report and review of the literature[☆]

Sharon W. Hung

Department of General Internal Medicine, University of Arizona Medical Center, Tucson, AZ, USA

ARTICLE INFO

Article history:

Received 10 March 2015
 Received in revised form
 17 May 2015
 Accepted 20 May 2015

Presented at Society of General Internal
 Medicine, California–Hawaii regional
 meeting January 31, 2014; Stanford Univer-
 sity in Palo Alto, CA, USA.

Keywords:

Acute eosinophilic pneumonia
 Pulmonary eosinophilia
 Corticosteroids
 Minocycline
 Tetracycline

ABSTRACT

Acute eosinophilic pneumonia (AEP) can be a challenging diagnosis and is often initially misdiagnosed as one of the more common pneumonia syndromes such as acute respiratory distress syndrome. Early bronchoalveolar lavage (BAL) is critical in distinguishing the diagnosis to initiate proper management. The etiology of AEP is unknown, though many drugs have been implicated, including minocycline.

Minocycline is commonly used for pneumonia, acute bronchitis, urinary tract infections, and acne and is likely the cause of AEP in our patient. There are 26 case reports of minocycline-induced AEP. In most cases, outcomes were favorable and symptoms rapidly resolved upon discontinuation of minocycline, with 11 cases employing steroids, one case twelve hours of CPAP and another 5 days of intubation. None resulted in mortality. Although it is difficult to evaluate without further studies, steroids should be recommended for minocycline-induced AEP, especially for those with severe or persistent symptoms.

© 2015 The Author. Published by Elsevier Ltd. This is an open access article under the CC BY-NC-ND license (<http://creativecommons.org/licenses/by-nc-nd/4.0/>).

1. Introduction

Acute eosinophilic pneumonia (AEP) can be a challenging diagnosis and is often initially misdiagnosed as one of the more common pneumonia syndromes. Early bronchoalveolar lavage (BAL) is critical in establishing a diagnosis to initiate proper management. There have been numerous drugs implicated in the development of AEP. Twenty-six have been reported in the English literature. We describe a case consistent with minocycline-induced eosinophilic pneumonia.

2. Case summary

An 87-year-old male initially presented to the emergency department with right hand cellulitis after being bitten by his pet dog. Past history included coronary artery disease, TIA, hypertension, hyperlipidemia, osteoporosis, and glaucoma. He previously smoked a few cigarettes per day but quit 60 years ago. He denied any other illicit drug use. One dose of intravenous ampicillin/

sulbactam was administered in the emergency department. The wound was thoroughly washed. The patient was then discharged to complete a course of oral amoxicillin/clavulanate. Three days later he was seen in orthopedic clinic for follow up. Continued significant erythema, edema, and warmth of the wound and hand were noted prompting hospitalization. Three days of intravenous ampicillin/sulbactam and vancomycin were administered with improvement. He was discharged to complete a 10 day course of oral amoxicillin 875 mg/clavulanate and minocycline. Twelve days after discharge he presented again to the emergency room for ankle pain after a misstep. He also described 10–15 loose, non-bloody bowel movements in the 24 h prior to admission. History was otherwise unremarkable.

Vitals revealed a fever to 102.7 F, hypotension to 90/62, tachycardia at 108 beats per minute, tachypnea to 22 breaths per minute and an oxygen saturation of 87% while breathing ambient air. On evaluation he was breathing and speaking comfortably. Faint crackles were auscultated. A 3/6 systolic murmur loudest at the apex and a flat JVP were noted. His hand exhibited mild erythema and an eschar on the dorsal hand without excessive warmth. There was mild left ankle warmth and edema. Laboratory studies reflected a leukocytosis to 20.8 k/uL with 74% neutrophils, 20% lymphocytes, and 2.8% eosinophils. Creatinine was slightly elevated at

[☆] Performed at West Los Angeles Veterans Medical Center.
 E-mail address: shung@deptofmed.arizona.edu.

1.38 mg/dL with normal liver enzymes. A chest radiograph demonstrated small bilateral effusions and vague bilateral upper lobe lung infiltrates (*Image 1*). He was diagnosed with an ankle sprain but was hospitalized for severe sepsis, pneumonia and acute kidney injury. Intravenous ertapenem, vancomycin, and azithromycin given recent antimicrobial use in addition to oral metronidazole for possible *C. difficile* colitis.

Worsening tachypnea and hypoxia developed on hospital day 2 in addition to ongoing fevers. Supplemental oxygen at 4 L per minute via nasal cannula was required to maintain oxygen saturation in the low 90s. A complete blood count with differential was obtained demonstrating a new eosinophilia to 22.8% with ongoing leukocytosis at 17.3 k/uL. Repeat chest film revealed interval worsening of a diffuse alveolar filling pattern concerning for acute respiratory distress syndrome. Small bilateral pleural effusions persisted. Computed tomography of the chest revealed diffuse bilateral airspace disease with ground glass attenuation involving all lobes along with moderate bilateral pleural effusions (*Images 2 and 3*).

The trachea was intubated to permit flexible fiberoptic bronchoscopy given the degree of compromise in hypoxemia and respiratory mechanics. BAL and transbronchial biopsies were obtained from the right side. A trial of liberation from mechanical ventilation immediately post procedure failed. The patient was reintubated, and mechanical ventilatory support was initiated. By the next morning an FiO₂ of 0.80 was required to maintain saturations in the low nineties. A pneumothorax developed in the right hemithorax and a chest tube was placed. Initial blood cultures identified streptococcus parasanguinus in 2 out of 2 specimens. Urine culture grew >100 K colony forming units of *Klebsiella*. *C. difficile* toxin returned negative without further diarrhea. Urine legionella antigen and coccidioides IgG and IgM returned negative. Antimicrobials were tailored to ampicillin/sulbactam and ciprofloxacin.

Analysis of the BAL sample revealed 515 nucleated cells per microliter, of which 6% were neutrophils, 5% lymphocytes, and 15% eosinophils. Transbronchial biopsies demonstrated marked eosinophilia in both the alveolar and interstitial spaces. Bacterial, fungal, mycobacterial and viral stains and cultures were negative. Methylprednisolone was started at 125 mg every 6 h.

The following morning leukocytosis decreased to 13.5 k/uL with a precipitous drop in eosinophilia to 8.3%. By hospital day six the patient had defervesced with marked improvement in gas exchange. He was successfully liberated from mechanical ventilation

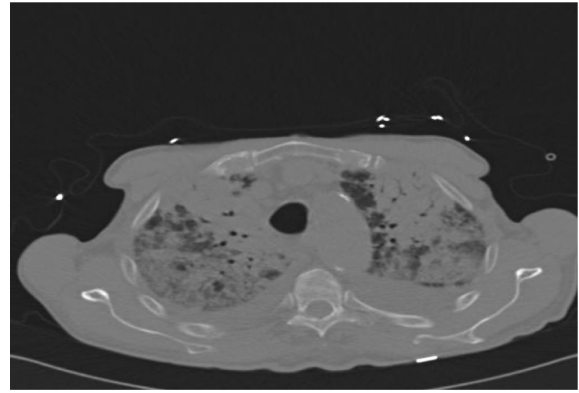


Image 2. Computed tomography of the chest revealed diffuse bilateral airspace disease with ground glass attenuation involving all lobes along with moderate bilateral pleural effusions.

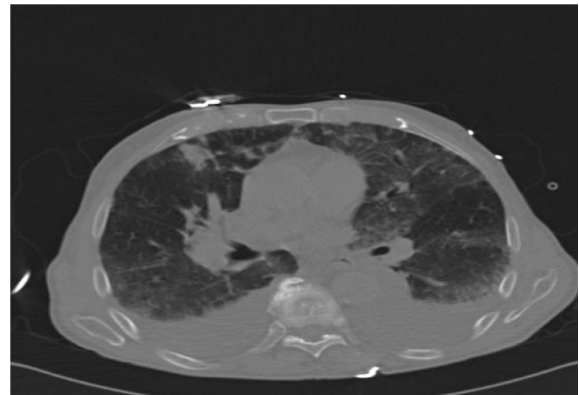


Image 3. Computed tomography of the chest revealed diffuse bilateral airspace disease with ground glass attenuation involving all lobes along with moderate bilateral pleural effusions.

with supplemental oxygen requirements improving to 3 L per minute via nasal cannula. There was normalization of eosinophilia to 0.1% with marked improvement in air space disease on imaging (*Image 4*). Solumedrol was transitioned to oral prednisone of 60 mg daily. Ciprofloxacin was discontinued as *Klebsiella* in the urine was determined to be a contaminant, given urinalysis was negative for

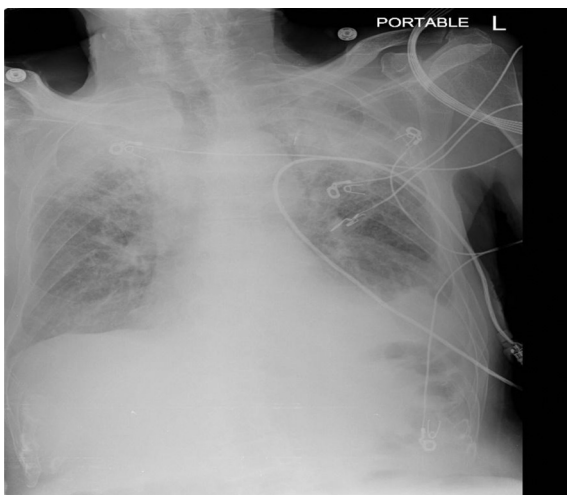


Image 1. Admission Chest Radiograph demonstrated small bilateral effusions and bilateral upper lobe lung infiltrates.

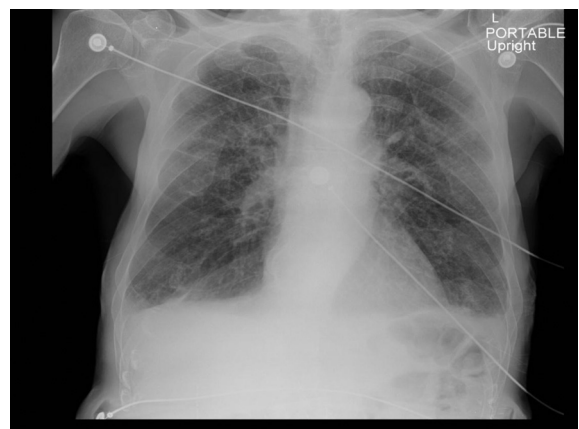


Image 4. Three weeks after oral steroid therapy, marked resolution of bilateral infiltrates and improvement of bilateral effusions are seen.

Download English Version:

<https://daneshyari.com/en/article/4212712>

Download Persian Version:

<https://daneshyari.com/article/4212712>

[Daneshyari.com](https://daneshyari.com)