Clinical Imaging 40 (2016) 732–738

Contents lists available at ScienceDirect

Clinical Imaging

journal homepage: http://www.clinicalimaging.org

Original Article

Assessment of severity of leukoaraiosis: a diffusional kurtosis imaging study☆

Shuhui Xu [a], Deqiu Ye [a], Tao Lian [a], Jianzhong Cai [b], Zebin Xiao [c], Yongchu Huang [a], Xiangrong Chen [a,*], Zhongping Zhang [d]

[a] Department of Radiology, Quanzhou First Hospital Affiliated to Fujian Medical University, Quanzhou, Fujian 362000, China
[b] Department of Radiology, Shishi City Hospital, Quanzhou, Fujian 362700, China
[c] Department of Radiology, First Affiliated Hospital of Fujian Medical University, Fuzhou, Fujian, 350005, China
[d] GE Healthcare China, Guangzhou 510623, China

ARTICLE INFO

Article history:
Received 14 May 2015
Received in revised form 31 January 2016
Accepted 19 February 2016

Keywords:
Diffusion
Kurtosis
DKI
Non-Gaussians
Leukoaraiosis

ABSTRACT

Objective: The objective was to investigate the capabilities of diffusional kurtosis imaging (DKI) in detection of age-related white matter (WM) changes in elderly patients with leukoaraiosis.
Material and methods: Fractional anisotropy (FA), kurtosis, and diffusion parameters in the frontal lobe and parietal lobe were compared between 14 patients at Fazekas scale 0 and 1, and 15 patients at Fazekas scale 2 and 3.
Results: FA and DKI parameters were significantly altered in the ischemic lesions vs normal regions of WM in the severe patients.
Conclusion: DKI can provide sensitive imaging biomarkers for assessing the severity of leukoaraiosis in reference to Fazekas score.

1. Introduction

Abnormal supratentorial white matter hyperintensities (WMHs) on T2-weighted magnetic resonance imaging (MRI) sequences are prevalent in the elderly population. Such changes, also referred to as leukoaraiosis, appear hyperintense in the WM on T2-weighted MRI sequences in patients with mild to severe grade [1]. Functional decline in elderly people such as cognitive impairment, depression, difficulties in walking, and urinary incontinence has been consistently reported to be associated with severe WM changes in leukoaraiosis [2]. However, pathological processes of leukoaraiosis involved in the transition from independent functional status to more substantial disability have not yet been fully elucidated. Advances in modern diagnostic techniques including brain imaging might help identify these processes [2].

Magnetic resonance diffusion tensor imaging (DTI) has been shown to provide unique structural information in characterizing tissue microstructure [3,4], which cannot be readily achieved by other noninvasive modalities. Although the orientational neuroarchitecture can be inferred from DTI, the heterogeneity within a voxel is often difficult to resolve [5]. For example, crossing or diverging WM fibers can appear to be isotropic, and DTI may fail to adequately probe these structures. Furthermore, the gray matter is relatively isotropic, and DTI is not effective enough to characterize water diffusion changes in this area. Based on the fact that neuronal tissues are known to be heterogeneous in nature and composed of multiple compartments [6], kurtosis, the fourth central moment of a distribution, has been introduced to indicate a more restricted diffusion environment. Indeed, diffusion kurtosis imaging (DKI) has so far been used to characterize such non-Gaussian water diffusion behaviors in neural tissues and appears to offer an improved sensitivity in detecting microstructural changes of neural tissues in certain developmental and pathological states as compared with the conventional DTI [7–9].

There have been no reports in the literature aimed at assessing the severity of leukoaraiosis by DKI in reference to Fazekas score. In this study, we evaluated whether directional kurtosis analysis of WM in the frontal lobe could define leukoaraiosis and its severity in elderly patients.

☆ Conflicts of interest: None.

* Corresponding author. Department of Radiology, Quanzhou First Hospital Affiliated to Fujian Medical University, Quanzhou, Fujian 362000, China. Tel.: +86 595 22277011; fax: +86 595 22277031.
E-mail address: 2310611338@qq.com (X. Chen).

http://dx.doi.org/10.1016/j.clinimag.2016.02.018
0899-7071/

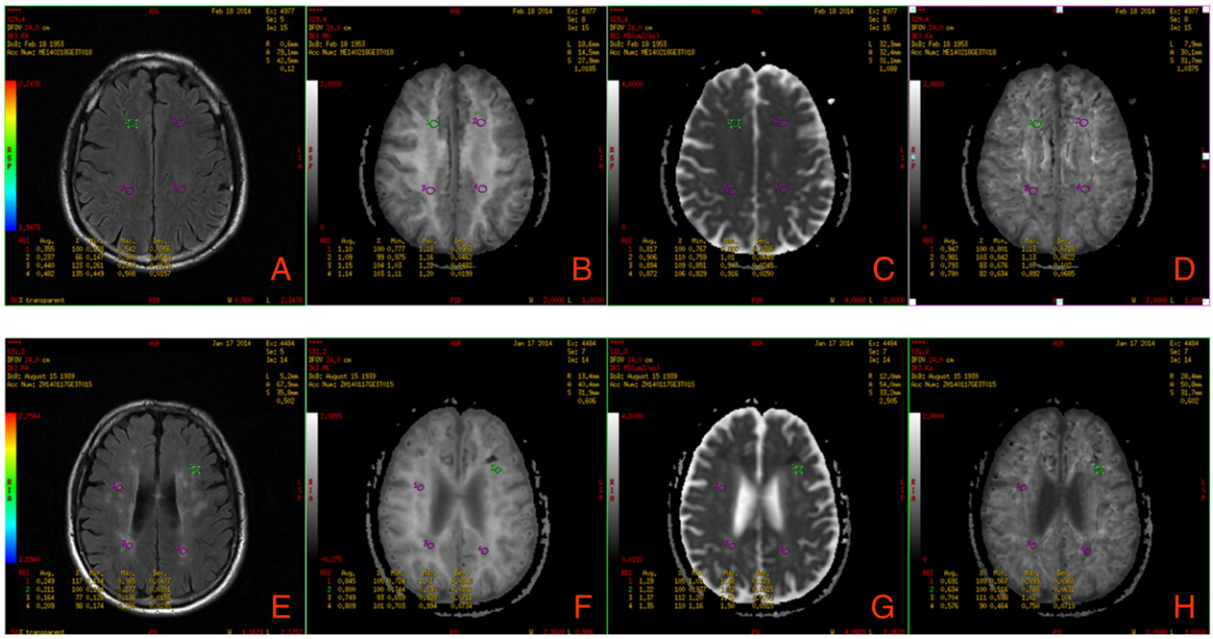

Fig. 1. Representative images of the frontal and parietal lobe ROIs defined on T2FLAIR axial slices (A) and DKI axial slices (B, C, D) from mild patients, and T2FLAIR axial slices (E) and DKI axial slices (F, G, H) from severe patients.

2. Materials and methods

This study was approved by our institutional review board, with waiver of informed consent.

2.1. Study subjects

We performed a retrospective review of clinical and imaging data on elderly patients aged between 70 and 80 years who complained of mild memory or motor problems, minor mood alterations, or other minor neurological problems. Those problems did not interfere with their daily life activities, but the patients were found to have age-related WM changes of any degree on brain MRI. Twenty-nine patients were selected and categorized into two groups based on the Fazekas scale [10]: mild group (Fazekas scale 0 and 1, 75.8 ± 3.4 years, $n = 14$) and severe group (Fazekas scale 2 and 3, 76.2 ± 2.8 years, $n = 15$). Cognitive function of all selected patients was assessed using the Mini-Mental Status Examination (MMSE). All subjects had no history of stroke, past head injury, and other types of mental disorders that may potentially affect the central nervous system.

2.2. MR imaging

Images were acquired using a 3.0-T MR scanner (GE Signa EXCITE HD, Milwaukee, WI, USA) equipped with an eight-channel head phased array coil. The conventional MRI protocol consisted of axial T2-weighted fluid-attenuated inversion recovery {T2FLAIR; 8425/165/2100 ms [repetition time (TR)/echo time (TE)/inversion time]}, axial fast spin-echo T2-weighted imaging (6000/96 ms), and axial and sagittal nonenhanced and three-plane enhanced gradient-echo T1-weighted imaging (250/2.48 ms). It was uniform in all series about field of view (FOV; 240 × 240 mm), section thickness (6 mm), and intersection gap (1.0 mm). DKI images were acquired with three b-values ($b = 0$, 1000, and 2000 s/mm^2) along 25 directions for each nonzero b value using a pulsed-gradient spin echo sequence with echo-planar imaging readout. Other imaging parameters were as follows: 40 oblique axial slices to cover the frontal and parietal regions, slice thickness = 3 mm, TR/TE = 2300/108 ms, FOV = 240 × 240 mm, matrix = 80 × 80 mm, number of excitation = 2, with scan time of 8 min and 34 s.

2.3. Data processing

Acquired images were transferred to an off-line workstation (GE Advantage Workstation 4.4) for processing. Before DKI quantification, image coregistration and smoothing were performed using automated image registration software 5.3.0 (http://bishopw.loni.ucla.edu/air5/) [11]. All DWIs were first coregistered to the b_0 image using the affine model. Then, registered DWIs with b values of 1000 and 2000 s/mm^2 were averaged over 25 diffusion-encoding directions. Afterwards, the two averaged DWIs were coregistered to the b_0 image using the affine model, and the registered averaged DWIs were set as a reference volume for further registrations. Finally, the initial DWIs with b values of

Table 1
Comparison of the MMSE score between the mild and severe patients using t test

Groups	n	Age	MMSE score
MK	14	75.8 ± 3.4	17.86 ± 6.45
FA	15	76.2 ± 2.8	18.67 ± 5.88

Table 2
Comparison of diffusion and kurtosis parameters between the frontal WM of mild patients and the N-A WM of severe patients using Mann–Whitney U test

DKI parameters	WM of mild patients	N-A WM of severe patients	U value	P value
MK	0.98 ± 0.06	0.90 ± 0.09	54	.026
MD	0.924 ± 0.05	1.005 ± 0.063	35	.020
Ka	0.86 ± 0.08	0.79 ± 0.06	52	.021
Kr	1.08 ± 0.08	0.98 ± 0.02	50	.016
Da	1.17 ± 0.05	1.25 ± 0.07	45	.010
Dr	0.80 ± 0.05	0.88 ± 0.06	34	.002
FA	0.27 ± 0.04	0.23 ± 0.02	49	.015