

## CASE REPORT

# Brucella osteomyelitis of the pubic bones



Pascale Aouad <sup>a</sup>, Ali Serhal <sup>a,\*</sup>, Leila Bleibel <sup>b</sup>, Mohamad Haidar <sup>c</sup>,  
Assaad Mohanna <sup>b</sup>

<sup>a</sup> Department of Radiology, Lebanese University, Rafic Hariri University Campus, Beirut, Hadath, Lebanon

<sup>b</sup> Department of Radiology, Bahman Hospital, Daccache Street, Haret Hreik (Baabda), Lebanon

<sup>c</sup> Department of Diagnostic Radiology and Nuclear Medicine, American University of Beirut Medical Center, Beirut, Lebanon

Received 24 April 2015; accepted 16 November 2015

Available online 23 December 2015

### KEYWORDS

Brucella;  
Pubic symphysis;  
Arthritis infectious;  
Osteomyelitis

**Abstract** Brucellosis is a worldwide zoonotic disease that represents a serious public health problem in developing countries. Clinical manifestations are diverse and can affect any organ or body system. Osteoarticular disease is the most common localized form and has been reported in up to 80%. Pubic osteomyelitis is a very rare localization for Brucella infection and only 4 cases have been previously published. The clinical manifestations, laboratory and radiologic findings are non-specific. High index of suspicion is required to make an early diagnosis. Herein we report a case of Brucella osteomyelitis of the symphysis pubis with its radiologic features.

© 2015 The Egyptian Society of Radiology and Nuclear Medicine. Production and hosting by Elsevier B.V. This is an open access article under the CC BY-NC-ND license (<http://creativecommons.org/licenses/by-nc-nd/4.0/>).

## 1. Introduction

Brucellosis is a zoonotic infection that is transmissible to humans resulting in diverse and non-specific clinical manifestations (1,2). The disease can be acute or chronic and localized or diffused (2). The musculoskeletal system represents the most

*Abbreviations:* CRP, C reactive protein; CT, computed tomography; ESR, erythrocyte sedimentation rate; MRI, magnetic resonance imaging; PPD, purified protein derivative; T1WI, T1 weighted images; T2WI, T2 weighted images; WBC, white blood cell; WHO, World Health Organization

\* Corresponding author at: Daraya, El Shouf, Main Street, Serhal Building, Lebanon. Tel.: +961 70955301.

E-mail addresses: [pascale\\_aouad@hotmail.com](mailto:pascale_aouad@hotmail.com) (P. Aouad), [al\\_serhal@hotmail.com](mailto:al_serhal@hotmail.com) (A. Serhal), [leilableibel@yahoo.fr](mailto:leilableibel@yahoo.fr) (L. Bleibel), [drmbhaidar@gmail.com](mailto:drmbhaidar@gmail.com) (M. Haidar), [assaadmohanna@hotmail.com](mailto:assaadmohanna@hotmail.com) (A. Mohanna).

Peer review under responsibility of Egyptian Society of Radiology and Nuclear Medicine.

<http://dx.doi.org/10.1016/j.ejrnmm.2015.11.009>

0378-603X © 2015 The Egyptian Society of Radiology and Nuclear Medicine. Production and hosting by Elsevier B.V.

This is an open access article under the CC BY-NC-ND license (<http://creativecommons.org/licenses/by-nc-nd/4.0/>).

common organ system involved in the localized form (1,3). Osteoarticular localization can present as spondylitis, arthritis, osteomyelitis and myositis (1,4).

Arthritis of symphysis pubis or pubic osteomyelitis is very rare in Brucellosis with only 4 previously reported cases. Osteomyelitis pubis caused by other pathogens and osteitis pubis, an inflammatory aseptic condition, can mimic Brucella osteomyelitis pubis (1). Therefore high index of suspicion is needed to reach the diagnosis. Serologic tests, blood cultures and culture of needle aspirate from the symphysis pubis are necessary to make a definite diagnosis.

## 2. Case presentation

A 72-year-old female presented for progressive pelvic pain irradiating to both groins and difficult ambulation over the last 6 months. She was also complaining of night sweats and

weight loss. She has been seen by several physicians and received symptomatic treatments with no improvement and no previous medical problems. The physical examination was unremarkable. Laboratory tests revealed mild leukocytosis (white blood cell [WBC] count of  $14,000/\text{mm}^3$ ) and mildly raised erythrocyte sedimentation rate (ESR 43 in 1st hour). Chest X-ray and abdominal ultrasound were normal.

Magnetic resonance imaging (MRI) of the lumbar spine demonstrated mild degenerative disk changes with no evidence of nerve compression. MRI of the pelvis demonstrated low signal on T1 weighted images (T1WI) at the iliopubic rami, subchondral marrow of the symphysis pubis and to a lesser extent on the ischiopubic rami bilaterally (Fig. 1a). There is corresponding high signal on T2 weighted images (T2WI) and enhancement after administration of Gadolinium. There was associated irregularity of the articular surfaces and a 2 cm ring enhancing collection in the joint space at the symphysis pubis (Figs. 1b and 2). These findings raised suspicion for infectious arthritis or pubic osteomyelitis.

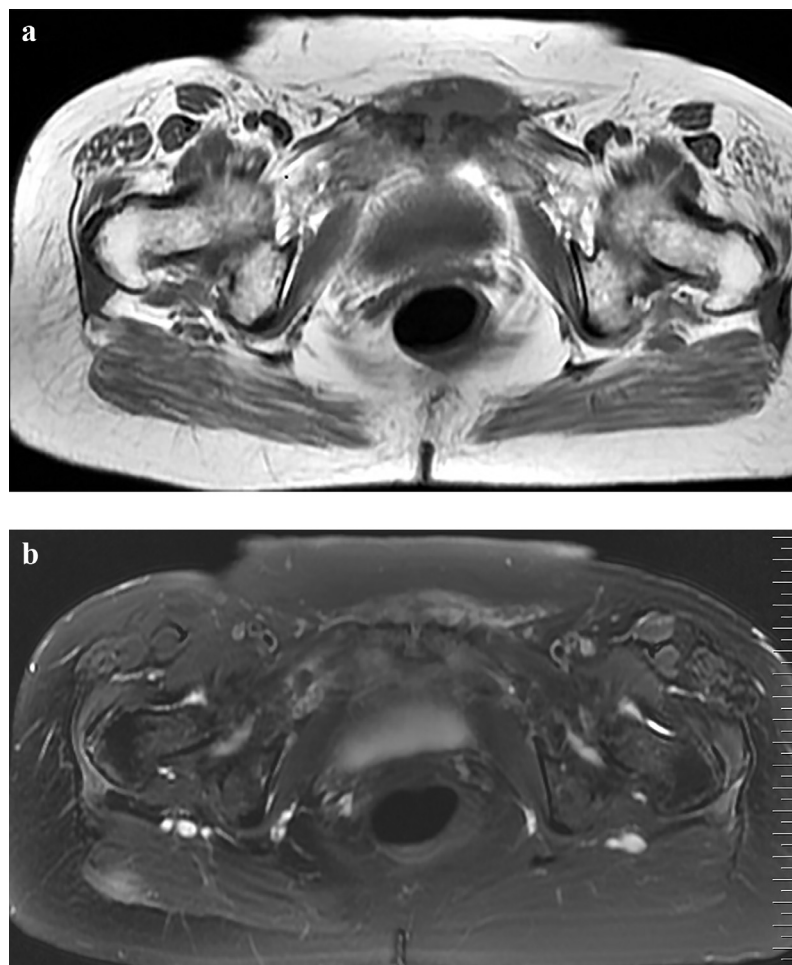
Fine needle aspiration of the collection was done. Cultures of the specimen and mycobacterial identification were negative. The purified protein derivative (PPD) test was negative. Serologic tests for Brucella titers were positive ( $>1/640$ ) for *Brucella melitensis* and *Brucella abortus*. The diagnosis of Bru-

cella osteomyelitis of the pubic bones was done. A more detailed history revealed previous intake of raw meat. The patient received streptomycin for 2 weeks and doxycycline for 3 months. After 3 months of treatment she was free of symptoms and her Brucella titer dropped significantly.

### 3. Discussion

Brucella is a zoonotic infection caused by Gram negative aerobic coccobacilli (1,2). Transmission to humans occurs usually through consumption of unpasteurized dairy products and less often through inhalation of infected aerosols or contamination of skin abrasions (1,2). The clinical presentation is variable and non-specific. Brucellosis can manifest as acute or chronic disease and may be associated with localized complications at any stage (2).

Any organ system can be involved and the most common localization is the osteoarticular system in active brucellosis (1,3). The frequency of skeletal involvement varies from 10% to 80% (1). A study conducted by Al-Shahed et al. on 224 patients with systemic brucellosis and radiologic evidence of osteoarticular involvement showed that 52.7% of patients had spinal disease, 36.2% had extraspinal involvement and 11.1% had both spinal and extra-spinal lesions (4). Arthritis,



**Fig. 1** (a, b) Axial T1-weighted image (TR/TE, 500/16.5) (a) reveals low signal intensity at the subchondral marrow of the symphysis pubis, along the ischiopubic rami bilaterally and within the joint space. Axial T2-weighted image (TR/TE, 2200/81.6) with fat suppression (b) shows high signal intensity along the ischiopubic rami, within the symphysis pubis joint and extending to the soft tissues anteriorly.

Download English Version:

<https://daneshyari.com/en/article/4224227>

Download Persian Version:

<https://daneshyari.com/article/4224227>

[Daneshyari.com](https://daneshyari.com)