Use of Magnetic Resonance in the Evaluation of Cranial Trauma

Wilson Altmeyer, MD[a,*], Andrew Steven, MD[b], Juan Gutierrez, MD[c]

KEYWORDS

• Cranial trauma • Diffuse axonal injury • Contusion • Hematoma • MR imaging

KEY POINTS

- MR imaging is commonly performed as an adjunct imaging modality after initial trauma evaluation with CT.
- MR imaging is the most sensitive imaging modality for diagnosis of diffuse axonal injury (DAI), parenchymal contusion, and traumatic cerebral infarction.
- MR imaging is just as sensitive as CT for the detection of acute subarachnoid hemorrhage (SAH) and is more sensitive in detection of subacute to chronic SAH.
- Magnetic resonance angiography (MRA) is a useful tool for interrogating the intracranial vasculature in children, pregnant patients, and patients with renal insufficiency or acute kidney injury.

INTRODUCTION

Approximately 1.7 million Americans present to emergency departments (EDs) each year with head trauma.[1] Of these patients, 52,000 die and 275,000 require hospitalization. Traumatic brain injury (TBI) is a contributing factor in one-third of all traumatic deaths in the United States, with motor vehicle accidents comprising the leading cause of TBI-related mortality.[1]

CT traditionally serves as the initial imaging modality of choice in the evaluation of TBI secondary to its widespread availability, speed, cost, and sensitivity for both acute intracranial hemorrhage and fractures. There has been a steady increase, however, in the use of MR imaging by EDs over the past decade.[2–4] Factors contributing to the increased rate of MR imaging use include improved availability, reduced cost, faster acquisition times, and lack of ionizing radiation.[3] MR imaging also offers improved soft tissue contrast with increased sensitivity for detection for a wide variety of traumatic pathologies, such as DAI and cerebral contusions.[5,6] This increased sensitivity for TBI is particularly useful in the setting of mild head trauma where initial imaging CT may be negative[7] (**Fig. 1**).

The brain and spine are the most common anatomic locations to be imaged with MR imaging by the ED. The most common indications for emergent MR imaging of the brain are stroke, headache, and trauma.[3,8] This article provides a succinct review of the MR imaging appearance of the common traumatic intracranial pathologies that are encountered in an ED setting.

INTRA-AXIAL TRAUMA

Contusions

Cerebral contusions are parenchymal bruises that occur when the brain has an impact on the surface

The authors have nothing to disclose.

[a] Department of Radiology, University of Texas Health Science Center at San Antonio, 7703 Floyd Curl Drive, San Antonio, TX 78229-3900, USA; [b] Department of Radiology, University of Maryland Medical System, 22 South Green Street, Baltimore, MD 21201, USA; [c] Centro Avanzado de Diagnóstico Médico CEDIMED, Calle 18 AA sur # 29 c 340, Medellín, Colombia

* Corresponding author.

E-mail address: altmeyer@uthscsa.edu

Magn Reson Imaging Clin N Am 24 (2016) 305–323

http://dx.doi.org/10.1016/j.mric.2015.11.011

1064-9689/16/$ – see front matter © 2016 Elsevier Inc. All rights reserved.

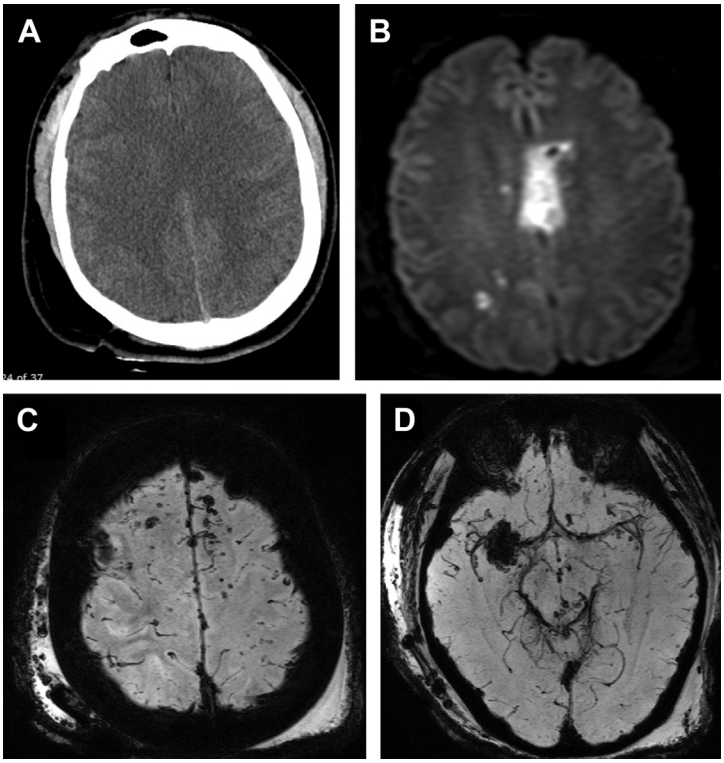

Fig. 1. (*A*) Axial noncontrast CT fails to reveal TBI after motor vehicle collision. MR imaging clearly depicts restricted diffusion in the (*B*) body of the corpus callosum, (*C*) small foci of hemorrhage at the frontal gray-white junction, and (*D*) punctate midbrain hemorrhages on axial SWI sequences, consistent with the final diagnosis of DAI.

of the skull, falx cerebri, or tentorium. Blunt, closed head injury is the most frequent cause of brain contusions. The inferior frontal and anterior temporal lobes are the most common locations for cerebral contusion because the adjacent anterior and middle cranial fossae of the skull base have a relatively sharp, irregular contour.[9] The occipital lobes are almost always spared from contusion because the bordering occipital bone exhibits a smooth inner table. A contusion at the site of trauma is referred to as a *coup contusion*. When the contusion is 180° opposite the site of direct impact, the contusion is termed, *contrecoup* (Fig. 2). Contusion may be difficult to visualize on initial CT examination in an ED. Contusions, however, have a tendency to enlarge and become more apparent on follow-up imaging.

Contusion by definition must involve the cortical surface of the brain, a feature that helps differentiate from subcortical DAI. The imaging appearance of cerebral contusion may vary from subtle petechial hemorrhage to multiple large parenchymal hematomas with severe mass effect. A CT examination classically demonstrates foci of hyperattenuating hemorrhage within a wedge-shaped region of hypodense cerebral edema. MR imaging is more sensitive than CT for the detection of cerebral contusion.[6,7,10] The fluid-attenuated inversion recovery (FLAIR) sequence is superior to T1-weighted and T2-weighted sequences for detection of cerebral edema in the setting of a brain contusion (Fig. 3). The appearance of hemorrhagic contusions change on T1-weighted and T2-weighted sequences along a predictable pattern based on the age of blood products (Table 1). Hemorrhagic contusions often contain blood products in various stages of degradation within the hematoma, with the evolution progressing in a centripetal fashion. Subacute blood products are one of only a few pathologic processes that are hyperintense on T1-weighted sequences.

Gradient-recalled echo (GRE) and susceptibility-weighted images (SWIs) are the most sensitive sequences for detection of hemorrhagic contusion. Hemorrhage appears as black "blooming" artifact on these sequences. There is growing evidence in the literature confirming SWI's superiority to GRE for the detection of intracranial hemorrhage.[11–13] Foci of DWI hyperintensity within a cerebral contusion may reflect either blood products or regions of cytotoxic edema and neuronal death.[9]

Penetrating Injury

Penetrating injuries are characterized by a projectile piercing the skull, dura, and brain. The

Download English Version:

https://daneshyari.com/en/article/4242496

Download Persian Version:

https://daneshyari.com/article/4242496

Daneshyari.com