



ELSEVIER

Available online at www.sciencedirect.com

ScienceDirect

journal homepage: <http://Elsevier.com/locate/radcr>

Case Report

Childhood giant omental and mesenteric lipoma

Hidayatullah Hamidi MD^{a,*}, Najibullah Rasouly MD, MS^a,
 Hayatullah Khpalwak MD, MS^b, Mohammad Omer Malikzai MD^c,
 Ahmad Reshad Faizi MBBS^a, Mer Mahmood Shah Hoshang MD^a, Sahar Maroof MD^a,
 Mohammad Nawaz Nasery MD^a, Farhad Farzam MD^a, Mohibullah Salehzai MD^a,
 Jamshid Sadiqi MD, MS^a

^a Radiology Department, French Medical Institute for Children (FMIC), Kabul 1006, Afghanistan

^b Surgery Department, Indira Gandhi Institute of Child Health (IGICH), Kabul, Afghanistan

^c Department of Pathology, CURE International Hospital, Kabul, Afghanistan

ARTICLE INFO

Article history:

Received 20 October 2015

Accepted 5 December 2015

Available online 27 January 2016

Keywords:

Lipoma

Mesenteric and omental mass

Pediatric abdominal mass

Abdominal distension

ABSTRACT

Omental and mesenteric lipomas are very rare benign lesions of mature adipose tissue. They are well-defined, noninvasive, and encapsulated masses that can be discovered in asymptomatic patients or may cause variable nonspecific symptoms depending on their size and location. The omental and mesenteric lipoma has confusing features in ultrasound; however, computed tomography and magnetic resonance imaging can well characterize and demarcate these lesions. Though few cases of mesenteric and omental lipomas have been reported in the literature, but because of its large size and childhood presentation, the case we present, can be one of the largest childhood omental and mesenteric lipomas ever reported. A 6-year-old girl presented with slowly progressing abdominal distension and repeated dull abdominal pain for last 4 years. Abdominal and pelvic computed tomography examination revealed a huge mesenteric and omental lipoma that was resected surgically without any complications. Copyright © 2016, the Authors. Published by Elsevier Inc. under copyright license from the University of Washington. This is an open access article under the CC BY-NC-ND license (<http://creativecommons.org/licenses/by-nc-nd/4.0/>).

Case report

A six-year-old girl presented with slowly progressing abdominal distension and repeated dull abdominal pain for last 4 years. No history of vomiting, diarrhea, constipation, or urinary tract symptoms were present.

Abdominal ultrasound examination revealed a large, heterogeneous, relatively echogenic mass lesion occupying

almost entire abdominal cavity. The outlines of the lesion were not well recognizable on ultrasound. Apart from displacement of the major abdominal viscera to periphery of the abdominal cavity, no gross abnormality was detected in the intra-abdominal organs.

The patient subsequently underwent the abdominal and the pelvic computed tomography (CT) examination with 128-slice Siemens scanner.

Competing Interests: The authors have declared that no competing interests exist.

* Corresponding author.

E-mail address: Hedayatullah.hamidi@gmail.com (H. Hamidi).
<http://dx.doi.org/10.1016/j.radcr.2015.12.003>

1930-0433/Copyright © 2016, the Authors. Published by Elsevier Inc. under copyright license from the University of Washington. This is an open access article under the CC BY-NC-ND license (<http://creativecommons.org/licenses/by-nc-nd/4.0/>).

CT images revealed a huge, well-defined, low density, fat attenuation, nonenhancing, intraperitoneal, mass lesion occupying majority of the abdominal cavity. This large mass lesion was extending from just beneath the right dome of diaphragm down to level of symphysis pubis. Multiple fibrous septations and few specks of calcifications were seen within this essentially fatty lesion. No major abdominal vessels were traversing the lesion. There was no evidence of inflammatory reaction or infiltration of surrounding structures or tissues (Fig. 1A).

This well demarcated huge mass lesion was compressing the bowel loops rather than infiltrating them; however, no extension of the mass lesion was seen to the retroperitoneal spaces.

There was no sign of entering of any part of this fatty lesion into the spaces between the liver and right kidney or spleen and left kidney. This finding excluded the possibility of peritoneal lipomatosis.

The retroperitoneal structures and the bowel loops were displaced posterolaterally toward the abdominal walls. There was no evidence of any obstructive compression on gastrointestinal or urinary tract organs (Fig. 1B).

This mass lesion measured $28 \times 24 \times 10 \text{ cm}^3$ in maximum craniocaudal, transverse, and anteroposterior dimensions, respectively.

The patient underwent open abdominal surgery under general anesthesia and a huge, encapsulated mass was discovered adherent to the stomach, transverse colon, intestinal mesentery, and posterior abdominal wall. The mass was not separable from both the omentum and the mesentery.

As the mass lesion was neither originating from nor infiltrating the important abdominal viscera and blood vessels, so

this huge; 4 kilograms mass lesion was easily resected without major bleeding or postoperative complications.

Macroscopically it was a large, tan and gray color glistening surfaced, encapsulated, moderately firm mass. The cut sections of the mass showed homogenous yellowish tan soft surfaces (Fig. 2).

Microscopic sections showed tumor composed of large nodules and a sheet of mature adipocytes without atypia that were separated by thin fibrous bands. The findings were negative for malignancy (Fig. 3).

Keeping in view the clinical, radiological, surgical, and histological findings; a rare childhood giant omental and mesenteric lipoma was diagnosed.

Discussion

Lipomas are benign, well-defined, noninvasive, and encapsulated tumor of mature adipose tissue [1]. These common benign lesions can arise in any part of the body [2], but mesenteric and omental lipomas are rare entities [3,4].

A literature review performed by Cha, Jae Myung et al at 2007 showed that less than 30 cases of mesenteric lipomas were reported with only 7 cases in children. He presented a lipoma of $19 \times 10 \times 5.1 \text{ cm}^3$ in a 29-year-old man and argued that this was one of the largest lipomas reported in literature [3]. The case presented here; can exactly be one of the largest childhood omental and mesenteric lipomas reported.

Mesenteric lipomas are slow-growing, mobile, soft, masses that does not infiltrate the surrounding organs [5,6].

Abdominal cavity lipomas may be discovered as asymptomatic masses or they may cause variable nonspecific symptoms. These symptoms include progressive abdominal

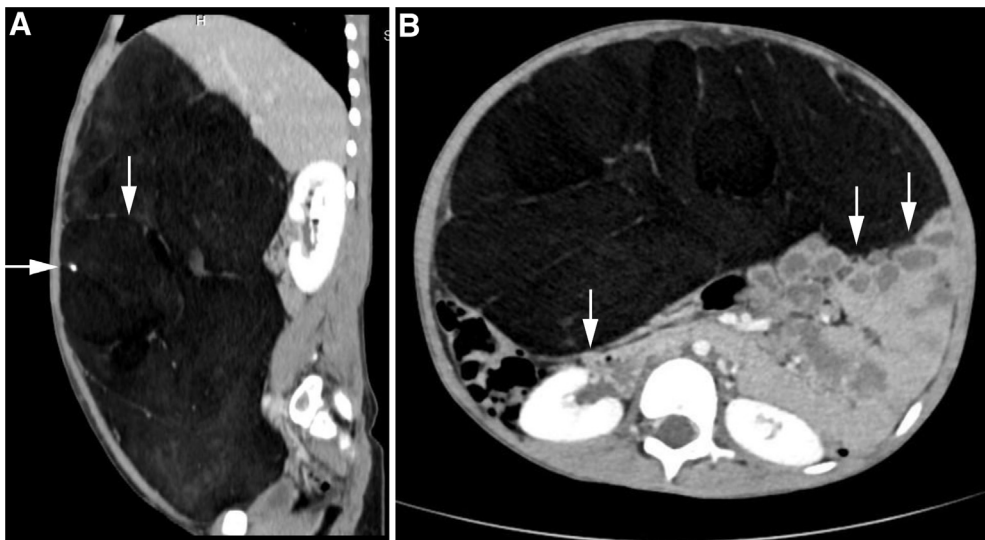


Fig. 1 – (A) Contrast-enhanced right parasagittal CT section through the abdomen and pelvis shows a huge, well-defined, low density, nonenhancing, intraperitoneal, mass lesion extending from the diaphragm down to pelvis. Note the fibrous septa and a calcified focus (arrow). No evidence of inflammatory reaction or infiltration of surrounding structures. (B) Contrast-enhanced axial CT section through the abdomen and pelvis: The well demarcated, low attenuating mass lesion is compressing the bowel loops rather than infiltrating them (arrows). No extension to the retroperitoneal spaces. The retroperitoneal structures and the bowel loops are displaced posterolaterally (arrows). No evidence of any obstructive compression on gastrointestinal or urinary tract organs.

Download English Version:

<https://daneshyari.com/en/article/4247938>

Download Persian Version:

<https://daneshyari.com/article/4247938>

[Daneshyari.com](https://daneshyari.com)