

Isolated traumatic rupture of the gallbladder

Benjamin Yin Ming Kwan, MD; Paul Plantinga, BSc(H), MD Cand.; and Ian Ross, BSc, MD, FRCPC

Gallbladder injury resulting from blunt abdominal trauma is rare, being found in only about 2% of patients who undergo laparotomy for abdominal trauma. Its small size and anatomic location—partially embedded in the liver tissue, surrounded by the omentum and intestines, and overlaid by the rib cage—provides good protection.

Diagnosis can be difficult, and delay may result in the development of weight loss, nausea, vomiting, abdominal distension, jaundice, ascites, and abdominal pains. Delayed imaging with computed tomography can aid in diagnosis, especially in differentiating benign processes from true gallbladder injuries.

Treatment for gallbladder injury is most commonly cholecystectomy. Mortality rates in patients with gallbladder injuries are related to associated injuries, including cardiac, thoracic or intra-abdominal hemorrhage, or multi-organ failure and/or brain damage. In isolated gallbladder injury, the prognosis is good.

Case report

A 59-year-old male presented to the emergency department after being struck by a train. The patient was hemodynamically stable upon arrival. On physical exam, the patient was grossly intoxicated and was tender in the right upper quadrant. Initial lab results revealed an elevated blood alcohol level of 67 mmol/L, elevated AST of 59 U/L, mildly elevated WBC of $10.4 \times 10^9/L$ and an elevated lactate of 2.6 mmol/L. Normal ALP, and total bilirubin of 83 U/L and 3.6 $\mu\text{mol/L}$, respectively.

The patient received a whole body scan under the trauma protocol. Computed tomography (CT) of the abdomen in the portal venous phase revealed fluid density surrounding the gallbladder, with areas of increased at-

tenuation (Fig. 1). On delayed imaging, there was increased layering of high-attenuation material, likely representing hemorrhage (Fig. 2). Additionally, there was a focal defect in the anterior wall of the gallbladder that was thought to represent perforation of the gallbladder. The only other injury seen on the CT images was a small liver laceration.

The patient was brought to the operating room for laparoscopic removal of the gallbladder. This was converted to an open laparotomy. Rupture of the gallbladder wall was seen; however, it was contained within the peritoneal covering of the gallbladder. No frank bile was seen in the abdominal cavity. Two small superficial liver lacerations in segment 4B and segment 5, which were both near the gallbladder, were also present. Surgical pathology revealed a thickened gallbladder wall measuring up to 0.6 cm with intramural red-brown hemorrhage. The gallbladder lumen was full of clotted blood.

Discussion

Etiology & demographics

Gallbladder injury resulting from blunt abdominal trauma is rare, as the gallbladder is a well protected organ due to its relatively small size and anatomic location. It is partially embedded in the liver tissue, surrounded by the omentum and intestines, and overlaid by the rib cage (1). Because of this protection, gallbladder injuries are usually associated with injury of other abdominal organs, espe-

Citation: Kwan BYM, Plantinga P, Ross I. Isolated traumatic rupture of the gallbladder. *Radiology Case Reports*. (Online) 2015;10(1);1029.

Copyright: © 2015 The Authors. This is an open-access article distributed under the terms of the Creative Commons Attribution-NonCommercial-NoDerivs 2.5 License, which permits reproduction and distribution, provided the original work is properly cited. Commercial use and derivative works are not permitted.

Drs. Kwan and Ross are affiliated with the London Health Sciences Centre, London, Ontario Canada. Dr. Plantinga is affiliated with the Schulich School of Medicine and Dentistry, London, Ontario, Canada. Contact Dr. Kwan at benjaminyming.kwan@londonhospitals.ca.

Competing Interests: The authors have declared that no competing interests exist.

DOI: 10.2484/rcr.v10i1.1029

Isolated traumatic rupture of the gallbladder

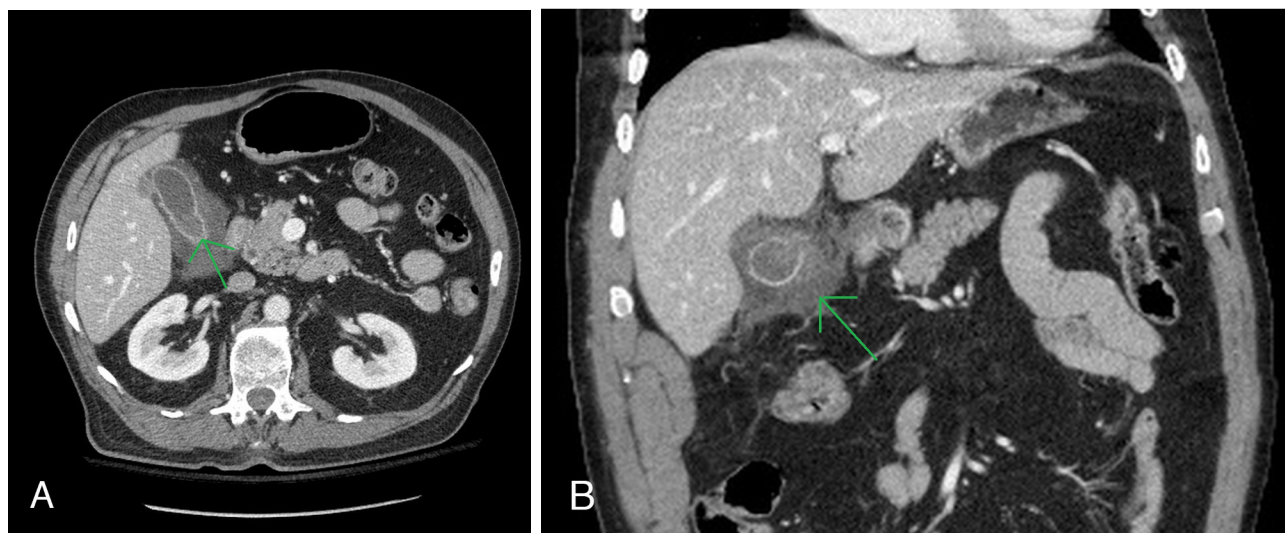


Figure 1, A and B. 59-year-old male with perforation of the gallbladder. Findings: Axial (A) and coronal (B) contrast-enhanced CT images of the abdomen through the gallbladder reveal wall thickening and focal mural disruption. Technique: Selected axial and coronal CT images of the abdomen and pelvis with IV contrast.

cially the liver (1, 2), making isolated gallbladder injury an even rarer occurrence (2, 3). Motor vehicle collisions are the most common cause of gallbladder injury, due to blunt abdominal trauma (1). Predisposing factors to gallbladder injury include a thin-walled normal gallbladder, a distended gallbladder, and alcohol ingestion (3), while a fibrotic thickened, chronically inflamed gallbladder is less likely to be

injured (4). Males are more commonly affected, with 73-89% of patients being male (1, 2), with a median age of 27 years, though wide age ranges have been reported (2, 4).

Gallbladder injuries are found in only about 2% of patients who undergo laparotomy for abdominal trauma (1). In a 13-year period at a level 1 urban trauma centre, of the over 40,000 injured patients seen, only 45 gallbladder injuries were detected. Of these patients, only 5 (11%) had suffered blunt abdominal trauma, either being struck by a vehicle or involved in a motor vehicle collision. The majority (89%) had experienced penetrating trauma, highlighting the rare occurrence of gallbladder injury as a result of blunt abdominal trauma (2). Gallbladder injuries rarely occur in isolation; most occur in conjunction with liver injury, with incidences reported at 83% to 91%. Associated injury to the spleen and duodenum are also common, in up to 54% of patients (1, 3, 5).

Classification of gallbladder injuries

Gallbladder injuries can be classified as contusion, perforation, or avulsion. Contusion is defined as an intramural hematoma. It is most often diagnosed at the time of laparotomy, and is thought to be underreported. Perforation, also referred to as rupture or laceration, is the most common gallbladder injury reported. Avulsion injuries are divided into three subtypes. In partial avulsion, the gallbladder is partially detached from the liver bed. In complete avulsion, the gallbladder is completely detached from the liver bed, but the cystic duct and artery remain intact. Total avulsion is when the gallbladder is free in the abdomen without any attachments (2, 3, 6).

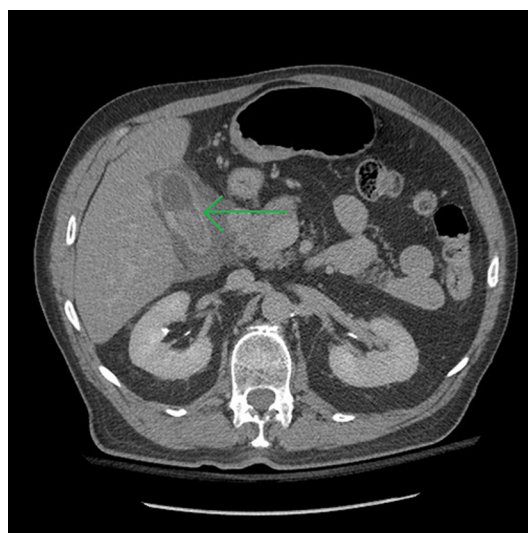


Figure 2. 59-year-old male with perforation of the gallbladder. Findings: Axial contrast-enhanced CT image of the abdomen through the gallbladder in the delayed phase demonstrates increasing density within the gallbladder representing accumulating blood within the gallbladder. Technique: Axial CT image of the abdomen and pelvis with IV contrast performed in the delayed phase.

Download English Version:

<https://daneshyari.com/en/article/4248003>

Download Persian Version:

<https://daneshyari.com/article/4248003>

[Daneshyari.com](https://daneshyari.com)