

## Susceptibility-Weighted Magnetic Resonance Imaging in the Evaluation of Dementia

James P. Larsen, M.D., William Britt, III, Ph.D., Daniel Kido, M.D., Brenda L. Bartnik Olson, Ph.D., Barbara A. Holshouser, Ph.D., and Wolff M. Kirsch, M.D.

An 88-year-old woman with a clinical diagnosis of Alzheimer's disease and advanced dementia, was evaluated with standard MRI of the brain as well as Susceptibility Weighted Imaging (SWI) with the MRI. SWI revealed more extensive brain microhemorrhages than standard MRI techniques, allowing the radiologic diagnosis of cerebral amyloid angiopathy. SWI shows promise as a more sensitive diagnostic tool than standard brain MRI for the evaluation of patients with dementia.

### Introduction

Neuroimaging techniques currently used for dementia evaluations are in a state of evolution with continued

---

Citation: Larsen JP, Britt W 3rd, Kido D, Olson BLB, Holshouser BA, and Kirsch WM. Susceptibility weighted magnetic resonance imaging in the evaluation of dementia. *Radiology Case Reports*. [Online] 2007;2:102.

Copyright: © James P. Larsen, M.D. This is an open-access article distributed under the terms of the Creative Commons Attribution-NonCommercial-NoDerivs 2.5 License, which permits reproduction and distribution, provided the original work is properly cited. Commercial use and derivative works are not permitted.

Abbreviations: CAA, cerebral amyloid angiopathy; CT, computed tomography; MRI, magnetic resonance imaging; PET, positron emission tomography; SWI, susceptibility weighted imaging;

James P. Larsen, M.D. (Email: [jp Larsen@llu.edu](mailto:jp Larsen@llu.edu)), is in the Department of Medicine Geriatric Medicine, Loma Linda University Medical Center, Loma Linda, CA 92354, United States of America.

William Britt, III, Ph.D., is in the Department of Psychiatry, Loma Linda University, Loma Linda, CA 92354, United States of America.

Daniel Kido, M.D., and Barbara A. Holshouser, Ph.D., are in the Department of Radiology, Loma Linda University Medical Center, Loma Linda, CA 92354, United States of America.

Wolff M. Kirsch, M.D. (Email: [wkirsch@llu.edu](mailto:wkirsch@llu.edu)), is at the Neurosurgery Center for Research, Training, and Education, Loma Linda University, Loma Linda, CA 92350, United States of America.

Funding sources: NIH Grant 5R01 AG20948

Published: October 1, 2007

DOI: 10.2484/rcr.v2i4.102

reassessments and reports of enhanced diagnostic accuracy [1-2]. Conventional CT and MRI brain imaging detects potentially treatable causes of dementia such as "normal pressure hydrocephalus," chronic subdural hematoma, strokes, and mass lesions [3]. PET scanning and MRI evidence of medial temporal lobe atrophy have been shown to be both sensitive and specific for diagnosing Alzheimer's disease [4-5]. Gradient-echo T2\* (GE-T2\*) weighted MR imaging detects cerebral microhemorrhages in lobar and subcortical patterns, findings that are considered highly suggestive for late-onset sporadic cerebral amyloid angiopathy [6-8].

Microhemorrhages associated with Alzheimer's disease may be an underestimated cause of progressive cognitive impairment in the elderly [9]. SWI is significantly more sensitive than GE-T2\* MRI technique for detecting iron-dependent blood products [11]. SWI has been used in the evaluation of trauma, tumors, vascular malformations and neurodegenerative diseases [12]. We report a case of dementia with a clinical diagnosis of AD and compare conventional GE-T2\* MRI with SWI MRI. In this case, the SWI demonstrated more extensive microhemorrhage involvement of the brain than GE-T2\* imaging.

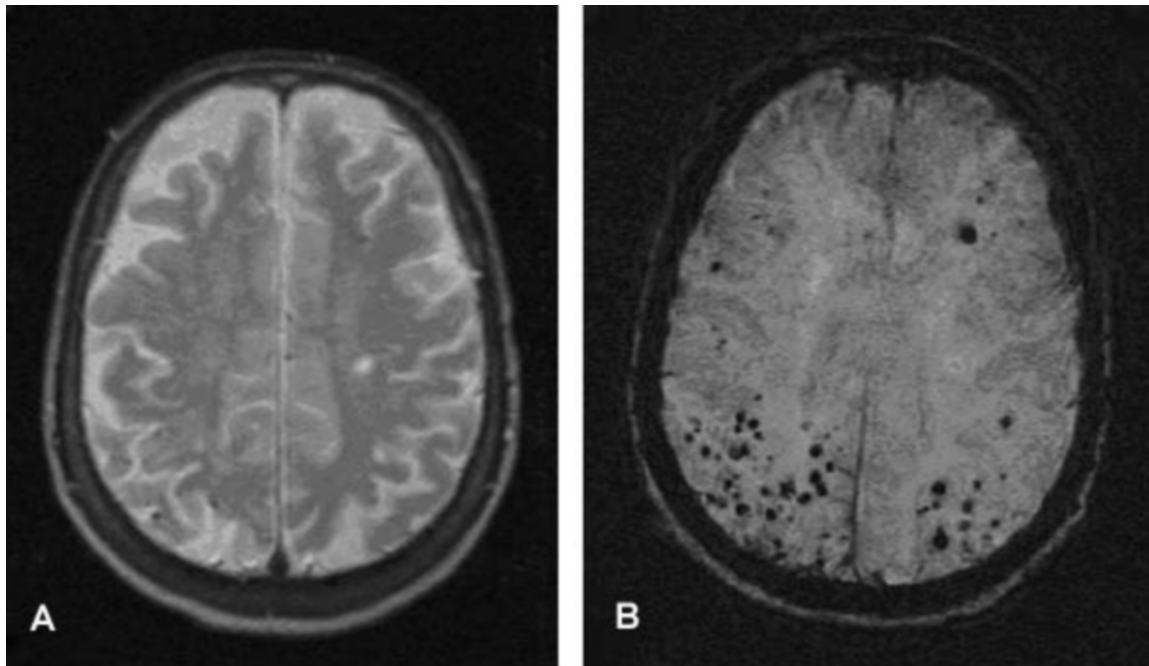


Figure 1. 88-year-old woman with severe dementia. Axial GE-T2\* MRI and corresponding SWI MRI through the centrum semiovale. A, The GE-T2\* image shows two small foci of hemorrhage in the right parietal lobe. B, The corresponding SWI image shows numerous hemorrhages in the frontal and parietal lobes.

### Case Report

An 88-year-old woman with a history of diabetes mellitus type II, medically controlled mild hypertension, asthma/chronic obstructive pulmonary disease, interstitial lung disease, and osteopenia presented to our gerontology service with a two-year history of slow but progressive cognitive impairment. Available history was obtained from the patient's daughter and granddaughter. The patient was living with her daughter and interacting on a daily basis with her family. Nothing in the neurological history suggested a neurovascular disorder - but rather a slow but progressive dementing process. There was no history of sudden or progressive motor or sensory defects, seizure disorders or headaches. Specifically, there was no history of unilateral extremity or facial weakness, diplopia, dysarthria, aphasia or sudden stepwise deterioration in cognitive function. There was no family history of dementia in her parents or siblings despite long life spans. There was no history of concussion or head trauma.

On physical examination, the patient was alert and conversant but with obvious signs of cognitive loss. She relied

on her daughter and granddaughter to answer questions. The neurological examination included normal fundoscopic and cranial nerve function, motor, sensory, cerebellar function as well as deep tendon reflex and plantar responses. A detailed neuropsychological evaluation and Clinical Dementia Rating (CDR) was attempted. The Sum of Boxes score on the CDR was 16.0 with a global CDR of 3.0, consistent with severe dementia.

Laboratory tests to include serum electrolytes, renal, thyroid liver function, and serum B12 level were within normal limits.

The patient did not have prior brain imaging. Conventional T1, T2, and FLAIR MRI at 1.5T revealed two to three microhemorrhages in the cerebellum. Conventional GE-T2\* images also showed several superficial areas of hypointensity (Fig. 1a). SWI images revealed significantly more numerous microhemorrhages involving both cerebral hemispheres, notably in the occipital lobes, as well as cerebellum (Fig. 1b).

This patient is still alive so there is no brain specimen available for pathological correlation.

Download English Version:

<https://daneshyari.com/en/article/4248495>

Download Persian Version:

<https://daneshyari.com/article/4248495>

[Daneshyari.com](https://daneshyari.com)