

Clinical note

An unusual presentation of primary hyperparathyroidism: multiple brown tumors and coexisting thyroid carcinoma

Y. Basaran^b, S. Ince^a, E. Alagoz^{a,*}, C. Meric^b, A. Taslipinar^b^a Gulhane Military Medical Academy and School of Medicine, Department of Nuclear Medicine, Etlik, Ankara, Turkey^b Gulhane Military Medical Academy and School of Medicine, Department of Endocrinology and Metabolism, Etlik, Ankara, Turkey

ARTICLE INFO

Article history:

Received 11 January 2016

Accepted 22 February 2016

Available online 29 March 2016

Keywords:

Parathyroid adenoma

Brown tumor

Bone scintigraphy

FDG PET/CT

ABSTRACT

We present a patient with a complex clinical picture of primary hyperparathyroidism with multiple destructive skeletal lesions suspicious of bone metastases and concomitant multifocal papillary thyroid carcinoma with a metastatic central lymph node. He presented with progressively worsening right hip pain and restricted motion. Magnetic resonance imaging revealed multiple lytic lesions involving predominantly the right trochanter minor and the left inferior and posterior pubic rami. Biochemical tests were consistent with primary hyperparathyroidism. Neck ultrasound and parathyroid scintigraphy revealed a single parathyroid adenoma and a thyroid nodule, preoperative cytology of which confirmed papillary thyroid carcinoma, as did the final surgical specimen. Biochemical results, regarding hyperparathyroidism, declined to normal levels and his complaints gradually decreased after surgery. Postoperative whole body bone scintigraphy showed increased tracer uptakes at multiple sites, but they were proved to be metabolically inactive by fluorodeoxyglucose positron emission tomography/computed tomography.

© 2016 Elsevier España, S.L.U. y SEMNIM. All rights reserved.

Presentación inusual de hiperparatiroidismo primario: múltiples tumores pardos y coexistencia de carcinoma tiroideo

RESUMEN

Presentamos el caso de un paciente con un cuadro clínico de hiperparatiroidismo primario, con muchas lesiones óseas destructivas sospechosas de metástasis óseas y carcinoma tiroideo multifocal concomitante con un ganglio linfático metastásico central. Se presentó con agravamiento progresivo de dolor y restricción de movimiento en la cadera derecha. La resonancia magnética reveló múltiples lesiones líticas que implicaban principalmente al trocánter menor derecho y a las ramas púbicas izquierdas inferior y posterior. Las pruebas bioquímicas fueron consistentes con un hiperparatiroidismo primario. La ecografía cervical y la gammagrafía paratiroidea revelaron un único adenoma paratiroideo y un nódulo tiroideo, cuya citología preoperatoria confirmó un carcinoma papilar de tiroides, que fue confirmado también por la muestra final obtenida quirúrgicamente. Los resultados bioquímicos, en relación con el hiperparatiroidismo, descendieron a niveles normales tras la cirugía, y los dolores fueron remitiendo gradualmente. La gammagrafía ósea postoperatoria de cuerpo entero reflejó un incremento de captación del radiotrazador en múltiples localizaciones, que resultaron ser metabólicamente inactivas en la tomografía por emisión de positrones con fluorodesoxiglucosa/tomografía computarizada.

© 2016 Elsevier España, S.L.U. y SEMNIM. Todos los derechos reservados.

Palabras clave:

Adenoma paratiroideo

Tumor pardo

Gammagrafía ósea

FDG PET/CT

Introduction

Brown tumors are rare non-neoplastic skeletal manifestations of primary and secondary hyperparathyroidism¹. Common sites of involvement are pelvis, femur and ribs, but may appear in any bone².

Since the incidence of thyroid disease is higher among patients with hyperparathyroidism than the general population³, these

lesions must be distinguished from metastases from thyroid carcinoma. Thus, a comprehensive preoperative evaluation, including fine-needle aspiration of thyroid nodules even not reported to have malignant features on ultrasound (US), should be carried out.

We present a case of a 38-year-old male with multiple brown tumors caused by primary hyperparathyroidism and coexisting metastatic multifocal papillary thyroid carcinoma.

Clinical case

The patient was admitted with expansile lytic lesions occupying mostly trochanter minor of the right femoral neck, and the left

* Corresponding author.

E-mail address: ealagoz@gata.edu.tr (E. Alagoz).

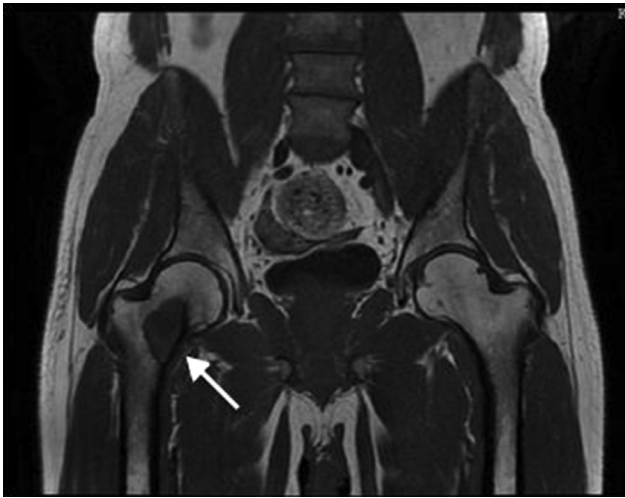


Fig. 1. Preoperative coronal T1-weighted MRI demonstrated a hypointense lytic expansile mass lesion at the trochanter minor of the right femoral neck (arrow). Significant contrast enhancement in the mass lesion and some degree of soft tissues expansion was noted.

inferior and posterior parts of pubic ramus (30 mm × 16 mm × 5.5 mm, 16 mm × 6.5 mm and 23 mm × 17 mm in diameter, respectively) on magnetic resonance imaging (MRI). They were reported to be hypointense on T1 and hyperintense on T2 weighted images, with various amounts of bone destruction, cortical thinning and some degree of soft tissue expansion around. Brown tumor was the most probable radiologic diagnosis (Fig. 1). At admission, he complained of severe hip pain, which had persisted for one year and progressively worsened over time, limiting his daily activities. On physical examination, tenderness with flexion and rotation of the right hip was detected, resulting in reduced range of motion in the hip joint. He had a 3-year history of kidney stones treatment with ureteral stenting and extracorporeal shock wave lithotripsy. But the rest of his medical history was unremarkable with no history of recent trauma.

Biochemical tests of note were PTH of 896.9 pg/mL (normal: 11.1–79.5), calcium of 15.06 mg/dL (normal: 8.5–10.5), phosphate of 1.87 mg/dL (normal: 2.6–4.5) and vitamin D3 of 18.4 mcg/L (normal: 11–70). Thyroid US displayed a 16 mm × 15 mm hypoechoic mass in the lower right pole of the gland, suggested for a parathyroid adenoma, and a thyroid nodule with irregular borders which was suspicious for malignancy (8 mm × 4 mm in diameter) in the left lobe. There were no grossly defined lymph nodes. Technetium-99m methoxyisobutylisonitrile (^{99m}Tc MIBI) scan revealed focal increased radiopharmaceutical uptake just

below the lower pole of right thyroid lobe (Fig. 2). Bone density by DXA revealed a distal radius *T*-score of −3.7. An ultrasound-guided fine-needle aspiration biopsy (FNAB) of the thyroid nodule was performed, which was suggestive of a malignant cytology. Pre-operative exploration for exclusion of multiple endocrine neoplasia did not find evidence of pituitary, pancreatic or adrenal tumors. To promote tumor regression and reduce hungry bone syndrome calcium and vitamin D treatment was initiated. Subsequently, the patient underwent bilateral total thyroidectomy with central compartment neck dissection and right inferior parathyroidectomy. Histological examination confirmed the presence of a parathyroid adenoma and three papillary micro-carcinomas of thyroid (with dimensions of 6 mm and 2 mm in the left lobe and 2 mm in the right lobe) with a central lymph node metastasis. Postoperatively, the patient received an ablative dose of 100 mCi (3700 MBq) iodine-131. Post-radioactive iodine whole body scan showed an uptake in the thyroid bed, but no ectopic uptake suggestive of local or distant metastases was visualized.

The patient was followed-up on levothyroxine 150 mcg daily and was in a complete remission, with undetectable levels of serum thyroglobulin (Tg) and anti-Tg postoperatively. PTH and calcium levels decreased to 53 pmol/L and 9.21 mg/dL, respectively. Moreover, the biochemistry regarding primary hyperparathyroidism remained normal during 3-monthly follow-ups and his symptoms of hip pain considerably weakened, but did not completely resolve. At the 18-month final follow-up, the patient persisted to experience mild symptoms of hip pain during activity and was subjected to whole-body bone scan, which revealed increased tracer uptakes in left sternoclavicular joint region, left proximal forearm, left pubic ramus and right femoral neck (Fig. 3). Single photon emission computed tomography/CT (SPECT/CT) images of the left ulna demonstrated an expansile lytic lesion with internal septas and SPECT/CT images of the pelvis showed increased tracer uptakes with peripheral sclerosis in the left pubic ramus and right femoral neck, the same osteolytic lesions seen on the preoperative MRI and postoperative whole body bone scans. In order to assess their metabolic activity, ¹⁸F-FDG PET/CT was performed. There was an increased ¹⁸F-FDG uptake only in the left sternoclavicular joint, which was highly suggestive of degeneration. No ¹⁸F-FDG uptake in the aforementioned lesions was detected (Fig. 4).

Discussion

Hyperparathyroidism is a relatively common disorder. However, brown tumor, also known as osteoclastoma, is a rare benign bone lesion with incidence ranging from 1.5% in primary hyperparathyroidism to 13% in secondary hyperparathyroidism⁴. It results from disturbed bone remodeling due to the long-lasting

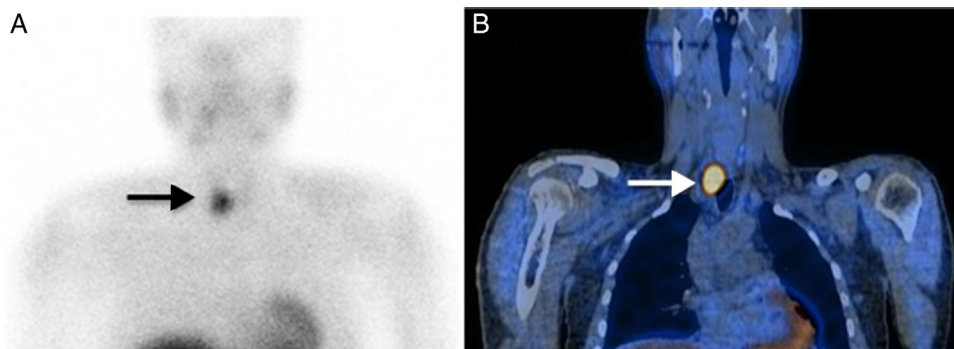


Fig. 2. ^{99m}Tc MIBI parathyroid scintigraphy planar (A) and SPECT/CT coronal (B) images showed a focus of intense radiopharmaceutical uptake (arrow) just below lower pole of the right thyroid lobe.

Download English Version:

<https://daneshyari.com/en/article/4249652>

Download Persian Version:

<https://daneshyari.com/article/4249652>

[Daneshyari.com](https://daneshyari.com)