



CASE REPORT

Closure of tracheoesophageal fistula with prefabricated deltopectoral flap



Shigeyuki Murono*, Eriko Ishikawa, Yosuke Nakanishi, Kazuhira Endo, Satoru Kondo, Naohiro Wakisaka, Tomokazu Yoshizaki

Department of Otolaryngology, Head and Neck Surgery, School of Medicine, Kanazawa University, Kanazawa, Ishikawa, Japan

Received 29 December 2012; received in revised form 24 December 2013; accepted 14 January 2014
Available online 25 March 2014

KEYWORDS

deltopectoral flap;
prefabricated;
skin graft;
total thyroidectomy;
tracheoesophageal
fistula

Summary Tracheoesophageal fistula (TEF) is a serious complication associated with impaired quality of life. However, a successful TEF closure is difficult owing to the high incidence of recurrence. We utilized a prefabricated deltopectoral (DP) flap for closure of a TEF that occurred after an extended total thyroidectomy. Prefabrication of the inner soft tissue lining the DP flap with a split skin graft was performed prior to surgical closure of a TEF. Esophageal and tracheal mucosa were sutured to the split thickness side and full thickness side of the prefabricated DP flap, respectively. A successful closure of the fistula was achieved with this procedure. Prefabricated DP flap is a useful procedure for the surgical treatment of TEF.

Copyright © 2014, Asian Surgical Association. Published by Elsevier Taiwan LLC. All rights reserved.

1. Introduction

Tracheoesophageal fistula (TEF) is a rare but life-threatening condition that promotes chronic aspiration, pneumonia, and tracheal stenosis.¹ Causes of acquired TEF

include ventilatory cuff injury, local infection, caustic or foreign body ingestion, penetrating or nonpenetrating trauma, tracheal or esophageal malignancy, and iatrogenic surgical injury. Although various surgical approaches have been described, a successful TEF closure remains difficult owing to the high incidence of recurrence.² We utilized a prefabricated deltopectoral (DP) flap for closure of a TEF that occurred after an extended total thyroidectomy.

Conflicts of interest: The authors declare that they have no financial or non-financial conflicts of interest related to the subject matter or materials discussed in the manuscript.

* Corresponding author. Department of Otolaryngology, Head and Neck Surgery, School of Medicine, Kanazawa University, Kanazawa, Ishikawa 920-8640, Japan.

E-mail address: murono@med.kanazawa-u.ac.jp (S. Murono).

2. Case report

A 65-year-old female patient was diagnosed with thyroid papillary carcinoma T4aN0M1 invading the trachea. A total

thyroidectomy with partial tracheal resection followed by creation of a tracheocutaneous fistula (TCF) was performed. However, leakage of saliva from the esophagus was observed after the surgery. Several procedures, including a direct closure and a pedicled myoperiosteal flap of the sternocleidomastoid muscle, were attempted to close the fistula. However, these procedures failed, resulting in a TEF measuring 1 cm in diameter at the left posterior wall of the trachea while the TCF still existed (Fig. 1). A two-stage operation was planned 92 days after the initial surgery.

The distal part of the DP flap was first elevated. At the same time, a 5×4 cm split skin graft was taken from the patient's left upper leg. Then the split skin graft was sutured to the inner soft tissue lining of the elevated DP flap using dissolvable sutures. The second procedure to close the TEF was performed 3–4 weeks later. First, an incision was made at the mucocutaneous junction along the unilateral edge of the TCF. The posterior wall of trachea was undermined and separated from the esophagus. When a severe scar formation prevented the tracheal wall from being undermined and separated from the esophagus, a circumferential excision of esophageal mucosa around the TEF including the dense scar tissue was performed. Subsequently, the prefabricated DP flap with well-healed skin graft was completely raised. The skin graft was de-epithelialized for a suitable size (Fig. 2). Esophageal mucosa was sutured around the split thickness side of the DP flap skin island to cover the esophageal defect (Fig. 3A). Tracheal mucosa was sutured to the full thickness side of the prefabricated DP flap to create a new TCF (Fig. 3B).

Videofluorography performed on the 36th day after the surgery did not demonstrate either leakage from the esophagus or laryngeal penetration, restoring the patient's ability to ingest a normal oral diet. Furthermore, the suitable volume of the DP flap allowed the TCF to become slender like a slit, which allowed excellent and fluent speech to develop without covering the TCF with her finger (Fig. 4). Moreover, the patient reported that there was no severe inconvenience during speech or food intake. Finally, closure of the TCF was then completed.

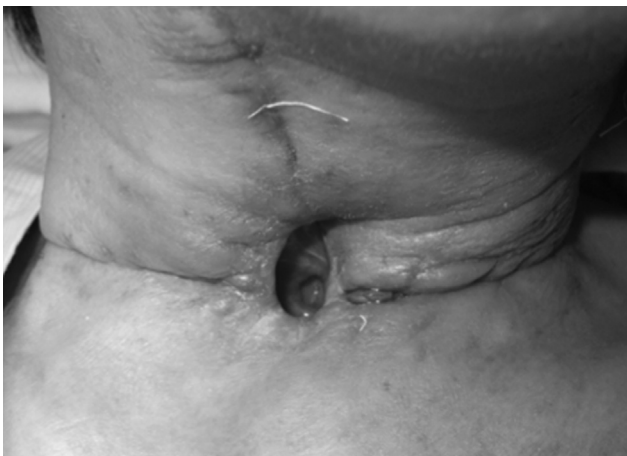

Figure 1 Tracheoesophageal fistula on the posterior wall of the trachea was observed through the tracheocutaneous fistula.

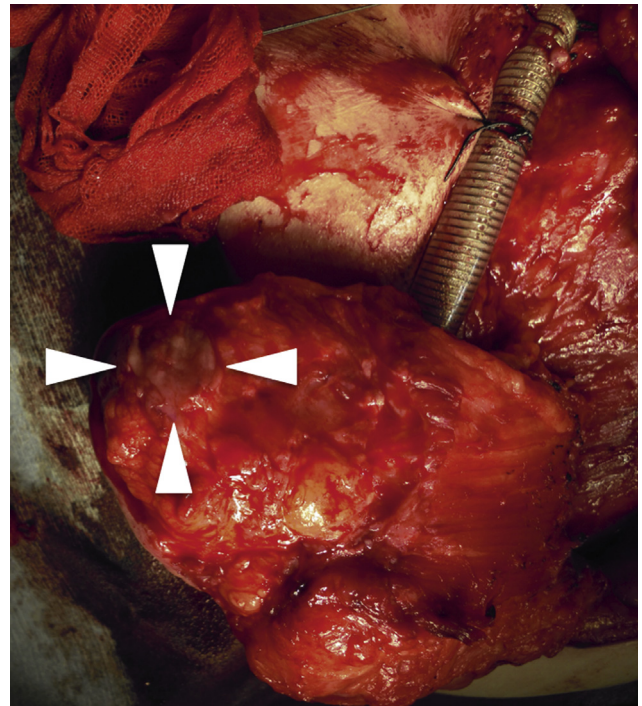


Figure 2 Prefabricated skin graft was de-epithelialized for 2.5 cm in diameter.

3. Discussion

The traditional surgical closure of a TEF includes fistula tract division and three-layer closure of the esophageal and tracheal linings with or without interposition of a pedicled regional skin or muscle flap.³ In this case, an alternative to the traditional procedure was required because of a dense scar formation around the TEF.

Although several free flaps including radial forearm flap and rectus abdominis flap and pedicled extracervical flaps including DP flap and pectoralis major myocutaneous flap have been reported to be useful for reconstruction of the pharynx and esophagus,^{4–7} we chose a DP flap with modification for closure of a relatively small TEF in this case. The removal of dense scarring around the TEF caused a mucosal defect not only in the esophagus, but also in the trachea. Therefore, a two-sided epithelial coverage of the TEF was preferred to close the esophageal leak and to create a new TCF as well as to circumvent possible postoperative issues of re-epithelialization compromise.

The procedure of grafting split-thickness skin onto the soft tissue side to create a bilaminar cervical flap has mainly been used for full-thickness cheek reconstruction including oral mucosa and facial skin.⁸ The only report describing the closure of a TEF with skin-grafted bilaminar flap is a radial forearm free flap.⁹ The size of the TEF in the report was relatively large, at 2×4 cm; therefore, using a wide thin well-vascularized flap appeared to be optimal. The surgeons sutured the full thickness skin side of the flap to the esophageal mucosa, and the split thickness side to the tracheal mucosa. In the present case, we utilized the DP flap as a skin-grafted bilaminar flap. We sutured the full

Download English Version:

<https://daneshyari.com/en/article/4282534>

Download Persian Version:

<https://daneshyari.com/article/4282534>

[Daneshyari.com](https://daneshyari.com)