



Original research

Axillary masses in a woman with a history of breast cancer: Dermatopathic lymphadenopathy



Nicola Rocco ^{a,*}, Gianni Antonio Della Corte ^b, Corrado Rispoli ^c, Vincenzo Sabatino ^d, Federica Romano ^d, Michele Altiero ^d, Maria Giulia Sommella ^e, Giuseppe Falco ^f, Rita Compagna ^b, Bruno Amato ^b, Antonello Accurso ^b

^a Department of Biomedical, Surgical and Dental Sciences, University of Milan, Milan, Italy

^b Department of Gastroenterology, Endocrinology and Surgery, University Federico II of Naples, Naples, Italy

^c Department of General Surgery – ASL NA1, Cardinale Ascalesi Hospital, Naples, Italy

^d Department of Advanced Biomedical Sciences – Section of Imaging, University Federico II of Naples, Naples, Italy

^e School of Medicine, Second University of Naples, Naples, Italy

^f Breast Unit, A.O. IRCCS Arcispedale S.M.N., Via Risorgimento 80, 42120 Reggio Emilia, Italy

ARTICLE INFO

Article history:

Received 15 May 2014

Accepted 15 June 2014

Available online 23 August 2014

Keywords:

Breast cancer

Dermatopathic lymphadenopathy

Axillary lymphadenopathy

ABSTRACT

The presence of axillary enlarged lymph nodes in the follow-up of a woman with a history of breast cancer should always be thoroughly indagated.

Dermatopathic lymphadenopathy presents a specific pathologic pattern found within the lymph nodes and is usually associated with cutaneous rashes.

Patients with various skin conditions can develop regional lymphadenopathy, which can result in the asymptomatic enlargement of the lymph nodes, especially in the inguinal, axillary and cervical regions.

Dermatopathic lymphadenopathy should be considered in the differential diagnosis also in patients with minimal cutaneous findings.

Dermatopathic lymphadenopathy is a benign process and management of these patients consists in simple clinical, mammographic and ultrasonographic follow-up.

© 2014 Surgical Associates Ltd. Published by Elsevier Ltd. All rights reserved.

1. Introduction

The presence of axillary enlarged lymph nodes in the follow-up of a woman with a history of breast cancer should always be thoroughly indagated.

Axillary nodes larger than 1.5 cm that do not contain a fatty hilum may be considered abnormal [1]. In a series evaluating axillary abnormalities, the most frequent cause of axillary adenopathy was nonspecific benign lymphadenopathy (29% of cases), followed by metastatic breast cancer (26%) and chronic

lymphocytic leukemia or well differentiated lymphocytic lymphoma (17%). Other causes included collagen vascular disease, lymphomas other than well-differentiated lymphocytic lymphoma, metastatic disease for primary site other than breast, sarcoidosis, human immunodeficiency virus-related lymphadenopathy, psoriasis and reactive lymphadenopathy associated with a breast abscess [2].

Reactive axillary nodal enlargement is common after breast biopsy [3]. It is also frequently seen after infection or inflammation of the upper extremity or breast. When nodal enlargement without an obvious cause is seen and the node maintains a benign appearance, no further intervention is usually needed other than correlation with clinical findings to exclude worrisome palpable axillary adenopathy [3].

Follow-up mammography is a reasonable alternative to biopsy if the patient has no history of malignancy, the amount of increase in nodal size is small and the node maintains a benign appearance.

In a study by Lee et al. [4] considering patients who had unilaterally enlarging axillary or intramammary lymph nodes or otherwise normal mammograms, the majority of those who

* Corresponding author. Department of Biomedical, Surgical and Dental Sciences, University of Milan, Via R. Galeazzi 4, 20161 Milan, Italy.

E-mail addresses: nicola.rocco@unimi.it, nicolarocco2003@gmail.com (N. Rocco), ga.dellacorte@gmail.com (G.A. Della Corte), super_rbros@hotmail.com (C. Rispoli), vincenzosabatino@yahoo.it (V. Sabatino), federikkaromano@hotmail.it (F. Romano), michelealtiero@hotmail.it (M. Altiero), mg.sommella@gmail.com (M.G. Sommella), giuseppe.falco@asmn.re.it (G. Falco), rita.compagna@libero.it (R. Compagna), bramato@unina.it (B. Amato), antonello.accurso@unina.it (A. Accurso).

underwent unilateral follow-up mammography 6 months later showed a decrease in the size of the enlarged nodes.

If a mammographically benign-appearing mass is identified in the outer breast in association with infection or dermatitis, dermatopathic lymphadenitis should be considered [5].

A size increase of 100% or more over baseline size and morphologic features such as change in shape, spiculation of the margins, loss of a radiolucent center or hilar notch and increase in density should increase the degree of suspicion for malignancy [4].

Homogenously dense axillary lymph nodes were strongly associated with malignancy when they were longer than 33 mm, had ill-defined or spiculated margins or contained intranodal microcalcification and the patient had no history of gold therapy for rheumatoid arthritis [2].

In a study conducted to evaluate mammographic findings in breast infection and biased to include those patients with more severe inflammation, abnormally dense and enlarged lymph nodes were not observed in any case, although not all axillary lymph nodes were visualized at mammography [6].

The primary tumor within the breast is usually depicted mammographically when lymph nodes enlarge because of metastatic breast cancer [7]. However the tumor may be occult [7,8].

The normal US appearance of a lymph node is that of a hypoechoic mass with well-circumscribed margins and a fatty echogenic hilum. With malignancy, the fatty hilum may be lost, the shape may become irregular and calcifications can be seen [9]. The presence of nodal spiculation suggests an aggressive tumor [10].

2. Case report

We report a case of a 65 years old woman who underwent left upper-outer quadrant quadrantectomy and axillary dissection for breast cancer in 2005. At a follow-up mammography performed in September 2013, she presented some enlarged lymph nodes at the level of the contralateral axilla.

Axillary masses appeared as mobile, nontender, firm subcutaneous nodules at physical examination. No masses were present at both breasts examination.

No skin lesions were present at the level of both upper limbs and breasts. No alterations were present at blood laboratory examinations.

Mammographic appearance of the lymph nodes did not show any change in shape, spiculation of the margins, intranodal microcalcification, but they appeared as homogenously dense,

without a radiolucent center and one of them measured more than 35 mm (Fig. 1).

No suspect densities or masses were described at the level of both breasts at mammography.

Ultrasonography showed right axilla enlarged hypoechoic masses with well-circumscribed margins and fatty echogenic hilum, one lymph node measuring 34.1 mm (Fig. 2).

In relation to the breast cancer history of the patient lymph node cytology was performed.

Cytology revealed reactive paracortical hyperplasia with vascular proliferation and eosinophil granulocytes infiltration, with an increased number of interdigitating dendritic cells and Langerhans cells and negative immunocytochemistry staining for CK-Pan.

Cytology diagnosed a dermatopathic lymphadenopathy, in the absence of clear cutaneous involvement. The patient had a history of psoriasis, without any skin lesion at the moment of the lymphadenopathy diagnosis.

Only clinical, mammographic and ultrasonographic follow-up was requested for the patient, who shows a stability of the clinical and imaging findings at one year from diagnosis.

3. Discussion

Dermatopathic lymphadenopathy (DL) was originally described by Pautrier and Woringer in French in 1937 but the name dermatopathic lymphadenitis was coined and published in English by Hurwitt in 1942 [11].

Dermatopathic lymphadenopathy is a benign process with a specific pathologic pattern found within the lymph nodes and is usually associated with cutaneous rashes.

Patients with various skin conditions can develop regional lymphadenopathy, which can result in the asymptomatic enlargement of the lymph nodes, especially in the inguinal, axillary and cervical regions. The lymph nodes are generally mobile, nontender, firm subcutaneous nodules.

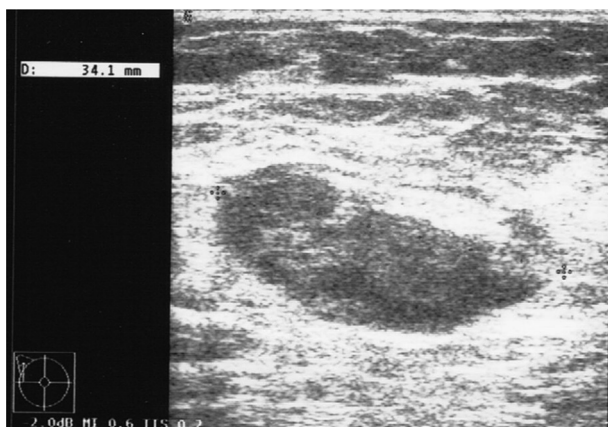


Fig. 1. Ultrasonography showing an enlarged (34.1 mm) hypoechoic mass with well-circumscribed margins and fatty echogenic hilum at the level of the right axilla.

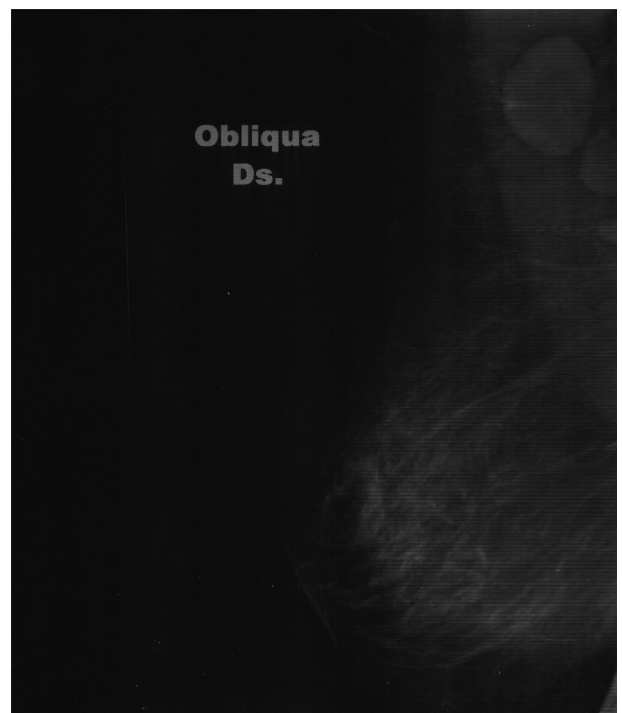


Fig. 2. Mammographic oblique view of the right breast showing homogenously dense enlarged axillary masses.

Download English Version:

<https://daneshyari.com/en/article/4286576>

Download Persian Version:

<https://daneshyari.com/article/4286576>

[Daneshyari.com](https://daneshyari.com)