



Contents lists available at ScienceDirect

International Journal of Surgery Case Reports

journal homepage: www.casereports.com

Laparoscopic extra-abdominal suturing technique for the repair of Larrey's diaphragmatic hernia using the port closure needle (Endo Close®): A case report

Yuji Yamamoto, Kazuaki Tanabe*, Ryuichi Hotta, Nobuaki Fujikuni, Tomohiro Adachi, Toshihiro Misumi, Yoshihiro Saeki, Hiroki Takehara, Hideki Ohdan

Department of Gastroenterological and Transplant Surgery, Applied Life Sciences, Institute of Biomedical & Health Sciences, Hiroshima University, 1-2-3, Kasumi, Minami-ku, Hiroshima 734-8551, Japan

ARTICLE INFO

Article history:

Received 22 July 2016

Received in revised form

11 September 2016

Accepted 11 September 2016

Available online 21 September 2016

Keywords:

Larrey's hernia

Morgagni's hernia

Diaphragmatic hernia

Laparoscopic repair

Extra-abdominal suturing technique

ABSTRACT

INTRODUCTION: Morgagni's or Larrey's diaphragmatic hernias are relatively uncommon. If the defect is too large for primary closure, the use of a mesh is inevitable. Although primary closure is adaptable for relatively small defects, it is difficult to suture the hernial orifice in which the anterior rim is absent. Herein, we present the case of a patient with Larrey's diaphragmatic hernia that was easily and securely repaired using the recently developed laparoscopic extra-abdominal suturing technique via the port closure needle (Endo Close®; Medtronic, Minneapolis, USA).

PRESENTATION OF CASE: An 89-year-old woman complaining of vomiting was transferred to our hospital. Computed tomography scan showed Larrey's diaphragmatic hernia. Laparoscopic repair was performed after gastric decompression. We diagnosed Larrey's hernia on the left side of the falciform ligament. The transverse colon was herniated through the defect. Since the hernial defect was located below the substernal space, there was no tissue to stitch at the anterior rim of the hernial orifice. We performed the extra-abdominal suturing technique, suturing the posterior rim of the hernia to the full thickness of the anterior abdominal wall using the port closure needle (Endo Close®) without the need for a mesh. The patient was discharged on the 8th postoperative day. There was no evidence of recurrence at 8 months postoperatively.

DISCUSSION: The recently developed extra-abdominal suturing technique using Endo Close® to suture the full thickness of the anterior abdominal wall achieved secure mattress suture and easy extra-abdominal tying.

CONCLUSION: This method may be useful in terms of easiness and security of suture.

© 2016 Published by Elsevier Ltd on behalf of IJS Publishing Group Ltd. This is an open access article under the CC BY-NC-ND license (<http://creativecommons.org/licenses/by-nc-nd/4.0/>).

1. Introduction

Morgagni's or Larrey's diaphragmatic hernias are relatively uncommon. Surgical repair is indicated in symptomatic patients, and asymptomatic patients who are at risk of incarceration or strangulation. If the defect is too large for primary closure, the use of a mesh is inevitable. Although primary closure is adaptable for relatively small defects, it is technically difficult to suture the hernial orifice in which the anterior rim is absent. A variety of repairing techniques have been described to address this problem. Herein,

we present the case of a patient with Larrey's diaphragmatic hernia that was laparoscopically repaired by the recently developed extra-abdominal suturing technique using Endo Close® to suture the full thickness of the anterior abdominal wall.

2. Presentation of case

An 89-year-old woman complaining of vomiting was transferred to our hospital. She had no other associated symptoms, no past surgical history, and no traumatic rupture of the diaphragm. She was in a good general condition, and clinical examination was unremarkable. No abnormalities were detected in the laboratory investigations. Chest radiography (Fig. 1A) and computed tomography (Fig. 1B) scan showed Larrey's diaphragmatic hernia. Hernial contents were transverse colon and stomach, and they showed no ischemic changes. A few days after computed tomography and gastric decompression, the contrast medium passed slowly to the

* Corresponding author.

E-mail addresses: ktanabe2@hiroshima-u.ac.jp (K. Tanabe), hotta.kuma@gmail.com (R. Hotta), bfxfw264@yahoo.co.jp (N. Fujikuni), adachitomohiro@hotmail.com (T. Adachi), lupinn3sei@yahoo.co.jp (T. Misumi), wttwtwxslikexth@ybb.ne.jp (Y. Saeki), turimeijinn82@yahoo.co.jp (H. Takehara), hohdan@hiroshima-u.ac.jp (H. Ohdan).

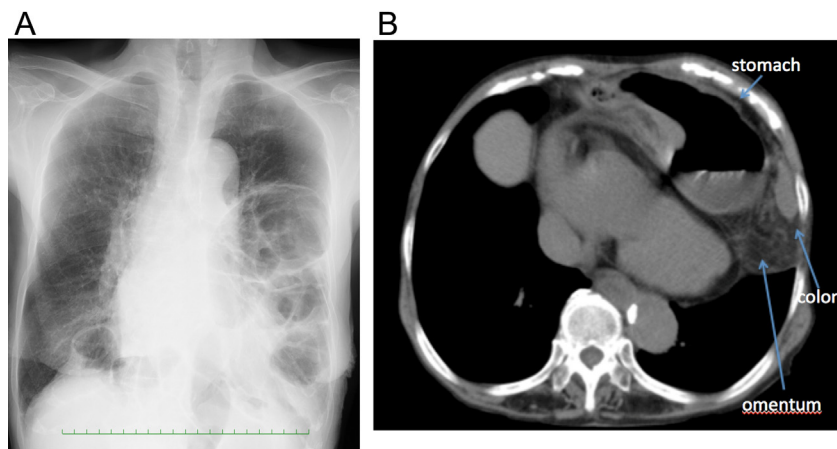


Fig. 1. (A) Chest radiograph showing colonic gas above the left diaphragm in the left middle and lower lung zones. (B) Chest computed tomography scan showing the transverse colon, greater omentum, and stomach incarcerated in the left pleural cavity.

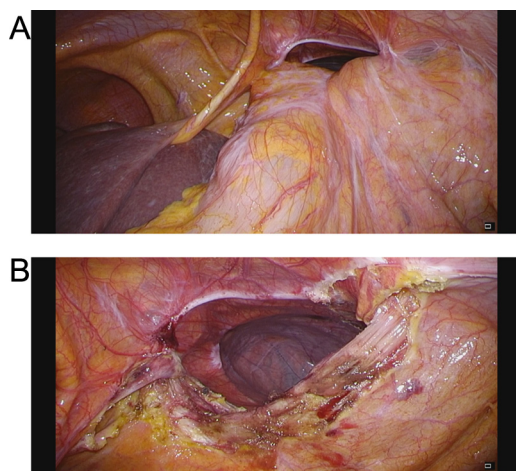


Fig. 2. (A) Laparoscopic view showing the transverse colon herniating through the defect on the left side of the falciform ligament. (B) The hernia content reduced into the abdominal cavity.

small intestine due to gastric decompression. Vomiting occurred because of incarceration of the stomach in the left pleural cavity, and was unresponsive to conservative therapy. Therefore, laparoscopic repair was planned.

Under endotracheal general anesthesia, the patient was positioned in the supine position. The first port was inserted at the umbilicus using an open technique. Five millimeter and 12 mm working ports were introduced under direct vision from the right and left upper quadrants at the mid clavicular lines, respectively.

We diagnosed Larrey's hernia based on the intraoperative findings of an anterior diaphragmatic defect of approximately 4.0×4.0 cm located in the left side of the falciform ligament. The transverse colon was found herniating through the defect (Fig. 2A) and was reduced into the peritoneal cavity (Fig. 2B). The mesocolon was adhering to the posterior rim of the defect, and was separated by laparoscopic coagulating shears. The stomach was not herniating through the defect intraoperatively, as it probably returned to the abdominal cavity due to preoperative gastric decompression. Since the hernia was located between the substernal space and the posterior border of the diaphragm, there was no tissue to stitch at the anterior rim of the hernial orifice. Primary closure of the hernial orifice was not possible; hence, we decided to suture the posterior rim of the hernia to the full thickness of the anterior abdominal wall using the extra-abdominal suturing technique. First, a 2-0 Prolene

suture attached to a curved needle was inserted into the abdominal cavity. A horizontal mattress suture was taken at the posterior rim of the hernia and the needle was removed from the abdominal cavity. A 2-cm incision was made at the epigastrium above the anterior border of the hernia. The port closure needle (Endo Close®) was inserted into the abdominal cavity, taking one end of the Prolene suture to the outside of the abdominal cavity (Fig. 3A). The other end was similarly removed. Following the same steps, 4 more sutures were placed and held (Fig. 3B). All 5 sutures were tied without tension. The knots were laid in the subcutaneous tissue. Closure of the hernial orifice was observed (Fig. 4). No hernia sac was removed, and using a mesh was not necessary. The operative time was 89 min. The postoperative course was uneventful. The patient underwent rehabilitation postoperatively because of her old age, and was discharged on the 8th postoperative day. There was no evidence of recurrence at 8 months postoperatively.

3. Discussion

Herniation through the subcostosternal space or Morgagni-Larrey's hernia is quite uncommon, representing only about 1% to 6% of all surgically repaired diaphragmatic hernias [1]. Morgagni's hernia was first described by Morgagni GB, an Italian anatomist, in 1761, being located through a defect in the diaphragm just behind the sternum [2].

The hernial defect results from the failure of fusion of septum transversum of the diaphragm and the costal arches. According to its laterality, it is known as "Morgagni's" or "Larrey's" hernia for left or right sided defects, respectively [3]. Right, left, and bilateral hernias have incidences of 91%, 5%, and 4%, respectively [4]. Having similar anatomical origin, they are collectively referred to as "anterior diaphragmatic hernia of Morgagni-Larrey" [5].

Horton et al. reviewed 298 adult cases with Morgagni-Larrey's hernia, and reported that 28% of these patients were asymptomatic [4]. In the same study, symptoms reported included pulmonary symptoms (dyspnea, cough, and shortness of breath) (36%), chest or abdominal discomfort not related to bowel obstruction (37%), symptoms due to obstruction (20%), and dysphagia (3%). The omentum (31%), colon and omentum (29%), stomach (15%), small bowel (11%), and liver (4%) were found within the hernia.

Traditional indications for surgical repair of this hernia are symptomatic patients, and asymptomatic patients who are at a risk of incarceration or strangulation. However, Loong et al. suggested that if the hernia is small or contains omentum only, then surgical repair is indicated when symptoms are recurrent and bothersome [7]. Surgical repair of the hernia has been accomplished

Download English Version:

<https://daneshyari.com/en/article/4288122>

Download Persian Version:

<https://daneshyari.com/article/4288122>

[Daneshyari.com](https://daneshyari.com)