

Contents lists available at [ScienceDirect](http://www.sciencedirect.com)

## International Journal of Surgery Case Reports

journal homepage: [www.casereports.com](http://www.casereports.com)

# High negative pressure subcutaneous suction drain for managing debilitating subcutaneous emphysema secondary to tube thoracostomy for an iatrogenic post computed tomography guided transthoracic needle biopsy pneumothorax: Case report and review of literature

Zeeshan Ahmed\*, Pinakin Patel, Suresh Singh, Raj Govind Sharma, Pankaj Somani, Abdul Rauf Gouri, Shiv Singh

Department of Surgical Oncology, SMS Medical College and Hospital, JLN Marg, Jaipur, 302004, Rajasthan, India

## ARTICLE INFO

## Article history:

Received 6 May 2016

Received in revised form 22 July 2016

Accepted 22 July 2016

Available online 27 July 2016

## Keywords:

Subcutaneous emphysema

Pneumothorax

Tube thoracostomy

Case report

## ABSTRACT

**INTRODUCTION:** Subcutaneous emphysema is a common complication of tube thoracostomy. Though self-limiting, it should be treated when it causes palpebral closure, dyspnea, dysphagia or undue disfigurement resulting in anxiety and distress to the patient.

**PRESENTATION OF CASE:** A 72 year old man who was a known case of COPD on bronchodilators developed a large pneumothorax and respiratory distress after a CT guided transthoracic lung biopsy done for a lung opacity (approx. 3 × 3 cm) at the right hilar region on Chest X-ray. Within 24 h of an urgent tube thoracostomy, patient developed intractable subcutaneous emphysema with closure of palpebral fissure and dyspnea unresponsive to increasing suction on chest tube. A subcutaneous fenestrated drain was placed mid-way between the nipple and clavicle in the mid-clavicular line bilaterally. Continuous negative suction (-150 mmHg) resulted in immediate, sustained relief and complete resolution within 5 days.

**DISCUSSION:** Extensive and debilitating SE (subcutaneous emphysema) has to be treated promptly to relieve patient discomfort, dysphagia or imminent respiratory compromise. A variety of treatment have been tried including infraclavicular blow-hole incisions, subcutaneous drains +/- negative pressure suction, fenestrated angiocatheters, Vacuum assisted dressings and increasing suction on a pre-existing chest tube. We describe a high negative pressure subcutaneous suction drain which provides immediate and sustained relief in debilitating SE.

**CONCLUSION:** Debilitating subcutaneous emphysema which causes distress, anxiety, palpebral closure, dyspnoea or dysphagia requires intervention. High negative pressure subcutaneous suction drain provides immediate and sustained relief in extensive and debilitating SE.

© 2016 The Authors. Published by Elsevier Ltd on behalf of IJS Publishing Group Ltd. This is an open access article under the CC BY-NC-ND license (<http://creativecommons.org/licenses/by-nc-nd/4.0/>).

## 1. Introduction

Pneumothorax secondary to transthoracic needle biopsy (TTNB) is a common complication which has to be treated with tube thoracostomy in severe cases. Chest tube malposition and subcutaneous emphysema are common complications of tube thoracostomy.

\* Corresponding author.

E-mail addresses: [drzeeshan180@gmail.com](mailto:drzeeshan180@gmail.com) (Z. Ahmed), [drpinakin@gmail.com](mailto:drpinakin@gmail.com) (P. Patel), [drsureshsingh@gmail.com](mailto:drsureshsingh@gmail.com) (S. Singh), [rajgovindsharma@gmail.com](mailto:rajgovindsharma@gmail.com) (R.G. Sharma), [dr.pankajsomani@yahoo.com](mailto:dr.pankajsomani@yahoo.com) (P. Somani), [rauf.mbb04@gmail.com](mailto:rauf.mbb04@gmail.com) (A.R. Gouri), [meena1989shivsingh@gmail.com](mailto:meena1989shivsingh@gmail.com) (S. Singh).

<http://dx.doi.org/10.1016/j.ijscr.2016.07.031>

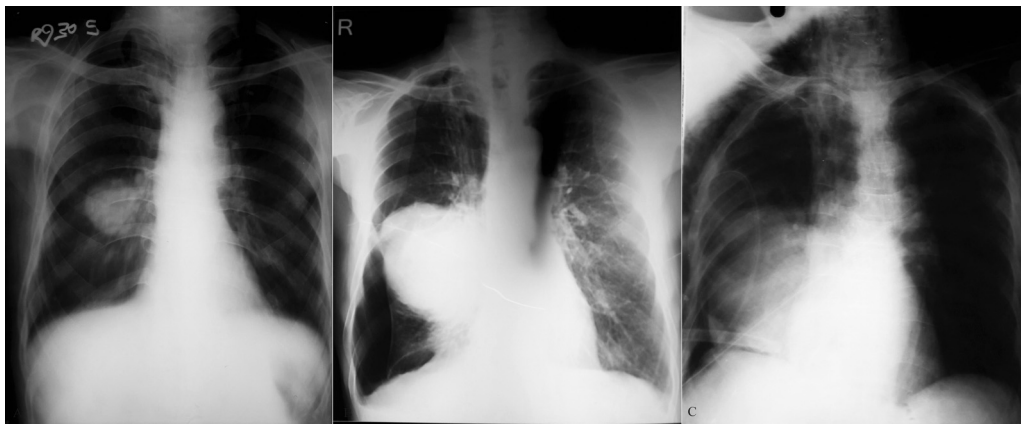
2210-2612/© 2016 The Authors. Published by Elsevier Ltd on behalf of IJS Publishing Group Ltd. This is an open access article under the CC BY-NC-ND license (<http://creativecommons.org/licenses/by-nc-nd/4.0/>).

Extensive and debilitating subcutaneous emphysema (SE) has to be treated promptly to relieve patient discomfort, dysphagia or imminent respiratory compromise. We describe a high negative pressure subcutaneous suction drain which provides immediate and sustained relief in debilitating SE.

## 2. Presentation of case

A 72 year old man who was a known case of Chronic obstructive pulmonary disease (COPD) was referred to us for evaluation of a lung opacity (approx. 3 × 3 cm) at the right hilar region. (Fig. 1A) He was chronic smoker (60 pack years).

Physical examination revealed a hyper-resonant chest on percussion, and prolonged expiration with wheezing on auscultation.



**Fig. 1.** (A) Chest X-ray PA view showing an opacity (approximately 3 × 3 cm) at the right hilar region with silhouette sign. Bilateral flattening of the diaphragms, a long narrow heart shadow, hyperlucency of the lungs with rapid tapering of vascular shadows are noted. (B) Chest X-ray PA view showing a large pneumothorax with a larger lung opacity than the previous X-ray. (C) Chest X-ray AP view (supine) showing chest drain in situ in the 7th right intercostal space pointing centrally and lying just above the right diaphragm.

Fiberoptic bronchoscopy showed narrowing of lumen of Right upper, middle, and intermediate bronchus due to extrabronchial compression and bronchoscopic biopsy was inconclusive. Contrast enhanced CT(CECT) scan of chest revealed evidence of hypodense large well defined egg shaped solid mass lesion of size 6.7 × 5.7 cm noted in right middle lobe of lung in posterobasal segment with well-defined margins. Pulmonary function test (PFT) revealed a FEV1 (Forced expiratory volume1) to be 1.36/3.20, 43% of predicted value.

A CT guided transthoracic lung biopsy was done. Subsequently, the patient complained of dypnoea with decreased air entry on the right side and hyperresonant note on percussion. A chest X-ray confirmed a large Right pneumothorax. (Fig. 1B) An urgent bedside tube thoracostomy with a 32 F Malecot catheter was done and connected to an underwater seal. The patient's condition improved and the pneumothorax resolved completely as seen on the repeat chest X-ray AP view but the tube was malpositioned in the 7th intercostal space and directed centrally. The tube was withdrawn by 2 cm. As the water column was moving and the lung had re-expanded, we decided to wait and watch. (Fig. 1C) There was a persistent air leak in the chest tube which made us suspect rupture of a large emphysematous bullae. The patient developed SE in the right chest wall which slowly progressed to the entire chest wall, abdomen, bilateral thighs, neck, face and bilateral palpebral fissures over the next 24 h. Eventually, the patient was unable to open his eyes and started complaining of dyspnoea and dysphagia. Applying negative suction on the chest tube upto – 40 cm of water did not relieve the condition. Since the first chest tube was functioning and the lungs had re-expanded, we decided against using a second chest tube which would have been more invasive option than a subcutaneous suction drain under high negative suction pressure. Two 1.5 cm horizontal incisions were made in the skin and subcutaneous tissue bilaterally in the anterior chest wall mid-way between the nipple and the clavicle in the mid clavicular line. A plane was created just above the pectoralis fascia using a hemostat forceps. We inserted the fenestrated limbs of a readily available 12F negative suction subcutaneous drain (Romo Vac Set, Romsons International, Noida, India). The efferent limb of the drain was attached to the negative pressure suction apparatus at a continuous high pressure of – 150 mmHg. A manual compression massage was done from the face downwards to force the already trapped air towards the fenestrated limbs. There was an immediate relief to the patient and the patient could open his eyes immediately (Fig. 2). The pressure applied was constant at – 150 mmHg. A repeat CECT thorax showed the chest tube to be located in the Right

oblique fissure with marked right pneumothorax, extensive bilateral SE, presence of emphysematous bullae in bilateral lung fields, and a large heterogeneous density lesion with irregular margins in right lower lobe (Fig. 3).

The time to complete resolution was 5 days after which the subcutaneous drains were removed. The chest drain was removed on the 6th day post drain insertion as there was no air leak.

The patient was eventually diagnosed with Small cell cancer lung and is currently receiving Cisplatin-etoposide combination chemotherapy.

### 3. Discussion

The most common complications of transthoracic needle biopsy (TTNB) are pneumothorax (20.5%) and clinically significant hemorrhage (2.8%) [1]. Risk factors for developing a post-TTNB pneumothorax are increased depth of lesion, increased patient age, increased time of needle across the pleura, traversal of a fissure and presence of COPD and emphysema [2]. Most of these pneumothorax are self-limiting, but some intractable cases eventually require chest tube drainage.

The British thoracic society has described a triangle of safety for intercostal drain insertion bordered by the lateral border of the pectoralis major, anterior border the latissimus dorsi, a line superior to the horizontal level of the nipple and apex below the axilla [3]. Ball et al. described tube thoracostomy complications as insertional (visceral or parietal injuries of the intercostal artery or intra-parenchymal lung), positional (extrathoracic placement or atypical intrathoracic placement resulting in tube failure and replacement) or infectious (wound infection or empyema) [4]. In cases of malposition of chest tube, if a tube is inserted in the 5th, 6th or 7th intercostal space in the lateral chest wall and directed centrally, it is more likely to enter the oblique fissure [5]. Thoracic CT scan is the most reliable investigation to detect a mal-positioned chest tube [4]. In a review of 76 chest tubes placed in 61 patients by residents, there were 17 (22.4% per procedure) complications with non-surgical residents more likely to have complications [4].

Subcutaneous emphysema (SE) is common complication self-limited complication of tube thoracostomy. Any SE on positive pressure ventilation, causing palpable cutaneous tension, palpebral closure, dysphagia, and dysphonia or associated with pneumoperitoneum, airway compromise, “tension phenomenon” and respiratory failure is labelled extensive SE as defined by Srinivas et al. [6].

Download English Version:

<https://daneshyari.com/en/article/4288203>

Download Persian Version:

<https://daneshyari.com/article/4288203>

[Daneshyari.com](https://daneshyari.com)