

Contents lists available at [ScienceDirect](http://www.sciencedirect.com)

## International Journal of Surgery Case Reports

journal homepage: [www.casereports.com](http://www.casereports.com)

## Laparoscopic resection of a hepatic mucinous cystic neoplasm: A case report



Shinsaku Obara, Takeo Nomi\*, Ichiro Yamato, Daisuke Hokuto, Satoshi Yasuda, Satoshi Nishiwada, Chihiro Kawaguchi, Takahiro Yoshikawa, Takatsugu Yamada, Hiromichi Kanehiro, Yoshiyuki Nakajima

Department of Surgery, Nara Medical University, 840 Shijo-cho, Kashihara-shi, 634-8522 Nara, Japan

## ARTICLE INFO

## Article history:

Received 20 April 2016

Accepted 25 April 2016

Available online 28 April 2016

## Keywords:

Case report

Laparoscopic liver resection

Liver

Mucinous cystic neoplasm

Ovarian-like stroma

## ABSTRACT

**INTRODUCTION:** We aimed to present a case of hepatic mucinous cystic neoplasm (MCN-H) that was completely resected by laparoscopy.

**PRESENTATION OF CASE:** A 47-year-old female exhibited mild elevation of serum liver enzyme levels. Abdominal computed tomography revealed a 45-mm multilocular cystic tumor in segment IV of the liver, along with intermittent border calcification and minimal wall thickness. Magnetic resonance imaging revealed fluid-to-fluid level in the cystic tumor, thereby increasing the suspicion of a mild hemorrhage. The patient underwent laparoscopic liver resection (LLR) with a diagnosis of suspected mucinous cystic neoplasm of the liver. The entire tumor was successfully resected with a laparoscopic approach. The resected specimen was a 4.2 × 3.3 × 2.2-cm cystic tumor. Histological findings revealed mucin-producing singular epithelium and ovarian-like stroma. The tumor was diagnosed as a MCN-H with no malignancy.

**DISCUSSION:** This is the first report in which a MCN-H was completely resected by laparoscopy. MCN-H is rare and is observed in only <5% of liver cystic tumors. MCN-H has been reported to have the malignant potential. And complete resection might be a good treatment option. Along with technical development, LLR has been indicated for benign liver tumors to date. Benign liver tumors are commonly observed in young females. The smaller incisions of the laparoscopic approach might provide cosmetic advantages for patients.

**CONCLUSION:** We presented the first case of a MCN-H completely resected by laparoscopy. Benign tumors and tumors with malignant potential might be good indications for a laparoscopic surgery.

© 2016 The Author(s). Published by Elsevier Ltd on behalf of IJS Publishing Group Ltd. This is an open access article under the CC BY-NC-ND license (<http://creativecommons.org/licenses/by-nc-nd/4.0/>).

## 1. Introduction

The number of laparoscopic liver resections (LLR) being performed has been rapidly increasing, together with improvements in surgical techniques and various surgical instruments. The second International Consensus Conference on Laparoscopic Liver Resection (ICLLR) held in 2014 indicated that laparoscopic approaches have demonstrated superiority in selected patients compared with open procedures, particularly for minor liver resections. To date, benign liver tumor has been a good indication for LLR because of its smaller incisions, less pain, and cosmetic advantages.

The World Health Organization (WHO) has categorized mucin-producing bile duct tumors into two distinct entities: hepatic mucinous cystic neoplasm (MCN-H) and mucin-producing intra-ductal papillary neoplasm of the bile duct (M-IPNB) [1]. MCN-H, a rare tumor with reported incidence of <5% of all cystic liver

tumors, is clearly defined as a cyst-forming epithelial neoplasm composed of mucin-producing epithelium associated with ovarian-like stroma. Furthermore, MCN-H has no communication with the bile ducts [2,3]. Several authors have reported improved prognosis with complete resection of MCN-H [2].

In this report, we present the first case of MCN-H that was completely resected with a laparoscopic approach.

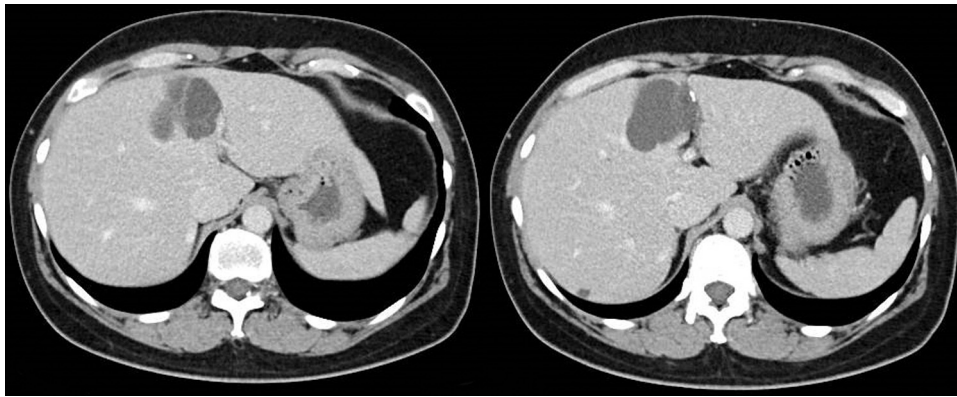
## 2. Presentation of case

A 47-year-old woman presented at the outpatient clinic to treat uterine leiomyoma. On blood chemical analysis, mild elevations were observed in the serum liver enzyme levels: gamma-glutamyl transpeptidase, 335 U/L; alkaline phosphatase, 390 U/L; alanine transaminase, 64 U/L; and aspartate transaminase, 89 U/L. However, the serum bilirubin level was not elevated at 0.5 mg/dL. Furthermore, carcinoembryonic antigen 19-9 was slightly elevated at 45 U/mL, and alpha-fetoprotein was within normal limits.

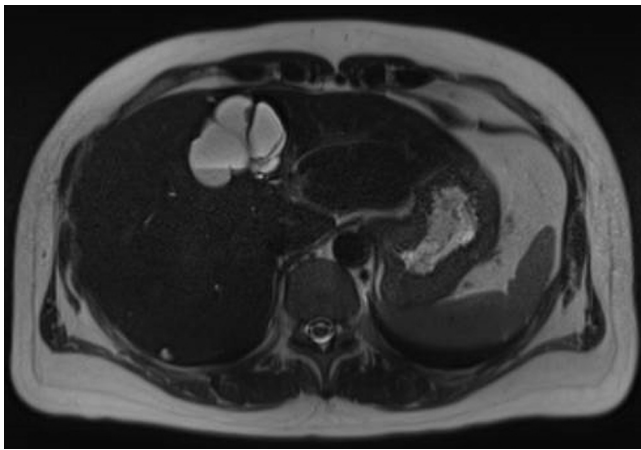
Dynamic multi-detector computed tomography (MDCT) was performed to investigate the cause of liver dysfunction. MDCT

\* Corresponding author.

E-mail address: [t.nomi45@gmail.com](mailto:t.nomi45@gmail.com) (T. Nomi).



**Fig. 1.** A multilocular cystic tumor was observed in segment IV of the liver. The tumor was 45 mm in diameter and had septations. CT revealed calcification of the cystic wall and slight wall thickness. There was no mural nodularity or communication to bile ducts.



**Fig. 2.** T2-weighted MRI revealed a high intensity on the ventral side and low intensity on the backside of the tumor. Fluid-fluid level was observed on the border, thereby leading to the suspicion that mild hemorrhage may have occurred in the cystic tumor.

revealed a 45-mm multilocular cystic tumor located in segment IV of the liver. The tumor had septations and border calcification in some areas as well as slight wall thickness (Fig. 1). T2-weighted MRI revealed fluid-to-fluid level in the cystic tumor that was suggestive of mild hemorrhage (Fig. 2). CT and MRI revealed no communication between the tumor and bile ducts.

On the basis of these findings, the patient was diagnosed with suspected MCN-H. M-IPNB, echinococcus cyst, and hepatocellular carcinoma with necrosis were addressed as differential diagnoses. Liver biopsy was not considered because the tumor was only composed of cystic regions without solidity. The patient underwent LLR. The tumor existed in segment IV near the right side of the umbilical portion. A yellowish-white cystic tumor was observed in the inferior border of the liver. Liver parenchyma was transected with a laparoscopic Cavitron Ultrasonic Surgical Aspirator (Valleylab, Boulder, CO). The tumor was completely resected with a laparoscopic approach. Intraoperative blood loss was 50 ml, and the duration of surgery was 377 min. The patient was discharged 7 days after surgery with no postoperative complications.

The resected specimen demonstrated a 4.2 × 3.3 × 2.2-cm subcapsular multiloculated cyst. Microscopically, mucin-producing single-layered epithelium was observed, and there were no signs of malignancy. Ovarian-like stroma was confirmed by positive immunostaining for both estrogen and progesterone receptors (Fig. 3). Histologically, the tumor was diagnosed as MCN-H with low-grade dysplasia.

### 3. Discussion

To the best of our knowledge, this is the first report in which a MCN-H was completely resected by a laparoscopic procedure. MCN-H is very rare and is observed in <5% of liver cystic tumors [4]. The classification proposed by WHO has defined mucin-producing bile duct tumors of the liver into two categories: MCN-H and IPMN-B [5]. In this classification, MCN-H is clearly defined as a cyst-forming epithelial neoplasm composed of mucin-producing epithelium and associated with ovarian-like stroma. It has been reported that MCN-H is observed only in female patients and have no communication to bile ducts [2,3]. These are the main characteristics for distinguish MCN-H from M-IPNB. Therefore, this case detected almost exact findings as per the definition declared by WHO.

An accurate preoperative diagnosis between MCN-H and M-IPNB is very difficult. Lee et al. have indicated that although six patients received preoperative percutaneous aspiration cytology or biopsy, the interpretation did not provide any specific diagnoses [6]. In general, MCN-H presents as a low-density mass with internal septa that demonstrates enhancement with intravenous contrast medium on CT. On T2-weighted MRI, MCN-H presents as a multilocular cystic mass containing liquids with various signal intensities in the different loculi [7]. In this case, there was no connection with the surrounding bile ducts, however, calcification was observed in some parts of the cystic wall. MRI revealed almost same intensities in each cyst; however, fluid-to-fluid level was observed that was caused by hemorrhage in the cyst.

MCN-H has been reported to have the potential for malignancy. Indeed, it is classified as low-, intermediate-, and high-grade intraepithelial neoplasia or an associated invasive carcinoma. However, the treatment of MCN-H still remains controversial. Previous reports suggest that complete surgical resection might be a good treatment option to prevent recurrence or potential malignant transformation [8–12]. A recent publication has reported that none of the 11 patients who underwent liver resection developed recurrence, whereas >60% of patients who underwent liver preserving surgery developed postoperative recurrence [6]. In contrast, MCN-H has been reported with good long-term survival rates after liver resection. Kubota et al. reported 5-year survival rates of 100% after liver resection for MCN-H [2]. Therefore, liver resection might be recommended for patients with MCN-H.

With technical development of LLR, indications for this procedure have recently expanded. A large number of publications have highlighted the benefits of minimally invasive LLR compared with open liver resection, including less pain, better cosmetic results, decreased mortality rates, and reduced length of hospital stay

Download English Version:

<https://daneshyari.com/en/article/4288234>

Download Persian Version:

<https://daneshyari.com/article/4288234>

[Daneshyari.com](https://daneshyari.com)