



Contents lists available at ScienceDirect

International Journal of Surgery Case Reports

journal homepage: www.casereports.com

Strangulated transmesosigmoid hernia as a late complication of a fall from a height: A case report



Shigehiro Kojima*, Tsuguo Sakamoto, Masayuki Honda, Dal Ho Kim

Department of Surgery, Sainokuni Higashiomiya Medical Center, 1522 Toro-cho, Kita-ku, Saitama 331-0804, Japan

ARTICLE INFO

Article history:

Received 9 June 2016

Accepted 19 August 2016

Available online 26 August 2016

Keywords:

Abdominal blunt trauma

Case report

Internal hernia

Intestinal obstruction

Laparoscopic herniorrhaphy

Sigmoid mesocolon hernia

ABSTRACT

INTRODUCTION: A transmesosigmoid hernia is defined as small bowel herniation through a complete defect involving both layers of the sigmoid mesentery. Blunt trauma injury to the sigmoid mesocolon has been reported only rarely. We herein report a case of a strangulated transmesosigmoid hernia associated with a history of a fall from a height.

PRESENTATION OF CASE: A 43-year-old woman presented to our hospital for evaluation of vomiting. She had no history of abdominal surgery but had sustained a complete spinal cord injury and pelvic fracture secondary to a fall from a height 25 years earlier. A computed tomography scan of her abdomen and pelvis demonstrated a closed loop of small bowel in the pelvis, with a zone of transition in the left lower abdomen. Although the cause of the obstruction was difficult to establish, ischemia was strongly suspected; therefore, the decision was made to perform emergency exploratory laparoscopy. During laparoscopy, a loop of ileum was observed to have herniated through a full-thickness defect in the sigmoid mesocolon, consistent with a transmesosigmoid hernia. The herniated loop was strangulated but not gangrenous and was successfully reduced using laparoscopic graspers. The incarcerated small bowel appeared viable and was therefore not resected. The defect was closed with a running suture. The patient had an uneventful postoperative course with no recurrence.

DISCUSSION AND CONCLUSION: Abdominal blunt trauma can cause sigmoid mesenteric rupture resulting in a transmesosigmoid hernia. In the management of transmesosigmoid hernias, laparoscopic herniorrhaphy has the advantage of facilitating simultaneous diagnosis and surgical intervention.

© 2016 The Author(s). Published by Elsevier Ltd on behalf of IJS Publishing Group Ltd. This is an open access article under the CC BY-NC-ND license (<http://creativecommons.org/licenses/by-nc-nd/4.0/>).

1. Introduction

A transmesosigmoid hernia is characterized by herniation of the small bowel through a complete defect involving both layers of the sigmoid mesocolon [1]. Mesenteric defects can be congenital, surgical, traumatic, inflammatory, or idiopathic in origin [2]. Blunt trauma injury to the sigmoid mesentery, unlike that to the mesentery of the small intestine, has been reported only rarely. Because hernias involving the sigmoid mesocolon are very difficult to diagnose preoperatively, prompt diagnostic and therapeutic surgical intervention is essential [3]. We herein report a case of successful laparoscopic management of a strangulated transmesosigmoid hernia in a patient with a history of a fall from a height.

2. Presentation of case

A 43-year-old woman was admitted to our hospital with a 1-day history of vomiting. She had no history of abdominal surgery but had sustained a complete spinal cord injury and pelvic fracture secondary to a fall from a height 25 years earlier. Because of this trauma, the patient had no motor or sensory function below the C5 level. Physical examination revealed tachycardia and generalized abdominal distension. She had no abdominal tenderness or guarding. Her groin examination was normal, and no signs of herniation through the femoral or inguinal canal were present. Laboratory investigation revealed leukocytosis (white blood cell count of $28,100/\text{mm}^3$ with a marked left shift) and mild renal dysfunction (serum creatinine level of 1.19 mg/dL). Abdominal radiographic findings were compatible with small bowel obstruction. A computed tomography scan of her abdomen and pelvis demonstrated an extensively dilated small bowel and a closed loop of small bowel in the pelvis, with no signs of adhesion, malignancy, or an inflammatory etiology (Fig. 1). A transition zone was seen in the left lower abdomen, where significant surrounding mesenteric fat stranding was observed, and ischemia was strongly suspected (Fig. 2). However, the cause of the obstruction was difficult to determine from

* Corresponding author.

E-mail addresses: oshige113gou@yahoo.co.jp (S. Kojima), tsuguo.sakamoto@achs.jp (T. Sakamoto), masayuki.honda@shmc.jp (M. Honda), tkim@shmc.jp (D.H. Kim).

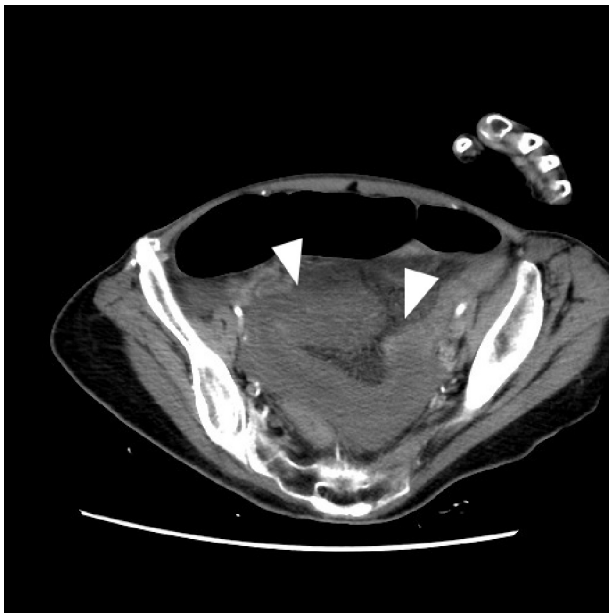


Fig. 1. Computed tomography showing a closed loop of the small bowel in the pelvis (arrowheads).

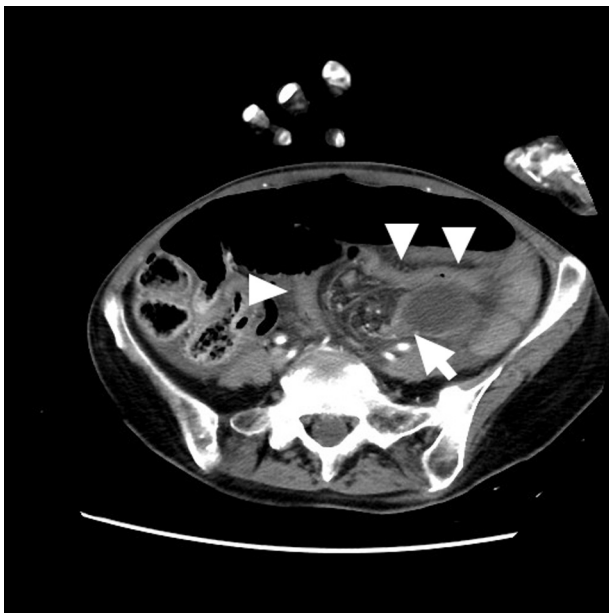

Fig. 2. Computed tomography showing the transition zone (arrow) in the left lower abdomen. There is significant surrounding mesenteric fat stranding. Arrowheads indicate sigmoid colon.

the patient's clinical and computed tomography findings; therefore, emergency exploratory laparoscopy was performed.

With the patient under general anesthesia, an infraumbilical incision was made and a 10-mm port was placed for the laparoscope. Two 5-mm ports were placed in the right middle and lower abdomen for additional instruments. Laparoscopy revealed a mechanical small bowel obstruction due to an incarcerated internal hernia. A loop of an ileum had herniated through a full-thickness defect in the sigmoid mesocolon, consistent with a transmesosigmoid hernia without a sac (Fig. 3). The herniated loop was strangulated but not gangrenous. The defect was slightly enlarged with a small incision, and the herniated loop was successfully reduced using laparoscopic graspers (Fig. 4). The approximately

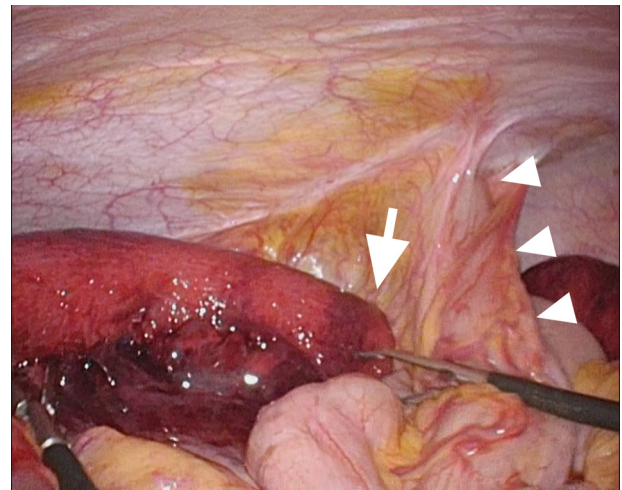


Fig. 3. Intraoperative photograph. A loop of ileum is seen herniating through a full-thickness defect (arrow) in the sigmoid mesocolon. Arrowheads indicate sigmoid colon.

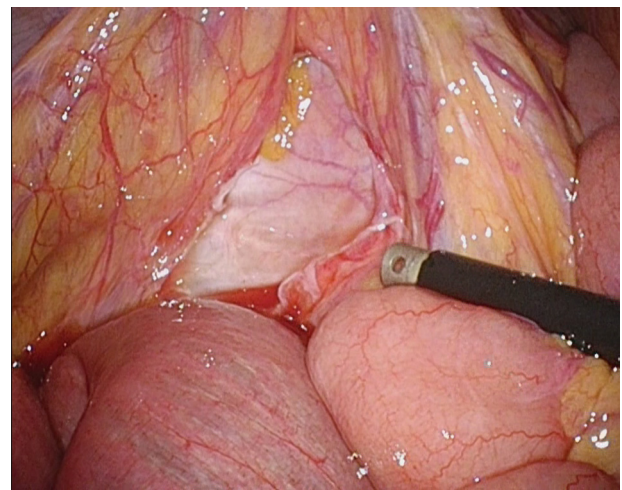


Fig. 4. Intraoperative photograph showing the sigmoid mesocolic defect after reduction of the incarcerated small bowel.

15 cm of incarcerated small bowel appeared viable and was therefore not resected. The defect was repaired with a running suture. The patient had an uneventful postoperative course. She was discharged home on postoperative day 9 and had developed no recurrence at the time of this writing.

3. Discussion

This patient's course reveals two important clinical issues. First, abdominal blunt trauma can rupture the sigmoid mesentery, resulting in a transmesosigmoid hernia. Falls from a height induce a specific type of blunt force trauma produced by rapid vertical deceleration and a high impact force [4]. Deceleration forces typically cause stretching and linear shearing at the interfaces between fixed and mobile parts of the gastrointestinal tract, such as at the ligament of Treitz [5]. Blunt trauma injury to the sigmoid mesentery, unlike that to the small intestinal mesentery, has been reported only rarely. Eleven previous studies were identified by searching the PubMed database using the terms *transmesosigmoid* and *hernia* with no limits on the date of publication [1,3,6–14] (Table 1). A few hypotheses about the etiology of mesenteric defects are available in these reports; however, there are no reports of patients

Download English Version:

<https://daneshyari.com/en/article/4288327>

Download Persian Version:

<https://daneshyari.com/article/4288327>

[Daneshyari.com](https://daneshyari.com)