



Contents lists available at ScienceDirect

## International Journal of Surgery Case Reports

journal homepage: [www.casereports.com](http://www.casereports.com)

# A rare case of ischaemic pneumatosis intestinalis and hepatic portal venous gas in an elderly patient with good outcome following conservative management

E.J. Nevins<sup>a,\*</sup>, P. Moori<sup>b</sup>, C.S.J. Ward<sup>a</sup>, K. Murphy<sup>a</sup>, C.E. Elmes<sup>a</sup>, J.V. Taylor<sup>a</sup><sup>a</sup> Emergency General Surgery and Trauma Unit, University Hospital Aintree, Liverpool, England L9 7AL, United Kingdom<sup>b</sup> University of Liverpool Medical School, Liverpool, England L69 3BX, United Kingdom

## ARTICLE INFO

## Article history:

Received 7 June 2016

Received in revised form 20 June 2016

Accepted 20 June 2016

Available online 23 June 2016

## Keywords:

Pneumatosis intestinalis  
Hepatic portal venous gas  
Conservative  
Survival  
Non-operative  
Ischaemia

## ABSTRACT

**INTRODUCTION:** Pneumatosis intestinalis (PI) and hepatic portal venous gas (HPVG) are typically associated and are likely to represent a spectrum of the same disease. The causes of both entities range from benign to life-threatening conditions. Ischaemic causes are known to be fatal without emergency surgical intervention.

**PRESENTATION OF CASE:** In this case a 93 year old male experienced acute abdominal pain radiating to his back, with nausea and vomiting and a 2-week history of altered bowel habit. Examination revealed abdominal tenderness and distension. He had deranged white cell count (WCC) and renal function. Computed tomography (CT) revealed PI with associated HPVG. The cause was due to ischaemic pathology. The patient was managed conservatively with antibiotics and was discharged 7 days later with resolution of his abdominal pain and WCC.

**DISCUSSION:** The pathogenesis of HPVG secondary to PI is poorly understood but usually indicates intestinal ischaemia, thought to carry a mortality of around 75%. HPVG in the older patient usually necessitates emergency surgery however this is not always in the patient's best interest.

**CONCLUSION:** There are few reported cases of patient survival following conservative management of PI and HPVG secondary to ischaemic pathology. This case demonstrates the possibility of managing this condition without aggressive surgical intervention especially when surgery would likely result in mortality due to frailty and morbidity. Further work is required to identify suitable patients.

© 2016 The Authors. Published by Elsevier Ltd on behalf of IJS Publishing Group Ltd. This is an open access article under the CC BY-NC-ND license (<http://creativecommons.org/licenses/by-nc-nd/4.0/>).

## 1. Introduction

The use of computed tomography (CT) has resulted in a more frequent diagnosis of pneumatosis intestinalis (PI) and hepatic portal venous gas (HPVG) [1,2]. PI is characterised by submucosal gas within the gastrointestinal tract. HPVG is defined as gas anywhere within the portal venous system from the superior mesenteric vein and its tributaries to the intrahepatic system. HPVG is typically allied with PI and is likely to represent a spectrum of the same disease [1,3]. Both entities result from a variety of benign to life-threatening pathologies. PI or HPVG caused by ischaemic disease, with or without mesenteric thrombus, has almost unanimously been reported to have fatal outcomes without operative intervention [1,3–8]. Here we report a rare case of PI and HPVG caused by ischaemic pathology which was managed conservatively without

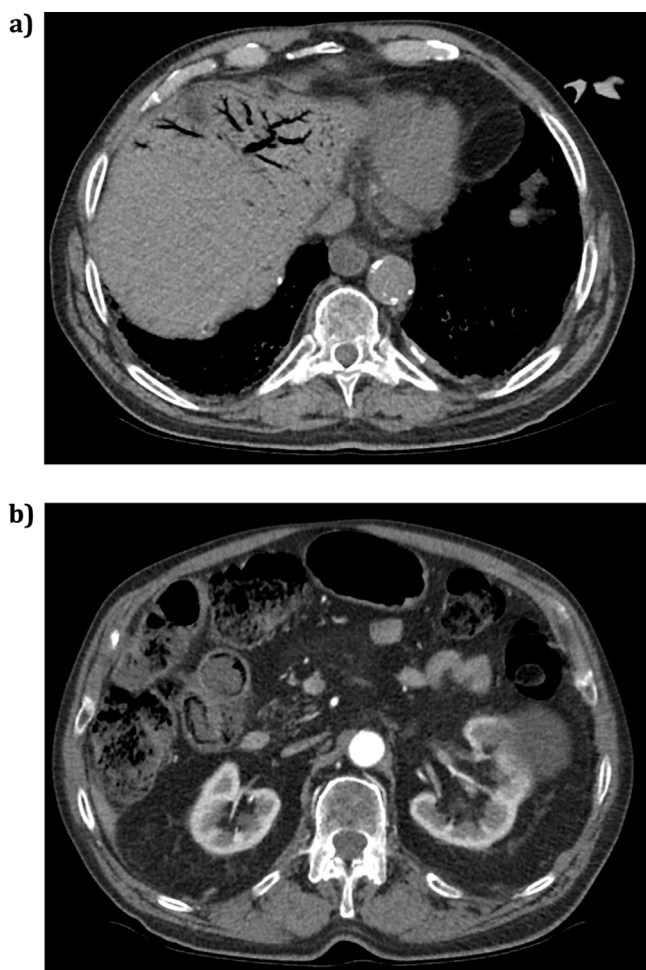
mortality. This document has been reported in line with the CARE criteria [9].

## 2. Case report

A 93 year old man presented with acute abdominal pain which radiated to his back, associated with nausea and vomiting. He had complained of altered bowel habit for 2 weeks prior to admission. He had generalised abdominal tenderness and distension but no features of peritonism. He was afebrile. His blood pressure, pulse and oxygen saturations were all within normal limits. He had a background of type 2 diabetes mellitus, ischaemic heart disease, hypertension, diverticulosis, varicose eczema, deep vein thrombosis for which he was taking warfarin and an extensive smoking history. He had no previous history of abdominal surgery. His WCC (white cell count) was elevated ( $18.1 \times 10^9/L$ ) and his renal function demonstrated acute kidney injury. His liver function and amylase remained normal. His INR was 3.4 and PTT 34.8 s. His arterial blood gas did not demonstrate acidosis and his lactate and bicarbon-

\* Corresponding author.

E-mail addresses: [dr.e.nevins@gmail.com](mailto:dr.e.nevins@gmail.com), [Edward.Nevins@doctors.org.uk](mailto:Edward.Nevins@doctors.org.uk) (E.J. Nevins).



**Fig. 1.** CT images from patient demonstrating (a) hepatic portal venous gas and (b) pneumatosis intestinalis in the terminal ileum.

ate were within normal range. An abdominal x-ray demonstrated dilated loops of small bowel.

To exclude a ruptured abdominal aortic aneurysm, a triple phase CT of his abdomen and pelvis was performed (Fig. 1). This was approximately 2 hours after admission to the emergency department. The CT demonstrated pneumatosis intestinalis in the terminal and distal ileum. The loops demonstrated wall oedema with increased enhancement on the arterial phase with marked surrounding vessel hyperaemia and fat stranding, strongly suggestive of acute small bowel ischaemia. There was also portal venous gas in the left lobe of the liver. The proximal and mid small bowel appeared normal. The coeliac axis, superior mesenteric artery (SMA), and inferior mesenteric artery (IMA) were all patent, but had non-stenotic calcification at their ostia. There was no evidence of mesenteric venous gas or intraperitoneal fluid or free air. The colon was faecally loaded and therefore ischaemic changes within the caecum could not be commented upon. The rest of the intra-abdominal organs appeared normal except for a large left renal cyst.

Due to his co-morbidities and general frailty it was felt that he was unlikely to survive operative intervention. Therefore intravenous antibiotics were initiated for conservative management (piperacillin-tazobactam 4.5 g TDS) along with a nasogastric tube and intravenous fluids. His warfarin was withheld due to bleeding risk, though he was not given a reversal agent. His clinical condition improved following 5 days of IV antibiotics. His warfarin was restarted and he was subsequently discharged from hospital 7 days

after admission, without abdominal pain, and his WCC had returned to normal range. The patient remained alive at the time of writing this article 3 months after the initial presentation.

### 3. Discussion

Due to the more liberal use of CT scanning in modern surgical units, PI and HPVG are increasingly detected [1,2]. Most cases of HPVG are associated with PI and therefore PI and HPVG are likely to represent a spectrum of the same disease, with gas tracking through the portal venous system [1,3].

PI causing HPVG has a poorly understood pathogenesis. Causes can broadly be separated into four categories: infection; mechanical; ischaemic; and iatrogenic. The pathogenesis of the mechanical theory can be explained by high pressures causing gas to track into the mesenteric veins from the intestinal lumen via intestinal endothelial and mucosal breakdown, such as in small bowel obstruction; or due to mucosal breaches in ulcerative disease [3,4]. The bacterial theory is thought to result from fermenting bacteria passing into the submucosa, resulting in PI which tracks into the HPV [3,4]. Ischaemic pathology results in breaches of the mucosal surface and proliferation of gas producing organisms [2]. In ischaemic disease, arterial embolic disease is the most common cause; however low-flow secondary to sepsis, venous thrombosis, vasculitis and arterio-spasm have also been documented [1,8,10]. Iatrogenic causes of portal venous gas include GI luminal instrumentation, vascular cannulation, or pharmacotherapy [2,3].

HPVG associated with PI usually indicates intestinal ischaemia or necrosis and was previously thought to carry an “all-cause” mortality of around 75% [3,5,8,11–13]. However, more recent studies have demonstrated a mortality of less than 40%, though this includes benign and iatrogenic causes of HPVG [11,14,15]. This improvement in mortality may also be at least partially explained by the increased use of CT, or by improved emergency surgical technique and decision making [10]. HPVG in the older patient is even more suggestive of mesenteric ischaemia and is usually a peri-mortem sign, indicating a necessity for emergency surgery [3]. Although early surgical intervention in ischaemic pathology can be lifesaving, it still carries high mortality [1,4–8,10,16]. In extremes of age, and when a patient has extensive co-morbidities, surgery may not be in the patient’s best interest, as the laparotomy may also not be survivable [1]. However, here we have reported a case of mesenteric ischaemia, resulting from impaired arterial flow secondary to sepsis, causing PI and HPVG. The patient was treated conservatively with non-operative management and survived to be discharged from hospital.

It would be beneficial to distinguish accurately between those cases of PI and HPVG that require operative intervention, as an emergency, and those where conservative treatment may be indicated; especially if they are unlikely to survive an operation. Wayne et al. reviewed 88 cases of HPVG or PI, in 86 patients [1]. In their ischaemic series, all patients had extensive cardiovascular risk factors, and lactate levels were normal in approximately 50% of these patients, as with our patient. The authors concluded that lactate, pH, WCC and bicarbonate were poor predictors of ischaemia [1]. Again, like the present patient, there were a large number of patients in their ischaemic subgroup who had both large and small bowel PI, suggesting SMA involvement. All four patients who were managed non-operatively, died during this author’s series [1]. However, our patient has identified that there are a small number of patients who may survive ischaemic pathology without operative intervention using antibiotic therapy. Urokinase and prostaglandin E1 have been suggested as suitable additions to the emergency surgeon’s armoury when dealing with PI and HPVG in ischaemic pathology but they were not used in this case [8,12]. We therefore

Download English Version:

<https://daneshyari.com/en/article/4288432>

Download Persian Version:

<https://daneshyari.com/article/4288432>

[Daneshyari.com](https://daneshyari.com)