

Contents lists available at [ScienceDirect](http://ScienceDirect)

## International Journal of Surgery Case Reports

journal homepage: [www.casereports.com](http://www.casereports.com)

## A rare gallbladder ciliated foregut cyst in chronic cholecystitis

Mee-Jin Lee<sup>a,\*</sup>, James Salinas<sup>a</sup>, Winny Varikatthas<sup>b</sup>, Ghiyath Alsnih<sup>a</sup><sup>a</sup> Department of General Surgery, Blacktown Hospital, Sydney, New South Wales, Australia<sup>b</sup> Department of Pathology, Westmead Hospital, Sydney, New South Wales, Australia

## ARTICLE INFO

## Article history:

Received 10 August 2015

Received in revised form 5 January 2016

Accepted 16 January 2016

Available online 22 January 2016

## Keywords:

General surgery

Surgery

Gallbladder

Cysts

Foregut

Ciliated

## ABSTRACT

**INTRODUCTION:** Ciliated foregut cysts (CFC) are rare anomalies due to aberrant embryological development. It is thought to arise from a remnant of the embryologic foregut. The solitary cysts are characterised by ciliated pseudostratified columnar epithelium. They are usually located above the diaphragm but they can also arise in relation to the liver, gallbladder and pancreas.

**PRESENTATION OF CASE:** We present the first ciliated foregut cyst of the gallbladder case reported in Australia, and the ninth known case to be reported worldwide. A 61-year-old male with chronic cholecystitis and cholelithiasis underwent an elective laparoscopic cholecystectomy and intraoperative cholangiogram. Intraoperatively, 'out-pouching' was noted on the lateral border of the gallbladder. Microscopically the histopathology showed that the cyst was lined by ciliated columnar epithelium the characteristic feature of a ciliated foregut cyst.

**DISCUSSION:** To date only 8 cases of these ciliated foregut cysts in the gallbladder have been reported in literature. Our case is the first reported in Australia. It is unique in that the patient was an older male as opposed to most other previous cases, which were younger females. These cysts can be difficult to distinguish from neoplasms clinically and radiographically. Reports have shown that these cysts may become dysplastic and is best excised when discovered.

**CONCLUSION:** Despite the rarity of CFCs and their potential to mimic malignancy, we propose awareness and understanding of the management for them—being excision and hopefully not cause any confusion or devastatingly allow it to become malignant.

© 2016 The Authors. Published by Elsevier Ltd. on behalf of IJS Publishing Group Ltd. This is an open access article under the CC BY-NC-ND license (<http://creativecommons.org/licenses/by-nc-nd/4.0/>).

## 1. Introduction

Ciliated foregut cysts (CFC) are rare anomalies due to aberrant embryological development. It is thought to arise from a remnant of the embryologic foregut. The solitary cysts are characterised by ciliated pseudostratified columnar epithelium. They are usually located above the diaphragm but they can also arise in relation to the liver, gallbladder and pancreas. We present the first ciliated foregut cyst of the gallbladder case reported in Australia, and the ninth known case to be reported worldwide.

## 2. Presentation

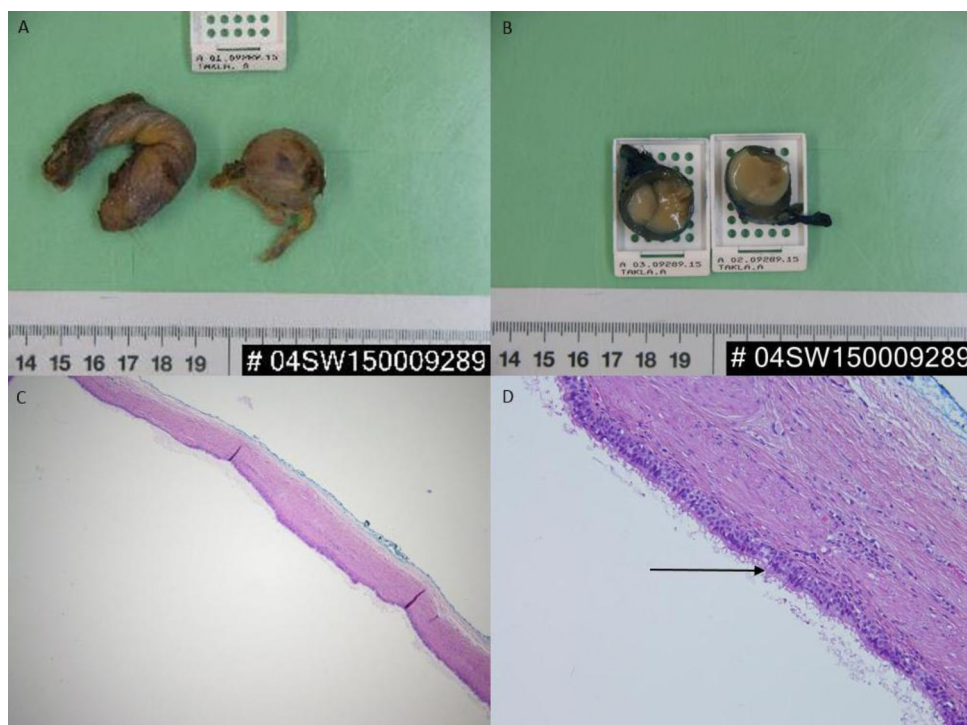
A 61-year old male with right upper quadrant abdominal pain from chronic cholecystitis and cholelithiasis underwent an elective laparoscopic cholecystectomy and routine intraoperative cholangiogram. Intraoperatively, an 'out-pouching' was noted on the lateral border of the gallbladder which was not clearly visible on the preoperative ultrasound. The intraoperative cholangiogram did

not reveal any common bile duct calculi obstructions or abnormal anatomy. While attempting to remove the gallbladder with the use of an *EndoCatch bag*<sup>TM</sup> (Covidien products, Medtronic Ltd., USA) difficulty was encountered due to the large cystic diverticulum. The gallbladder was successfully removed with the commonly used technique of aspirating the bile to deflate the gallbladder via the *EndoCatch*<sup>TM</sup>. The gallbladder tissue was sent to histopathology for routine analysis and the patient was discharged the following day with no post-operative complications.

The macroscopic histopathology reported the gallbladder dimensions to be 85 mm long, 25 mm across (Fig. 1). The serosa was smooth and the wall between 2–3 mm thick. The mucosa was smooth with no obvious solid lesions or lymph nodes identified. Up to 4 pigmented black stones measuring 1 mm in maximum dimension each were seen in the lumen. Microscopically, sections from the gallbladder showed chronic cholecystitis with occasional Rokitansky–Aschoff sinuses and mild chronic inflammation. No evidence of atypia or malignancy was seen.

Separately submitted was a well-demarcated smoothly encapsulated cyst measuring 27 mm in diameter. On sectioning the cyst wall was 1 mm thick uniformly and contained a soft gelatinous material without papillary excrescences. Microscopically the cyst was lined by ciliated columnar epithelium and supported by fibrous

\* Corresponding author. Fax: +61 2 9881 7478.  
E-mail address: [meejin@yahoo.com](mailto:meejin@yahoo.com) (M.-J. Lee).



**Fig. 1.** Illustration of macroscopic and microscopic gallbladder CFC. (A) Macroscopic view of gallbladder and CFC specimen. (B) Macroscopic view of CFC dissection. (C) Low power view of the ciliated columnar cells (H&E, original magnification is 40 $\times$ ). (D) High power view of the ciliated columnar cells (H&E, original magnification is 200 $\times$ ).

connective tissue. No significant inflammation of the wall was seen. No evidence of atypia or malignancy was appreciated. The features were reported to be consistent with a CFC of the gallbladder.

All work has been reported in line with the CARE criteria [1].

### 3. Discussion

We present the first CFC of the gallbladder case reported in Australia, and the ninth known case to be reported worldwide (PubMed<sup>TM</sup>, MEDLINE<sup>TM</sup>). Gallbladder cysts are rare. Out of the three classes of cysts, acquired, neoplastic and congenital [2], the CFCs, which are congenital cysts arising from the embryological foregut, are extremely rare. CFCs are usually found above the diaphragm as a cyst on the bronchi or esophagus [3]. Below the diaphragm, they usually present on the liver, known as ciliated hepatic foregut cysts (CHFC) [4]. While the precise molecular mechanism for CFCs are not understood, it is hypothesized that the aberrant congenital ciliated cysts in the liver, gallbladder and pancreas are due to the induction of a faulty selective cellular differentiation [5,6].

To date only 8 cases of these ciliated foregut cysts in the gallbladder have been reported in literature (Table 1). In 1995, the first description of this cyst, a single layer of ciliated columnar epithelial layer with a fibro-muscular wall was coined “epithelial cyst of the gallbladder [7].” In the following year, one out of the 4 patients with ciliated hepatic cysts had CFC on the gallbladder [8]. In 2000, Nam et al. were the first to term this anomaly a “ciliated foregut cyst of the gallbladder [9].” Hirono et al. and Muraoka et al. then reported 2 additional cases in 2002 and 2003 [10,11]. In 2010 Bulut and Karayalçın presented the 6th case of CFC in the gallbladder [12]. In this paper it was noted that as with previous cases, the patients were mostly young women with unilocular cysts. The walls were smooth muscles and lined by a ciliated pseudostratified epithelium. They were located under the mucosa and did not communicate

with the lumen. The cysts contained mucinous or thick fluids. In 2013, a CFC measuring 7 mm was the smallest to be reported [13]. The most recent case published was in 2014, the histological findings consistent with previous expect for an unusual presence of a tiny 0.5 mm focus of salivary gland type acini within the wall [14]. There was reported only one case of a CHFC communicating with the gallbladder [15].

Ultrasound is an efficient method of imaging for hepatobiliary masses. For CFCs in the gallbladder (see Table 1), the ultrasound was the main imaging modality and was anechoic in most cases. It has been shown that some hypo-anechoic lesions can have highly echogenic areas as was in 2 of the cases and in hepatic CFCs [11,13,16]. This may be confused with malignant tumors. In our particular case, an ultrasound was performed 2 months prior to the operation that showed gallstones with nil reports of the cyst. A “comet-tail” form of echogenicity has been discussed in literature as a feature of cysts [11]. This is from Rokintansky–Aschoff sinuses [17]. Two cases in literature used Doppler imaging. In Hirata et al.’s investigations, there was no Doppler activity [18] but in Tuncyurek et al.’s study there was Doppler currents detected on the wall of the cyst [13]. Therefore Dopplers may not assist in differentiating CFC presence. CFCs are not always associated with gallstones [13,14]. The absence of acoustic shadows or echogenicity from other calcifications can help to narrow down the diagnosis.

Masses with dimensions less than 1 cm are difficult to diagnose in CT or MRI. Out of the 8 previous cysts reported only 2 used other imaging modality aside from US and in both cases were greater than 1 cm [14]. Muraoka visualised a protruding lesion with slight enhancement in the gallbladder on CT and CTA after US visualisation. Angiography provided no additional information, however, sequential CT-arteriography (CTA) clearly demonstrated that this tumour was a cystic lesion [11]. Giakoustidis et al. [14] showed that while US showed the cyst to be located in the hepatic region, an endoscopic US showed that there was no cyst in the liver or

Download English Version:

<https://daneshyari.com/en/article/4288579>

Download Persian Version:

<https://daneshyari.com/article/4288579>

[Daneshyari.com](https://daneshyari.com)