



Contents lists available at ScienceDirect

## International Journal of Surgery Case Reports

journal homepage: [www.casereports.com](http://www.casereports.com)

## Pseudo subclavian steal syndrome: Case report



Sneha Konda, Samantha Dayawansa\*, Soren Singel, Jason H. Huang

Department of Neurosurgery, Baylor Scott and White Health Care, Temple, TX 76508, USA

## ARTICLE INFO

## Article history:

Received 21 April 2015

Received in revised form

21 September 2015

Accepted 22 September 2015

Available online 28 September 2015

## Keywords:

Persistent trigeminal artery

Carotid atherosclerosis

Syncope attacks

## ABSTRACT

**INTRODUCTION:** Vertebrobasilar insufficiency (VBI) is a condition that results from restricted blood flow to the posterior portions of the brain, which are primarily served by the vertebral and basilar arteries. It is the most common cause of vertigo in the elderly and is usually accompanied by impaired vision and sensation. Congenital abnormalities, atherosclerosis, stroke and/or trauma may all lead to decreased vertebrobasilar circulation. A syndrome called Subclavian Steal Syndrome (SSS), which manifests with similar neurological symptoms but with a different pathophysiology, may also cause VBI.

**CASE PRESENTATION:** A middle-aged female presented with gradual onset fainting and vertigo attacks. Cardiac, auditory and autonomic etiologies were investigated and excluded. Clinical findings and presentation were highly suggestive of subclavian steal. However, subsequent CT angiography showed normal subclavian arteries. Instead, findings included a persistent right trigeminal artery (PTA), stenosis of the right proximal internal carotid artery, atresia of the left vertebral artery and distal segment of right vertebral artery, congenitally compromised changes in vertebral circulation (bilateral absence of the posterior communicating arteries (PCOMs)) and an absent anterograde vertebrobasilar circulation. Symptoms resolved after carotid endarterectomy.

**DISCUSSION:** Due to the absence of a normally developed posterior circulation, the PTA was the main source of blood supply for the patient. Development of recent arteromatous changes in the right internal carotid artery, however, resulted in decreased blood through PTA, further compromising posterior circulation. This resulted in vertebrobasilar insufficiency, and manifested in symptomatology similar to SSS.

**CONCLUSIONS:** This clinical encounter illustrates the relative contribution of anatomical and vasoocclusive factors in closely mimicking symptoms of subclavian steal syndrome.

© 2015 The Authors. Published by Elsevier Ltd. on behalf of Surgical Associates Ltd. This is an open access article under the CC BY-NC-ND license (<http://creativecommons.org/licenses/by-nc-nd/4.0/>).

## 1. Introduction

Subclavian steal syndrome (SSS) is a relatively rare phenomenon that usually presents in patients 55 years or older, more frequently in Caucasians due to increased incidence of atherosclerosis. It has a 2:1 male to female ratio, and is characterized primarily by the occlusion of the subclavian artery proximal to the origin of the vertebral artery. Typical clinical findings of SSS are a difference of more than 20 mm Hg in blood pressure between two arms, unilaterally decreased pulses, supraclavicular bruits, and absence of radial pulse during exercise of affected extremity. Ultrasound, MRI or angiography confirms diagnosis. Surgical intervention is required for symptomatic patients after critical evaluation of complete hemodynamic situation, and aims at restoring antegrade vertebral artery flow, alleviating cerebral hypoperfusion and improvement of arterial perfusion in upper arm. In addition, aggressive management and modification of risk factors, namely control of hypertension,

diabetes, hypocholesterolemia, and tobacco use, is essential in optimal treatment algorithm for this syndrome [1,2].

Underlying pathophysiology is a build up of a negative pressure gradient between the vertebral-basilar and vertebral-subclavian artery junctions, resulting in altered vascular hemodynamics. Blood flows in the retrograde direction in the ipsilateral vertebral artery toward the upper arm, distal to stenosed subclavian artery, effectively stealing blood away from vertebrobasilar circulation (Fig. 1). This syndrome is usually asymptomatic due to abundant collateral circulation in head and neck region, and is usually discovered incidentally in ultrasound or angiography. It may also be prompted by clinical findings such as unilateral upper limb pulse and blood pressure [3].

Decreased blood flow to the brain and affected upper extremity can result in a diverse gamut of symptoms, but can be generally categorized into two main broad categories: (1) Vertebrobasilar insufficiency, (2) Ischemia of the affected extremity. Vertebrobasilar insufficiency results if too much blood is diverted away from intracranial structures. Posterior cerebral circulation is particularly compromised. Collateral circulation to the posterior fossa is primarily through the circle of Willis, principally through the posterior

\* Corresponding author.

E-mail address: [sdayawansa@sw.org](mailto:sdayawansa@sw.org) (S. Dayawansa).

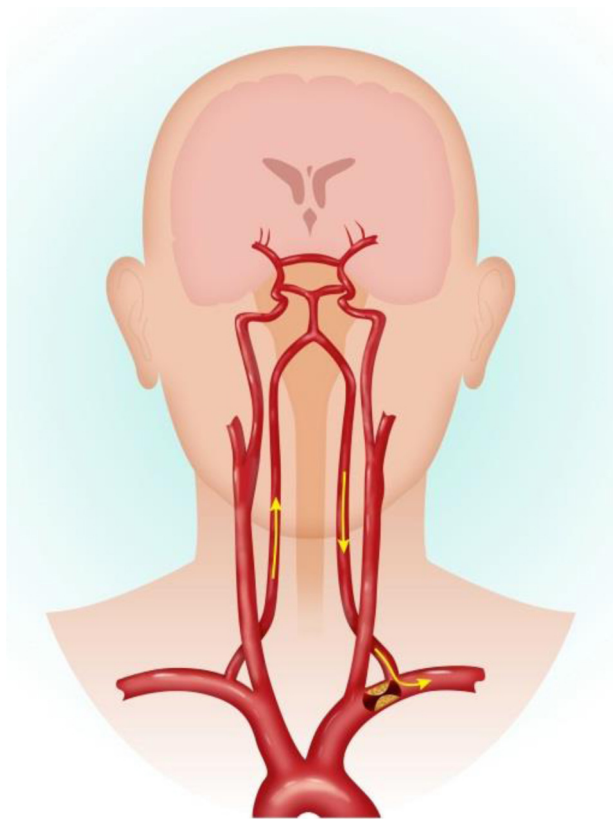


Fig. 1. Pathology of subclavian steal syndrome.

communicating artery. Compromise of this circulation, frequently due to concurrent extracranial carotid stenosis, leads to vertebrobasilar symptomatology. Syncope, vertigo, ataxia, seizures and confusion comprise the constellation of symptoms that may result in this situation. Ischemia of the affected extremity is less common and symptomatology includes weakness or arm claudication after exercise, paresthesias, or temperature changes on affected side. Both classes of symptoms are particular manifest and classically reproducible when patient acquires certain body postures that increase circulatory demand from distal subclavian artery or the brachial artery of the upper limb [4,5].

SSS has a wide range of clinical manifestations, and although less common, any compromise of the posterior cerebral circulation can give rise to similar signs and symptoms, as highlighted in this particular case. It is therefore paramount that the clinician be vigilant and informed of such presentations to avoid its morbidity and potential for mortality if misdiagnosed.

## 2. Case report

A thirty nine year old female presented with gradual onset “usually” postural syncope and vertigo episodes. According to the patient, her likelihood of having a vertigo attack or syncope was greater when suddenly rising from a seated or spine position. Milder and less conspicuous spontaneous episodes would also manifest in certain upper limb positions e.g., sudden lifting of her right arm and prolonged manual work involving the right arm, the latter of which became more evident recently.

Patient did not experience any chest pain, palpitations or signs and symptoms of epilepsy prior to or following these syncope episodes. She regained consciousness from these episodes in few seconds without any urinary or fecal incontinence. She did not have

any auditory difficulties, tinnitus, ear infections, or trauma, all of which can be normally attributed to this clinical presentation.

When initially presented to the clinic, routine tests were performed and results excluded cardiac pathologies, medications, autonomic pathologies, or auditory pathologies. EEGs and other neurologic physical examinations were also normal. When directed to the vascular clinic, a diagnosis of subclavian steal syndrome was high on the clinician’s list of differential diagnoses. However, no blood pressure differential between arms or vascular pathology in hands was noted, both clinical features of which are normally seen in patients with subclavian steal syndrome.

Subsequent CTA angiography showed normal subclavian arteries, ruling out SSS entirely. Abnormal findings included a persistent right trigeminal artery, atresia of the left vertebral artery and distal segment of right vertebral artery, and bilateral absence of the posterior communicating arteries (PCOMs). A significant anterograde vertebrobasilar circulation was absent. The right internal carotid artery (ICA) had atherosclerotic plaque with 75% narrowing of the lumen. Patient was asymptomatic after undergoing a carotid endarterectomy.

## 3. Discussion

In a healthy adult, two vertebral arteries form the basilar artery, which connects to the anterior circulation through bilateral posterior communicating arteries, comprising the Circle of Willis. In ideal circumstances, the posterior cerebral circulation is maintained with little anterior contribution. However in vascular pathologies in which a cerebral artery is occluded, the Circle of Willis interconnects anterior and posterior circulation allowing collateral blood circulation to target tissues of occluded vasculature to avoid ischemia.

One such pathology that prompts a direct communication between anterior and posterior circulation is the subclavian steal syndrome (SSS). In SSS, the proximal subclavian artery is stenosed, compromising blood flow. As a result, blood travels through ipsilateral vertebral artery to basilar artery, around Circle of Willis, and descends through contralateral vertebral artery to supply affected upper limb [6]. Affected upper limb is supplied by blood flowing down the vertebral artery at the expense of vertebrobasilar circulation, resulting in symptoms such as syncope, vertigo, and neurologic deficits [7]. Patient presented to clinic with similar symptoms, namely syncope and vertigo, with unremarkable cardiac and neurologic physical examinations, prompting a possible diagnosis of SSS. However, no circulatory differences were noted between upper extremities and CT angiography excluded subclavian steal syndrome altogether. CT angiography findings further elucidated medical mystery: atresia of patient’s left vertebral artery, absent posterior communicating arteries due to bilateral fetal posterior cerebral artery (PCA) configuration, and absent distal segments of right vertebral artery (VA) [8]. Patient’s right vertebral artery (VA) ended in the posterior inferior cerebellar artery (PICA). Patient’s vascular configuration resulted in posterior blood supply being almost entirely dependent on anterior circulation through patient’s persistent trigeminal artery (PTA). However, PTA was compromised due to high-grade proximal right internal carotid artery stenosis, resulting in vertebrobasilar insufficiency, manifesting in patient’s neurological symptoms. This particular type of PTA—with an ill-developed basilar artery and absent posterior communicating arteries—has a designated classification of Saltzman type II [9]. An artist’s rendition of patient’s circulation is shown in Fig. 2.

Vertebrobasilar insufficiency, in which blood flow to the vertebral and basilar arteries is inadequate leading to compromised posterior cerebral circulation, can be caused by a variety of factors

Download English Version:

<https://daneshyari.com/en/article/4288656>

Download Persian Version:

<https://daneshyari.com/article/4288656>

[Daneshyari.com](https://daneshyari.com)