



Contents lists available at ScienceDirect

International Journal of Surgery Case Reports

journal homepage: www.casereports.com

Malignant melanoma revealed by testicular metastasi.

Marie Dusaud^{a,*}, Lucille Adjadj^b, Alexandre Debelmas^c, Jean Baptiste Souraud^d, Xavier Durand^a^a Department of Urology, Hôpital d'Instruction des Armées Val-de-Grâce, 74 boulevard de Port Royal, 75005 Paris, France^b Department of Plastic and reconstructive surgery, Hôpital Européen George Pompidou, 20 rue Leblanc, 75015 Paris, France^c Department of maxillo-facial surgery, Hôpital Saint Louis, 1 avenue Claude Vellefaux, 75010 Paris, France^d Department of Pathology, Hôpital d'Instruction des Armées Bégin, 69 avenue de Paris, 94160 Saint-Mandé, France

ARTICLE INFO

Article history:

Received 15 February 2015

Received in revised form 13 May 2015

Accepted 14 May 2015

Available online 21 May 2015

Keywords:

Testicular tumor

Metastasis

Melanoma

Elderly

ABSTRACT

We report the case of an 83 years old man supported for painless indurated and nodular lesion of the left testicle. Histological analysis identified a primary cutaneous melanoma metastasis although it has never been found on physical examination.

The discovery of a testicular mass should suggest first a germ cell tumor, despite in some populations (age over 60 years), other diagnosis are more frequent, including metastasis.

Due to rapid disease progression and high mortality rate within a short interval, a complete staging looking for other secondary locations must be done and a multidisciplinary care and palliative involvement must also be initiated in the context of metastatic melanoma.

© 2015 Published by Elsevier Ltd. on behalf of Surgical Associates Ltd. This is an open access article under the CC BY-NC-ND license (<http://creativecommons.org/licenses/by-nc-nd/4.0/>).

1. Introduction

Cutaneous malignant melanoma diagnosed by a testicular metastasis is uncommon.

Although germ cell tumors are the most frequent tumors in men after age 65 other diagnostics should be mentioned as lymphoma and melanoma. We report the case of an 83 years old man with a testicular mass revealing a metastatic melanoma.

2. Case report

An 83 years old man was seen for a mild but rapidly evolving deterioration of his general state, associated with a testicular tumefaction. He had a body mass index of 19.3 kg/m² and a loss of 14 kg from is usual weight. His WHO performance status was 2–4. Physical examination before surgery did not show any skin lesion but only bilateral superficial inguinal lymphadenopathies.

The scrotal ultrasound revealed a hypoechoic, heterogeneous, well-limited nodule, measuring 14 per 20 mm, with a central and peripheral hypervascularization on the Doppler, associated with multiple bilateral nodules in the subcutaneous tissue of the scrotum.

* Corresponding author. Tel.: +33 140514324; fax: +33 140514154.

E-mail addresses: marie.dusaud@gmail.fr (M. Dusaud), docteur.adjadj@gmail.com (L. Adjadj), alexandre.debelmas@hotmail.fr (A. Debelmas), jsouraud@hotmail.com (J.B. Souraud), xavier.durand.urovdg@orange.fr (X. Durand).

A total left orchidectomy with testicular prosthesis replacement using an inguinal approach was performed, for a diagnostic purpose.

The surgical approach was responsible for the incidental finding of a subcutaneous necrotic left inguinal nodule, highly friable, measuring 2 cm.

Macroscopic analysis of the resected specimen showed an indurated, brown nodule of 2.2 cm long in its greater axis, strongly evocative of a testicular melanoma (Fig. 1).

Microscopic analysis showed cells arranged in clusters, without specific tissue architecture, with a dark brown intracytoplasmic pigment, a megakaryocytosis, a high mitotic index, and an important infiltration of the underlying fatty tissue (Fig. 2).

The immuno-histological profile confirmed a testicular melanoma metastasis (Fig. 3). The search of BRAF mutation was negative.

After surgery, the patient had many subcutaneous nodules appearing on the whole body and cervical, axillary and inguinal lymphadenopathies.

A thoracic abdominal and pelvic CT-scan, realized postoperatively, revealed nodules suggestive of metastasis in lungs, soft tissues, hepatic fundus, adrenal glands, anterior mediastinum, thyroid gland, pericardium, and an osteolytic lesion of the third lumbar vertebra (Fig. 4). These locations are not usual secondary locations for germ cells tumors.

In this context of multi metastatic melanoma, a cerebral MRI was performed. It revealed diffuse supra and infratentorial lesion of the brain, including one in the third ventricle, without impact on the ventricular system (Fig. 5).



Fig. 1. Macroscopic view of the testicular specimen. Melanoma appears in dark blue.

A per os chemotherapy containing temozolomide was administered, only 3 doses in 5 days because of the poor tolerance with increased confusion.

Because of the confusion, a lumbar puncture was performed and demonstrated meningeal carcinomatosis.

The patient received a palliative care because of the increase of confusion and major deterioration of the general state.

The patient died of a status epilepticus caused by cerebral metastasis a little less than 2 months after the orchidectomy.

3. Discussion

Melanoma affects people of all ages. Its occurrence is very rare before puberty. Its incidence doubles every 10 years (especially in countries where the sun exposure is important and where the population is mainly Caucasian). Its death rate is 1.7 for 100,000 for men in France in 2011 [1].

Testicular tumors affect mainly young adults and are generally germ cells tumors. However, after age 60, epidemiological data are different, though their clinical presentations remain the same (occurring under the form of a nodule or a painful testicular mass) [2].

The diagnosis of skin melanoma is mainly clinical, with the use of a dermatoscope. It is usually an incidental diagnosis, rarely established on clinical signs (such as morphological modifications of a nevi, or alteration of the general state).

The most commonly used prognostic histological score is the Breslow index (thickness of the tumor, measured on the specimen, between the stratum granulosum and the deepest layer of the tumor), and Clark index (the degree of invasion of tumoral cells in the dermo-hypodermic layers, its value is less important than the Breslow index). The ulceration and mitotic index are also highly predictive elements [3].

Its extension work up depends on the causal lesion, the lymphatic drainage zone ultrasounds assessment is optional and every other paraclinical examination depends on clinical calling-in points. The histopathological examination and extension work up for the staging of the cancer follow the UICC/AJCC classification.

A life-long follow up will be ensured, its frequency depending on the seriousness of the initial lesion [4].

According to the French Urologic Lesions Study Group (GELU) concerning 2215 testicular tumors diagnosed in 13 French centers, the most commonly encountered malignant testicular tumors histological types after age 60 are, in order of frequency: blood disease (31.92%), germ cells tumors (18.78%), Leydig cells tumors (9.86%), metastasis (9.39%), benign mesenchymal tumors

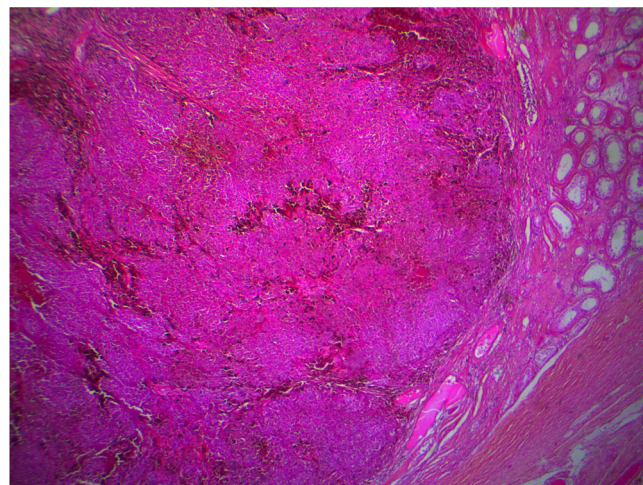


Fig. 2. Microscopic view, nodular tumor, poorly circumscribed, composed of nests of cells with frequent clusters of brown pigment (dark arrow). Testicular parenchyma is visible on the periphery (blue arrow). Magnification x25, HES stain.

(7.98%), sarcomas (7.51%), adenomatoid tumors (3.29%), spermatocytic seminomas (1.88%), epidermal cysts (1.41%) and other types (7.98%).

Testicular metastasis is rarely symptomatic of an unrecognized cancer (less than 15%) [5,6].

A testicular mass after age 65 has to evoke a secondary lesion, even though lymphoma remains the most frequent diagnosis.

There are other symptoms evoking a testicular melanoma, such as: absence of elevation of tumor markers, presence of melanospermia, presence of a supraclavicular lymphadenopathy, and personal history of skin primitive melanoma [7].

Life expectancy of patients having a testicular metastasis is very low, because of the advanced stage of tumoral spreading [8].

The main differential diagnoses in males after age 65 are: diffuse large B cells lymphoma (CD20+), germ cells tumors and Leydig cells tumors.

There are various ways of spreading for testicular metastasis: retrograde venous way, arterial embolism, lymphatic route, or by contiguity with the primary lesion.

It is also possible for the lesion to regress and to make way for a systemic dissemination, like in the present case, though this event is very rare.

The diagnostic approach is to identify before treating the primitive lesion. However, if the lesion remains unidentified, and since there is no more easily accessible metastatic lesion, the diagnostic process consists in radical orchidectomy through inguinal approach after high spermatic cord ligation, followed by histopathologic examination.

Some histological elements can lead to suspect a testicular metastasis [9]:

- morphological aspect that does not evoke a primitive testicular tumor
- predominant interstitial infiltration sparing the seminiferous ducts
- numerous lymphatic and vascular emboli in the testis, epididymis and spermatic cord.
- misleading signs: predominant intratubular extension mimicking intratubular germ cell neoplasia (27% of cases) invading the rete testis.

Histologic examination succeeds in a great majority of cases in identifying the primitive tumor and in eliminating differential diagnoses. Specific immunohistochemical markers of melanoma are: PS100, Melan A, HMB45.

According to the GELU study, cancers metastasizing in testicles are, in order of frequency: prostate adenocarcinomas (30–65%),

Download English Version:

<https://daneshyari.com/en/article/4288695>

Download Persian Version:

<https://daneshyari.com/article/4288695>

[Daneshyari.com](https://daneshyari.com)