

Perianal pyoderma gangrenosum after excision and fulguration of anal condyloma acuminatum

Jennifer L. Agnew^{a,*}, Paul D. Strombom^a, Carmen F. Fong^a, Timothy J. Kelly^a, Joseph E. Martz^b

^a Mount Sinai Beth Israel, Department of Surgery, First Avenue at 16th Street, New York, NY 10003, USA

^b Mount Sinai Beth Israel, Division of Colorectal Surgery, First Avenue at 16th Street, New York, NY 10003, USA

ARTICLE INFO

Article history:

Received 26 August 2015

Accepted 8 October 2015

Available online 23 October 2015

Keywords:

Pyoderma gangrenosum

Postoperative wound

Anorectal surgery

ABSTRACT

INTRODUCTION: Pyoderma gangrenosum (PG) is a rare, inflammatory skin pathology frequently associated with systemic inflammatory disease. While rare after surgery, recognition of this disease in the post-surgical setting is important as it can mimic wound infection.

PRESENTATION OF CASE: We herein present a dramatic presentation of perianal PG four days after routine excision and fulguration of anal condyloma acuminatum. The affected area did not improve with broad spectrum antibiotics or surgical debridement. A diagnosis of PG was made from clinical suspicion and pathology findings, and further confirmed with rapid improvement after starting steroids. Diagnosis of this disease in the postoperative period requires high suspicion when the characteristic ulcerative or bullae lesions are seen diffusely and show minimal improvement with antibiotic treatment or debridement.

DISCUSSION: Our case highlights the importance of recognizing this disease in the post-operative period, to allow for early initiation of appropriate treatment and prevent unnecessary surgical debridement of a highly sensitive area. There have been 32 case reports of PG in the colorectal literature, mostly following stoma creation. There is one case report of idiopathic perianal pyoderma gangrenosum with no known prior trauma. To our knowledge there are no previously reported cases of perianal PG after routine elective anorectal surgery.

CONCLUSION: This is the first reported case of perianal pyoderma gangrenosum in the post-surgical setting. Increased awareness of pyoderma gangrenosum in the surgical literature will aid in prompt diagnosis and proper medical management of this uncommon postoperative morbidity.

© 2015 The Authors. Published by Elsevier Ltd. on behalf of IJS Publishing Group Ltd. This is an open access article under the CC BY-NC-ND license (<http://creativecommons.org/licenses/by-nc-nd/4.0/>).

1. Introduction

Pyoderma gangrenosum (PG) is a rare inflammatory dermatologic condition leading to skin ulceration, pustules or bullae. PG has a reported incidence of 3–10 million cases per year, with nearly half of the cases associated with an underlying systemic disease, such as inflammatory bowel disease, hematologic conditions and autoimmune disorders [1]. Though the etiology and pathogenesis is not well understood, the most accepted theory involves immunologic pathways and improperly functioning neutrophils. This hypothesis is supported by the clinical improvement of the condition with corticosteroids and immunosuppressive therapies [1]. Major and minor trauma is also believed to play a role, and has led to recog-

nition of cases of postsurgical pyoderma gangrenosum (PSPG) [2]. Within the colorectal literature, the majority of cases are noted in patients with underlying inflammatory bowel disease (IBD) undergoing abdominal surgical procedures. Here we describe the first reported case of perianal PSPG after an anorectal surgical procedure.

2. Presentation of case

A 41-year-old Caucasian male who has sex with men presented to colorectal surgery for outpatient evaluation of anal warts. The patient reported a history of anal herpes simplex virus treated with oral valacyclovir, as well as anal warts treated with exam under anesthesia at an outside hospital 1.5 years prior to current presentation. During preoperative evaluation for his prior procedure, the patient was noted to be anemic and was diagnosed with myelodysplastic syndrome for which he completed a course of oral prednisone. The patient now reported recurrent anal warts associated with pain, itching and discomfort. Clinical exam revealed several wart-like

* Corresponding author.

E-mail addresses: jenniferagnewMD@gmail.com (J.L. Agnew), pstrombom@chpnet.org (P.D. Strombom), cfong@chpnet.org (C.F. Fong), tikelly@chpnet.org (T.J. Kelly), jmartz@chpnet.org (J.E. Martz).

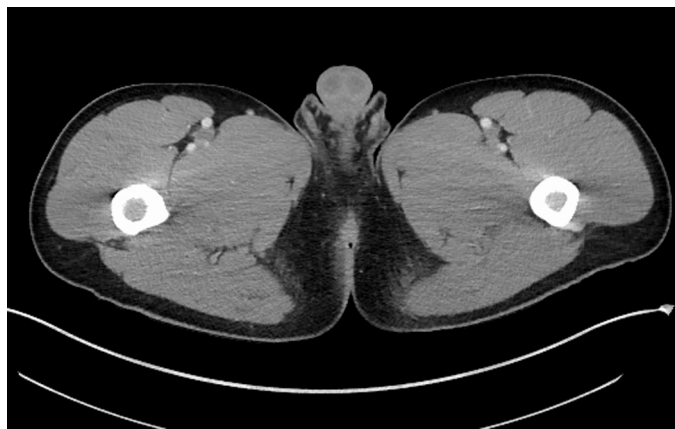

Fig. 1. Initial computed tomography of the pelvis revealing mild inflammation of the perianal skin and tissue surrounding the rectum.

growths in the anal canal. The patient underwent an uneventful ambulatory examination under anesthesia with excision and fulguration of the anal canal lesions. Final surgical pathology reported condyloma acuminatum.

Four days after the ambulatory procedure, the patient returned to the office complaining of severe right-sided perianal pain radiating to the groin, with subjective fever and chills. On exam, the patient was afebrile, with low-grade tachycardia but normotensive. His abdomen was soft and without tenderness or distension. The perianal area showed moderate edema and minimal erythema with tenderness to palpation, but without fluctuance, purulence or crepitus. Laboratory studies revealed a leukocytosis of 15,000 cell/mcL (92% neutrophils). Computed tomography (CT) of the pelvis ruled out deep abscess or collection, but was remarkable for mild inflammation of the perianal skin and tissue surrounding the rectum (Fig. 1). The patient was admitted to the hospital for pain control and antibiotic therapy (ciprofloxacin and metronidazole). Clinical impression at that time was concerning for an infectious process with associated postoperative inflammatory reaction or altered immune response secondary to the patient's underlying comorbidity of myelodysplastic syndrome.

Over the following three days, the patient was observed in the hospital wards while on intravenous antibiotics. While his perianal clinical exam did not change, the patient began to experience febrile episodes as high at 104°F (40°C) and his leukocytosis persisted. By the fourth hospital day, on clinical exam the patient had developed significant bilateral perianal ecchymoses and perianal edema with increased tenderness to palpation (Fig. 2A). CT of the pelvis was repeated and only remarkable for increased circumferential perianal inflammation and edema without any appreciable

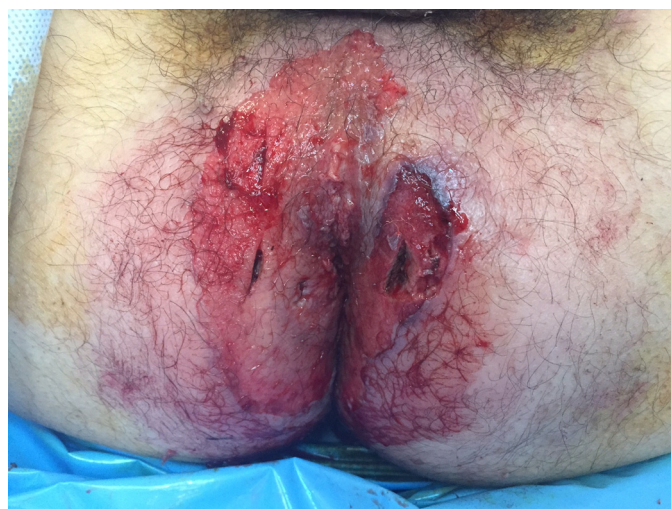

Fig. 3. Intraoperative photograph after superficial debridement and tissue biopsy.

underlying abscess (Fig. 2B). Given the worsening clinical exam findings, the patient was consented and taken to the operating room for exam under anesthesia and debridement. In the operating room he was found to have severe perianal inflammation and induration, proctitis, and desquamation of the perianal skin and anal canal. Only superficial epidermal debridement was necessary to encounter viable tissue (Fig. 3). Tissue biopsies were taken and cultures were sent. An infectious disease consultation was obtained and the antibiotic regimen was broadened to cefepime, doxycycline, metronidazole, and vancomycin in order to cover methicillin-resistant staphylococcus aureus, streptococcus, enterococcus, gonorrhea, and Chlamydia. Valacyclovir was also added to cover herpes simplex virus.

Over the following two postoperative days, his clinical exam again worsened with development of ecchymoses and bullae formation where he had previously been debrided (Fig. 4). Given the poor response to antibiotics and debridement, a dermatology consult was obtained with concern for an underlying autoimmune inflammatory process. Dermatological assessment was clinically most consistent with pyoderma gangrenosum. Clinical signs of pathergy were noted, including the worsening of the clinical exam after further trauma to the area after debridement. Intravenous methylprednisolone 125 mg daily was initiated.

Surgical pathology of the tissue biopsies revealed denuded epidermis with ulcer bed and diffuse, exudative infiltrate of neutrophils extending into subcutaneous fat, with fibrin thrombi, suppurative folliculitis and neutrophilic eccrine hidradenitis. The

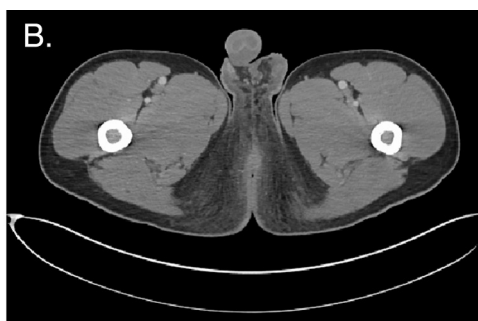
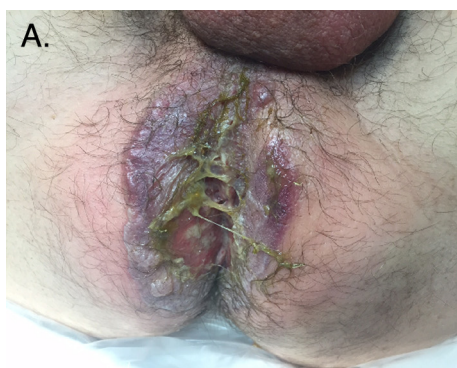

Fig. 2. (A) Initial clinical manifestation consisting of bilateral perianal ecchymoses and perianal edema, which developed on postoperative day 7; (B) computed tomography of the pelvis repeated on postoperative day 7 revealing increased circumferential perianal inflammation and edema without abscess formation.

Download English Version:

<https://daneshyari.com/en/article/4288861>

Download Persian Version:

<https://daneshyari.com/article/4288861>

[Daneshyari.com](https://daneshyari.com)