



Contents lists available at ScienceDirect

International Journal of Surgery Case Reports

journal homepage: www.casereports.com

Craniotomy for cerebellar hemangioblastoma excision in a patient with von Hippel–Lindau disease complicated by uncontrolled hypertension due to pheochromocytoma



Yoshifumi Mizobuchi*, Teruyoshi Kageji, Yamaguchi Tadashi, Shinji Nagahiro

Department of Neurosurgery, Institute of Health Biosciences, The University of Tokushima Graduate School, Tokushima, 3-18-15, Kuramoto-cho, Tokushima 770-8503, Japan

ARTICLE INFO

Article history:

Received 15 October 2015

Accepted 30 October 2015

Available online 4 November 2015

Keywords:

Von Hippel–Lindau disease

Hemangioblastoma

Pheochromocytoma

ABSTRACT

INTRODUCTION: This report describes a patient with Von Hippel–Lindau (VHL) syndrome and uncontrolled hypertension due to pheochromocytoma who underwent craniotomy for the excision of a cerebellar hemangioblastoma combined with a laparoscopic adrenalectomy.

CASE REPORT: A 31-year-old man presented with severe headache. MRI showed areas of abnormal enhancement in the left cerebellum that were determined to be hemangioblastoma with mass effect and obstructive hydrocephalus. His blood pressure rose abruptly and could not be controlled. CT of the abdomen revealed bilateral suprarenal tumors, and the patient was diagnosed as having VHL syndrome. On the third day, he presented with increasing headache, a decreased level of consciousness, and hemiparesis. We were not able to perform a craniotomy because abdominal compression in the prone or sitting position resulted in severe hypertension. We performed ventricular drainage to control his ICP. On the fifth day, we first performed a bilateral laparoscopic adrenalectomy to control ICP and then moved the patient to the prone position before performing a craniotomy to remove the left cerebellar hemangioblastoma.

DISCUSSION & conclusion In patients with pheochromocytoma, the effects of catecholamine over-secretion can cause significant perioperative morbidity and mortality, but these can be prevented by appropriate preoperative medical management. When carrying out an excision of cerebellar hemangioblastomas in patients with intracranial hypertension complicated by abnormal hypertension due to pheochromocytoma whose blood pressure is not sufficiently controlled, tumor resection of the pheochromocytoma prior to cerebellar hemangioblastoma excision in the same surgery may prevent increased ICP and reduce perioperative risk.

© 2015 The Authors. Published by Elsevier Ltd. on behalf of IJS Publishing Group Ltd. This is an open access article under the CC BY-NC-ND license (<http://creativecommons.org/licenses/by-nc-nd/4.0/>).

1. Introduction

Von Hippel–Lindau syndrome (VHL) is an autosomal, dominant, inherited familial cancer syndrome characterized by retinal and central nervous system (CNS) hemangioblastomas and cysts or tumors of the kidneys, adrenal glands, pancreas, epididymis, and endolymphatic sacs [1–3]. For patients with VHL who have confirmed or possible pheochromocytomas requiring resection of CNS tumors, preoperative alpha- and beta-adrenergic blockade is recommended to reduce the risk of perioperative hypertensive crisis [4]. However, there are no clear treatment guidelines for the excision of cerebellar hemangioblastomas in patients with intracranial hypertension complicated by abnormal hypertension due to

pheochromocytoma whose blood pressure is not sufficiently controlled before surgery.

This report describes a patient with VHL syndrome and uncontrolled hypertension due to pheochromocytoma who developed obstructive hydrocephalus and underwent craniotomy for the excision of a cerebellar hemangioblastoma combined with a laparoscopic adrenalectomy.

2. Case report

A 31-year-old man presented with a steady, gradually increasing, headache that had persisted for the previous 3 months. He was admitted to the emergency room of another hospital for a severe headache. His symptoms suggested intracranial hypertension. Magnetic resonance imaging (MRI) showed areas of abnormal enhancement in the left cerebellum, which were revealed to be a hemangioblastoma with mass effect causing obstructive hydrocephalus (Fig. 1). He was then referred to our hospital. On

* Corresponding author. Fax: +81 88 632 9464.

E-mail address: mizo@vj8.so-net.ne.jp (Y. Mizobuchi).

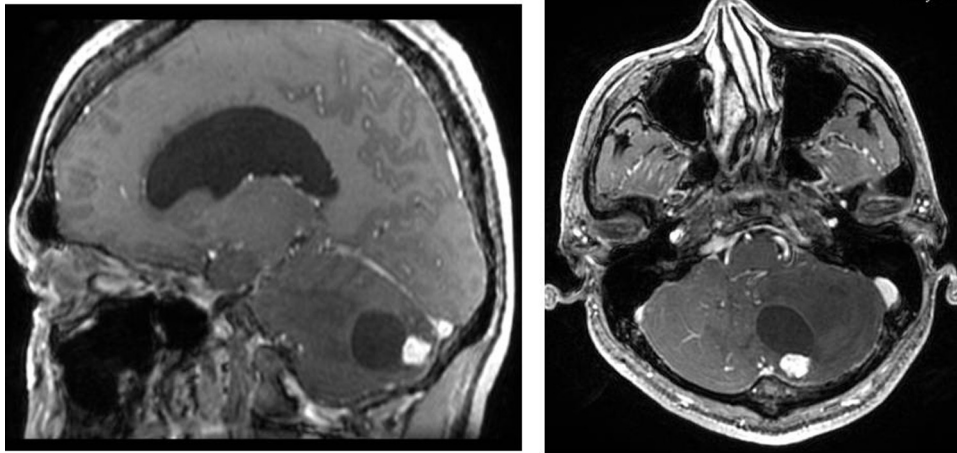


Fig. 1. Axial (left) and sagittal (right) T1-weighted magnetic resonance images with gadolinium demonstrating a left cerebellar hemangioblastoma with a mural node causing obstructive hydrocephalus.

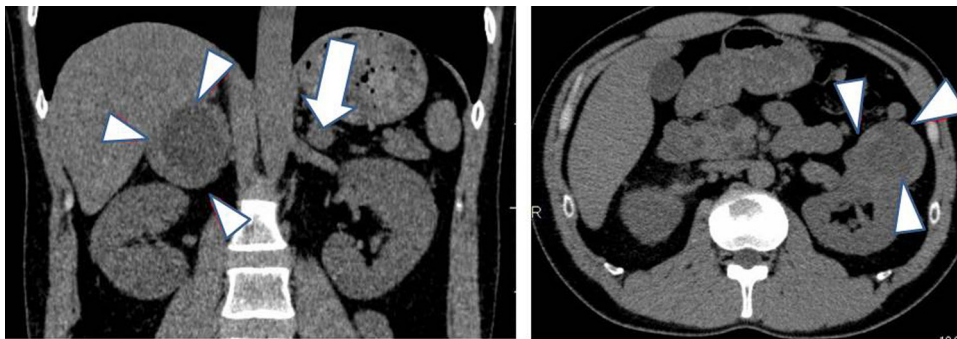


Fig. 2. Abdominal CT scan showing bilateral adrenal tumors (the right and left masses were 5.5 and 1.5 cm in diameter, respectively).

admission, his blood pressure and pulse rate were 220/120 mmHg and 110 bpm, respectively. His blood pressure rose abruptly following postural changes and mild abdominal compression. Fundus examination revealed a hemangioblastoma in the right eye, and neurological examination revealed truncal ataxia. Laboratory data showed increased levels of catecholamines and their metabolites in 24-h urine collection samples. Computed tomography (CT) of the abdomen revealed bilateral suprarenal tumors with a cyst and a 5-cm-diameter tumor in the left kidney (Fig. 2). The patient was diagnosed with VHL, and his severe headache and neurological symptoms suggested raised intracranial pressure (ICP). The day after admission, doxazosin mesilate treatment was started at a dosage of 8 mg/day to stabilize blood pressure. He was scheduled to undergo excision of a cerebellar hemangioblastoma after blood pressure was controlled with alpha- and beta-blockers.

However, on the third day, he presented with an increasing headache, decreased level of consciousness, hemiparesis, and uncontrollable hypertension. Doxazosin mesilate was increased to 16 mg/day; however, we were unable to perform a craniotomy because of abdominal compression in the prone position. Similarly, mild stimulation of abdominal flexion in a sitting position induced very high blood pressure. Thus, we performed ventricular drainage to control ICP. After ventricular drainage, the patient's consciousness level increased, and his headache was relieved. However, we judged that blood pressure stabilization by alpha-blockers would take time and that intraoperative blood pressure elevation by abdominal stimulation might result in intracranial pressure elevation either in the prone or sitting position. Moreover, there was concern that ICP control by ventricular drainage alone might further exacerbate the patient's symptoms, causing upward herni-

ation. On the fifth day, we decided to first perform a laparoscopic adrenalectomy on the patient in the supine position, considering the patient's general condition and intraoperative and postoperative invasiveness, in order to excise the pheochromocytoma. After blood pressure was stabilized, the patient was shifted to the prone position to excise the cerebellar hemangioblastoma. We performed a bilateral laparoscopic adrenalectomy to control ICP by ventricular drainage. Intraoperatively, we administered propofol, remifentanyl, phentolamine, landiolol, and a calcium blocker for blood pressure control, and the patient's serum adrenaline level increased from 4885 pg/mL to 16,148 pg/mL (~60–500 pg/mL). His blood pressure rose to 220 mmHg by mechanical stimulation when the tumor was compressed. However, after adrenalectomy, his serum adrenaline level decreased to 191 pg/mL, and the patient's blood pressure returned to normal (Fig. 3). Next, we changed the patient to the prone position and performed a craniotomy to remove the right cerebellar hemangioblastoma. The patient's neurological deficits were relieved postoperatively, no other deficits occurred, and no further hypertensive medication was required.

3. Discussion

Hemangioblastoma can occur in any part of the CNS, but the sites of predilection are the posterior fossa (80%) and spinal cord (20%). Almost 95% of infratentorial hemangioblastoma are located in the cerebellum, mainly in the hemispheres and less frequently in the vermis [5]. Cerebellar hemangioblastoma are highly vascular but benign tumors that account for ~2% of all intracranial tumors [6]. CNS hemangioblastomas occur in both type 1 (without pheochromocytoma) and type 2 (with pheochromocytoma)

Download English Version:

<https://daneshyari.com/en/article/4288874>

Download Persian Version:

<https://daneshyari.com/article/4288874>

[Daneshyari.com](https://daneshyari.com)