



Contents lists available at ScienceDirect

International Journal of Surgery Case Reports

journal homepage: www.casereports.com

The use of resuscitative endovascular balloon occlusion of the aorta to control hemorrhagic shock during video-assisted retroperitoneal debridement or infected necrotizing pancreatitis.



Adam S. Weltz*, Donald G. Harris, Natalie A. O'Neill, Lindsay B. O'Meara, Megan L. Brenner, Jose J. Diaz

R Adams Cowley Shock Trauma Center, University of Maryland Medical Center, Baltimore, United States

ARTICLE INFO

Article history:

Received 18 May 2015

Received in revised form 19 May 2015

Accepted 20 May 2015

Available online 30 May 2015

Keywords:

Hemorrhagic shock

Balloon occlusion

REBOA

VARD

ABSTRACT

INTRODUCTION: Resuscitative endovascular balloon occlusion of the aorta (REBOA) is a technique that has been shown to provide central vascular control to support proximal aortic pressure and minimize hemorrhage in a wide variety of clinic settings, however the role of REBOA for emergency general surgery is less defined.

CASE DESCRIPTION: This is a report of a 44 year old man who experienced hemorrhagic shock during video-assisted retroperitoneal debridement (VARD) for necrotizing pancreatitis where REBOA was used to prevent ongoing hemorrhage and death.

DISCUSSION: This is the first documented report REBOA being used during pancreatic debridement in the literature and one of the first times it has been used in emergency general surgery. The use of REBOA is an option for those in hemorrhagic shock whom conventional aortic cross-clamping or supra-celiac aortic exposure is either not possible or exceedingly dangerous.

CONCLUSION: REBOA allows for adequate resuscitation and can be used as a bridge to definitive therapy in a range of surgical subspecialties with minimal morbidity and complications. The risks associated with insertion of wires, sheaths, and catheters into the arterial system, as well as the risk of visceral and spinal cord ischemia due to aortic occlusion mandate that the use of this technique be utilized in only appropriate clinical scenarios.

© 2015 The Authors. Published by Elsevier Ltd. on behalf of Surgical Associates Ltd. This is an open access article under the CC BY-NC-ND license (<http://creativecommons.org/licenses/by-nc-nd/4.0/>).

1. Introduction

Necrotizing pancreatitis develops in approximately 20% of patients with acute pancreatitis, and it is associated with mortality rates of 11–39% [1]. Hemorrhagic complications account for approximately 50% of deaths with a higher risk of bleeding in the setting of pancreatic necrosis. Open debridement of infected necrotic pancreatic tissue has been the traditional treatment strategy in patients with infected pancreatic and peripancreatic tissue, but this strategy entails significant morbidity [2,3]. More recently, as an alternative to open necrosectomy, percutaneous drainage followed by minimally invasive video-assisted retroperitoneal debridement (VARD) via the “step up approach” has been shown to reduce mortality and rates of secondary complications such as hemorrhage [4].

Resuscitative endovascular balloon occlusion of the aorta (REBOA) is a technique that has been shown to provide central vascular control to support proximal aortic pressure and minimize hemorrhage in a wide variety of clinic settings including trauma, vascular populations and for patients undergoing pelvic surgery [5,6]. As an alternative to conventional resuscitative thoracotomy, REBOA has been shown to preserve myocardial and cerebral tissue perfusion in a less invasive fashion [5]. The procedure involves obtaining arterial access through the common femoral artery, inserting a large vascular sheath through which a balloon catheter can then be inflated in the appropriate section of the aorta to occlude blood flow [5]. For the purposes of endovascular control, the aorta is divided into three zones of bleeding. Zone 1 is in the descending thoracic aorta for abdominal hemorrhage, Zone 3 is below the renal arteries but above the aortic bifurcation for pelvic hemorrhage, and Zone 2 in the mid abdominal aorta with critical visceral branches is a proposed no-occlusion zone [5].

The use of REBOA in emergency general surgery patients has not been extensively described in the literature. We present a case

* Corresponding author at: 22 S. Greene Street, Baltimore MD 21201, United States. Tel.: +1 703 582 6543.

E-mail address: AWeltz@smail.umaryland.edu (A.S. Weltz).

where REBOA was used to prevent ongoing hemorrhage during VARD for the treatment of necrotizing pancreatitis.

2. Case presentation

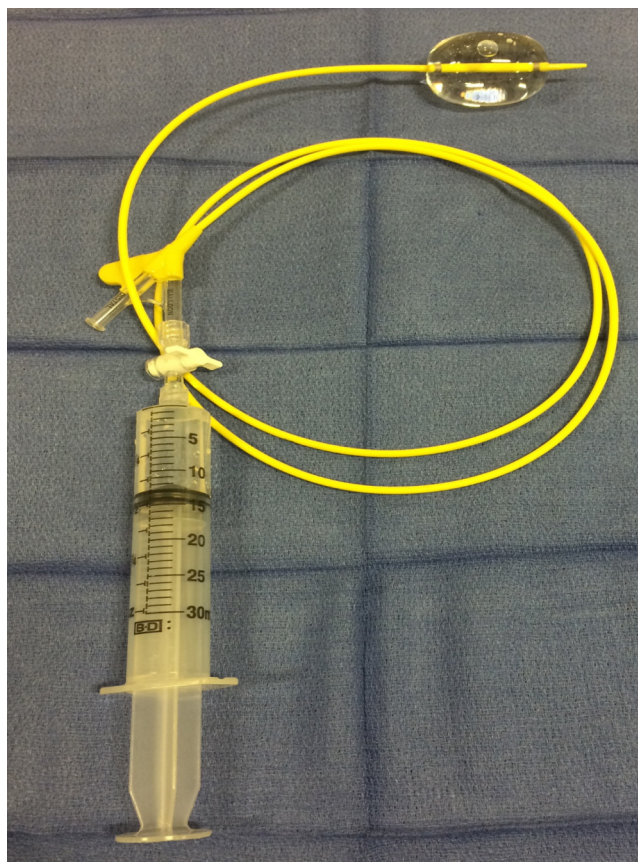
The patient is a 44-year old man who presented with gallstone pancreatitis. This progressed to severe, infected necrotizing pancreatitis complicated by respiratory failure and acute kidney injury. During his index admission, he was managed via the step up approach as described by Van Santvoort et al., [4]. Peripancreatic collections were drained by percutaneous left flank retroperitoneal catheters in the anterior and mid axillary lines, and after interval stabilization he returned for an elective VARD procedure and simultaneous cholecystectomy. Preoperative computed tomography demonstrated the drains to be within the lesser sac beside his pancreatic collections, which had gas foci indicative of ongoing infection.

Under general anesthesia, the drain sites were accessed for placement of 5–10mm trocars. A working thoracoscope was introduced into the retroperitoneum, where significant scarring, inflammation and necrosis were noted. Sharp pancreatic debridement with toothed forceps under direct visualization was initiated, but during the course of debridement, brisk arterial bleeding was encountered. The retroperitoneum was packed with hemostatic agents, and the patient was taken emergently to the interventional radiology suite for angioembolization of bleeding intercostal arteries. The patient was taken to the intensive care unit post-operatively for hemodynamic monitoring and resuscitation.

Forty-eight hours later, the patient returned to the operating room for removal of retroperitoneal packing and completion VARD. However, after removal of several large segments of necrotic debris, brisk arterial bleeding from what appeared to be the splenic capsule was encountered. The procedure was converted to a mid-line exploratory laparotomy. Upon entry into the peritoneum, dense vascularized adhesions were encountered that involved the entire left upper quadrant which prevented safe dissection of the splenic hilum. The patient developed hemodynamic instability with a mean arterial pressure below 50 mm Hg despite four quadrant packing. At this juncture, supra celiac clamping of the aorta appeared to be impossible due to the degree of vascular adhesions in this area and the decision was made to place a REBOA to gain vascular control.

The right groin was explored to expose and control the patient's right common femoral artery. Via open Seldinger technique [7], the vessel was accessed with a 20 Fr hollow bore needle and a 0.035 guidewire was inserted. Next a 5 Fr sheath was inserted, through which a 0.035 Bentson wire (Cook Incorporated, Bloomington, IN) was advanced into the thoracic aorta. The 5Fr sheath was then removed and upsized to a 14Fr sheath. Via this sheath, a 32 mm CODA balloon catheter (Cook Incorporated, Bloomington, IN) (See Picture 1) was inserted and deployed in the descending thoracic aorta. Landmarks as well as Intraoperative fluoroscopy confirmed wire and balloon placement.

Following balloon inflation, the patient's hemodynamics immediately improved and stabilized, enabling adequate resuscitation by anesthesia and further retroperitoneal packing. For definitive hemostasis, the REBOA balloon was slowly deflated, and



Picture 1. CODA 32 mm balloon mounted on 100 cm flexible 10 Fr catheter (Cook Incorporated, Bloomington, IN). Introduced via 14 Fr sheath.

angioembolization of a left intercostal artery was performed in the interventional radiology suite. He was subsequently stable without signs of bleeding, and the REBOA was removed and the femoral access site closed. No procedural complications occurred. Two days later the packing was removed, and completion necrosectomy and cholecystectomy were performed. After an 18-day hospital stay, the patient was discharged home and is doing well without gastrointestinal or vascular complaints.

3. Discussion

The use of REBOA in non-trauma general surgery patients is an option for those in hemorrhagic shock whom conventional aortic cross-clamping or supra-celiac aortic exposure is either not possible or exceedingly dangerous as we described here. Placement of a REBOA can be performed via simple femoral artery cut-down with catheter and balloon confirmation via external landmarks and fluoroscopy. REBOA allows for adequate resuscitation and can be used as a bridge to definitive therapy in a range of surgical subspecialties with minimal morbidity and complications. (See Table 1)

Balloon occlusion of the aorta to tamponade bleeding was first described during the Korean War in the 1950's on three wounded soldiers. Two soldiers were temporized long enough for exploratory

Table 1

Clinical use	Total patients, n	Mortality, n (%)	Complications, n (%)	References
Elective surgery	151	3 (2%)	9 (6%)	[10,11,17]
Trauma surgery	82	5 (6%)	2 (2%)	[6,8,9,13–15,18,19]
Emergency general surgery	1	0	0	[20]

Morbidity and mortality associated with REBOA use.

Download English Version:

<https://daneshyari.com/en/article/4288902>

Download Persian Version:

<https://daneshyari.com/article/4288902>

[Daneshyari.com](https://daneshyari.com)