



Contents lists available at ScienceDirect

International Journal of Surgery Case Reports

journal homepage: www.casereports.com

Endovascular stenting in malignant obstruction of superior vena cava

Julian Hamzik^a, Juraj Chudej^b, Anton Dzian^a, Juraj Sokol^{b,*}, Peter Kubisz^b^a Department of Thoracic Surgery, Jessenius Faculty of Medicine in Martin, Comenius University in Bratislava, Kollarova 2, 036 59 Martin, Slovakia^b Department of Haematology and Transfusion Medicine, National Centre of Haemostasis and Thrombosis, Jessenius Faculty of Medicine in Martin, Comenius University in Bratislava, Kollarova 2, 036 59 Martin, Slovakia

ARTICLE INFO

Article history:

Received 19 March 2015

Received in revised form 10 June 2015

Accepted 20 June 2015

Available online 26 June 2015

Keywords:

Hodgkin lymphoma

Stent

Superior vena cava syndrome

ABSTRACT

INTRODUCTION: Superior vena cava syndrome (SVCS) is obstruction of blood flow through the SVC. It is a medical emergency and most often manifests in patients with a malignant disease process within the thorax. A patient with SVCS requires immediate diagnostic evaluation and therapy.

PRESENTATION OF CASE: A 33-years-old woman presented with complaints of dyspnoea and chest pain. Computer tomography revealed a large mass in the anterior mediastinum. This mass compressed surrounding structures. Stenting was indicated for early symptoms of SVCS. The diagnosis of Hodgkin's lymphoma (HL) was confirmed with biopsy. The patient's stage II HL has been subsequently treated with six cycles of chemotherapy with doxorubicin, bleomycin, vinblastine, dacarbazine (ABVD), followed by radiotherapy. Presently she is doing well.

DISCUSSION: Although lymphomas are a common cause of SVCS but almost always SVCS is caused by non-Hodgkin's lymphoma (NHL). HL despite its common presentation with mediastinal lymphadenopathy rarely causes SVCS.

CONCLUSION: Lymphomas are a common cause of SVCS in young age. HL may present as SVCS. Pathological confirmation of diagnosis should be done before initiating therapy while dealing with a case of SVCS. SVC stenting is effective and has few complications in patients with SVCS.

© 2015 The Authors. Published by Elsevier Ltd. on behalf of Surgical Associates Ltd. This is an open access article under the CC BY-NC-ND license (<http://creativecommons.org/licenses/by-nc-nd/4.0/>).

1. Introduction

The mediastinum is the cavity that separates the lungs from the rest of the chest [1]. More than two thirds of mediastinal tumors are benign, masses in the anterior compartment are more likely to be malignant [2]. Localizing symptoms are secondary to tumor invasion. Common localizing symptoms include respiratory compromise, dysphagia, paralysis of the limbs, diaphragm, and vocal cords, Horner syndrome, and superior vena cava syndrome (SVCS). Systemic symptoms are typically due to the release of excess hormones, antibodies or cytokines [3].

SVCS includes various clinical signs and symptoms due to external compression of the SVC itself or greater veins emptying into the SVC or the superior cavo-atrial junction, resulting in reduced blood flow. The assessment of a patient with SVCS must be prompt. The optimal treatment choice should be decided with an interdisciplinary consensus [4]. Although lymphomas are a common cause of SVCS but almost always SVCS is caused by non-Hodgkin's lymphoma (NHL). Hodgkin's lymphoma (HL) despite its common

presentation with mediastinal lymphadenopathy rarely causes SVCS [5].

2. Presentation of case

A 33-years-old woman was hospitalized at the Department of Pulmonology and Phthysiology, Martin University Hospital with mediastinal mass finding on conventional chest radiography in October 2011. The patient was hospitalized on the recommendation of local pulmonologist, who ordered a chest X-ray for differential diagnosis of dyspnoea and chest pain. It revealed homogeneous dark area on the right chest side.

The patient reported a two-week history of progressive dyspnoea after exertion, dry irritating cough, and mild chest pain. She complained from night sweats but without fever. She also referred with a weight loss of 10 kg for the last 3 weeks. She had no experience with chest oppressions or heart palpitations but she suffered from occasional dizziness.

On physical examination, temperature was normal, blood pressure was 130/80 mm Hg in both arms, pulse rate is 96/min, and respiration rate is 26/min. Pulses were symmetric and equal in all extremities. There was marked facial oedema. The skin was pale, anicteric, with no signs of bleeding or peripheral cyanosis. Her neck veins were distended, prominent veins were present on whole of the chest wall and the flow in these veins was from above down-

* Corresponding author. Fax: +421 43 4122061.

E-mail addresses: julian.hamzik@jfm.uniba.sk

(J. Hamzik), durochudej@pobox.sk (J. Chudej), anton.dzian@centrum.sk (A. Dzian), juraj.sokol@me.com (J. Sokol), kubisz@jfm.uniba.sk (P. Kubisz).

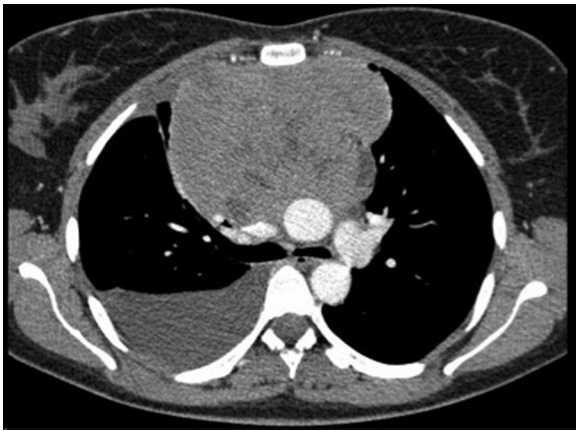


Fig. 1. Postcontrast CT images at the level of crossing of left brachiocephalic vein and arch of aorta showing a large homogeneously enhancing mass lesion in anterior mediastinum (October, 2011).

wards. On examination of respiratory system there was dullness on percussion over right side of chest at infraclavicular, suprascapular and interscapular areas, vocal resonance and vocal fremitus was also reduced in these areas and there were decreased intensity of breath sounds in these areas. Heartbeat was regular, without murmurs. The liver did not exceed the costal margin, the spleen was not felt and there was no mass in the abdomen. Peripheral lymphadenopathy was not present.

According to medical records, in June 2000, she underwent appendectomy. There was no other personal or family history. She had allergic contact dermatitis from nickel.

Based on classical clinical features of swelling over upper body, dilated veins over neck and chest, dyspnoea and dysphagia a provisional diagnosis of SVCS was made and she was investigated further.

2.1. Investigations

Laboratory tests on the day of admission revealed mild anaemia (haemoglobin level 11 g/dL). Total leucocyte count was 8500/mm³ and differential leucocyte count was neutrophils 71% and lymphocytes 29%. The biochemical tests like liver and renal function tests were within normal limits. Bronchoscopy demonstrated stenosis of the right lower lobe bronchus. Segmental bronchi were also closed. Computed tomography (CT) scan revealed a mass in anterior mediastinum. This mass compressed the surrounding vascular structures (Fig. 1). Therefore, a thoracic surgeon was consulted. Anterior mediastinotomy was indicated. In early October, the oper-

ation was performed for tissue biopsy and pleural effusion. For early symptoms of the SVCS a stent was inserted into the SVC (Fig. 2). The procedure was performed with the patient under local anaesthesia (1% mesocain) in the angiographic suite (equipped with a fluoroscopic machine; Siemens, Munich, Germany) and was performed by an interventional team assisted by an anaesthesiologist for cardiocirculatory and airway support. Intubation was not necessary. Venography was performed to evaluate the location, length, and severity of the stenosis. The right common femoral vein was used as the approach site to access the SVC. After puncture of femoral vein, a 6-F sheath was inserted. The stenosis of the SVC was negotiated with a 5-F catheter and a 0.035-in hydrophilic guidewire that was 150 cm in length. The pressure gradient between the brachiocephalic vein or the internal jugular vein and the right atrium was measured before inserting the stent. Predilation was performed with a 6 mm (diameter) balloon catheter to determine stent size and to facilitate easy navigation of the stenosis and placement of the stent. We used the self-expanding nitinol Sinus-XL stent (OptiMed, Ettlingen, Germany). Heparin (4000 units) was administered intravenously prior to these procedures. Warfarin administration was continued for 18 months followed by aspirin administration (81 mg/day). The postoperative period passed without any complications. Histologic analysis revealed a Hodgkin's lymphoma (HL). Therefore, the patient was moved to the Department of Haematology and Transfusiology in order to start treatment and complete the staging. In the beginning of the first hospitalization the trephine biopsy excluded infiltration of bone marrow.

2.2. Treatment

The first cycle of ABVD immunochemotherapy was administered in early November. ABVD is an acronym for different chemotherapeutic drugs. "A" stands for adriamycin; "B" for bleomycin; "O" for vinblastine; and "D" for dacarbazine. All drugs were given intravenously on days 1 and 15 (doxorubicin 25 mg/m², bleomycin 10 mg/m², vinblastine 6 mg/m² and dacarbazine 375 mg/m²). The treatment was repeated every 4 weeks.

2.3. Outcome and follow-up

After four cycles of chemotherapy CT showed regression of tumor, so it was decided to continue with the treatment (Fig. 3). The last (sixth) cycle of chemotherapy was administered in March 2012. Restaging CT examination revealed persistent tumor 6 × 5 × 3 cm in size. Based on this finding, external radiotherapy (ERT) in mediastinal region was indicated. The ERT consisted of a dose of 36 Gy in 6 fractions over.

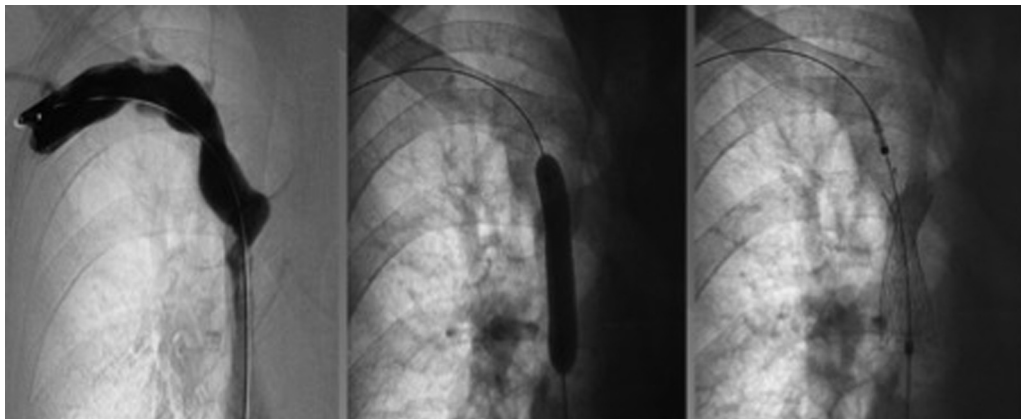


Fig. 2. Angiography shows SVC stenting in our patient.

Download English Version:

<https://daneshyari.com/en/article/4288921>

Download Persian Version:

<https://daneshyari.com/article/4288921>

[Daneshyari.com](https://daneshyari.com)