



Contents lists available at ScienceDirect

International Journal of Surgery Case Reports

journal homepage: www.casereports.com

Normalization of chromium and cobalt values after femoral head replacement



Claudio Iacobellis^{a,*}, Antonio Berizzi^a, Assunta Pozzuoli^b, Carlo Biz^a

^a Orthopaedic Clinic, Department of Surgery, Oncology and Gastroenterology DISCOG University of Padua, via Giustiniani 2, 35128 Padova, Italy

^b Histology, Microbiology and Medical Biotechnology, University of Padua, via Giustiniani 2, 35128 Padova, Italy

ARTICLE INFO

Article history:

Received 28 November 2014
Received in revised form 7 March 2015
Accepted 20 March 2015
Available online 27 March 2015

Keywords:

ARMD
Metallosis
Metal ion levels
Metal on metal hip arthroplasty

ABSTRACT

INTRODUCTION: Adverse reaction to metal debris (ARMD) can be caused by metal-on-metal total hip arthroplasty. We treated a case of ARMD in a 61-year-old patient by limited prosthetic revision, replacing the metal head with a polyethylene one.

PRESENTATION OF CASE: Two years after metal-on-metal total arthroplasty of the left hip, radiographic control showed osteolysis of the patient's greater trochanter. He underwent surgical curettage and the application of demineralized bone matrix. After a few months, blood Co and Cr increased, and at clinical evaluation, the patient had worsening paresthesias. He agreed to prosthetic revision after 14 months.

DISCUSSION: During surgery, the acetabular cup and femoral stem appeared correctly osteointegrated; therefore, the cup was maintained, while the prosthetic femoral head was removed and replaced with a 50 mm polyethylene head.

CONCLUSION: Blood Cr and urinary Cr and Co decreased and normalized 3 months after surgery, and the patient no longer suffered paresthesias. Blood Co normalized 7 months after revision. Radiographic follow-up showed no change after 30 months post-operatively. We believe this case report could be a starting point for a future randomized clinical trial to test the efficacy of the procedure used compared with complete implant revision.

© 2015 The Authors. Published by Elsevier Ltd. on behalf of Surgical Associates Ltd. This is an open access article under the CC BY-NC-ND license (<http://creativecommons.org/licenses/by-nc-nd/4.0/>).

1. Introduction

In recent years, metal-on-metal total hip arthroplasties (THAs) have been widely used because of their big femoral heads and thin profile acetabular cups with high stability and reduced wear. These implants have caused major problems due to a high incidence of adverse reactions to metal debris (ARMD) [1,2] and related pathologies (polyneuropathies, renal, cardiac, and thyroid alterations) [3–5] that lead to implant removal [6,7]. The aim of this report is to show how the treatment of an ARMD case with prosthetic revision limited to metallic head substitution allowed good clinical and toxicological results, resolving the complicated case.

2. Presentation of case

In January 2003, a 55-year-old bricklayer (height 170 cm, weight 86 kg, non-smoker) underwent an uncomplicated primary implant of a ceramic–ceramic total hip arthroplasty (Lima Corporate, Italy)

* Corresponding author. Tel.: +39 49 8213343; fax: +39 49 8213365.

E-mail addresses: claudio.iacobellis@unipd.it (C. Iacobellis), antonio.berizzi@unipd.it (A. Berizzi), assunta.pozzuoli@unipd.it (A. Pozzuoli), carlo.biz@unipd.it (C. Biz).

<http://dx.doi.org/10.1016/j.ijscr.2015.03.037>

2210-2612/© 2015 The Authors. Published by Elsevier Ltd. on behalf of Surgical Associates Ltd. This is an open access article under the CC BY-NC-ND license (<http://creativecommons.org/licenses/by-nc-nd/4.0/>).

at our institution for painful right hip coxarthrosis. At time of surgery, the patient was healthy. By Prick Test, he was found allergic to concrete, rubber, plastic, and latex; no allergies for food and drugs were found. The patient had a normal postoperative course with excellent results. After 11 years, the right hip was very mobile and without any pain, and radiographic follow-up was within normal limits (Fig. 1).

In October 2008, due to constant painful coxarthrosis of the left hip, the patient underwent uncomplicated total hip arthroplasty with primary anterior-lateral approach. Components included a PLS 158 mm femoral stem (Lima Corporate, Italy) and a large-diameter metal-on-metal bearing (56 mm metal cup and 50 mm head). The post-operative course was normal. The patient started bearing weight a few days after surgery, and the left hip presented almost complete mobility with 10° reduction in intra-rotation, maintained in later follow-up. One year after, both clinical and radiological evaluations were within normal limits.

In 2010, the patient was doing well, without complaints, fever, or hip pain. However, antero-posterior and lateral radiographs revealed a bone density reduction in the left greater trochanter and mild bone rarefaction of the acetabular cup on the medial side (Fig. 2). Laboratory analysis showed a CRP level of 15 mg/L (normal range 0–6 mg/L).

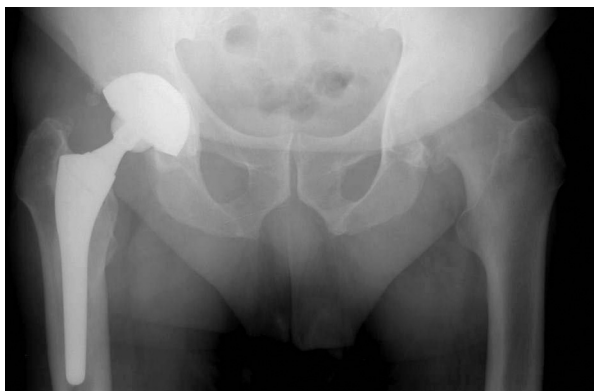

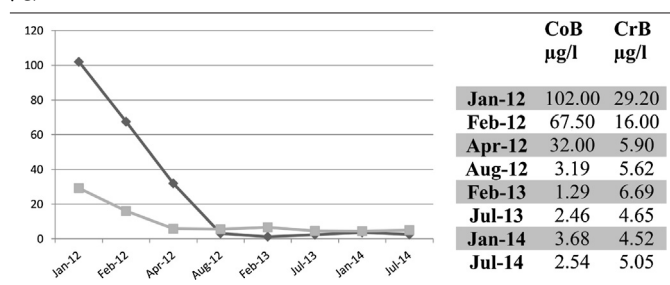
Fig. 1. Left hip pre-operative X-ray and primary implant of the ceramic–ceramic total hip arthroplasty on the right hip after 11 years follow-up.

Therefore, in November 2010, 25 months after the initial procedure, the patient underwent prosthetic surgical revision. Intraoperatively, grayish caseous material was evident, once the greater trochanter was exposed. Creamy lead gray material spurted out from the hip articulation, occupying most part of trochanteric area (Fig. 3A). The stem appeared well fixed and stable. The remaining lytic area was filled with 11 cc of demineralized bone matrix (DBX by Synthes) and closed with the residual thin trochanteric wall (Fig. 3B). Histological sample examination confirmed metallosis, revealing amorphous fibrous material with marginal necrotic areas and inflammatory lymphocytic infiltrate, coupled with necrotic bone spicules and hemosiderin macrophages. Microbiological samples revealed no infection.

During 2 months follow-up, 20 cc of serum-hematic fluid were drawn weekly. At radiographic control (2 months after surgery), trochanteric lysis was no more visible and periarticular ossifications were evident (Fig. 4). There were no more articular effusions, but the patient complained of paresthesias in the whole left leg and foot. There was indication for surgical revision and prosthetic

Table 1

Blood cobalt (black) and blood chromium (gray) concentration during follow-up in $\mu\text{g/L}$.



replacement. The patient refused it, preferring further clinical evaluation in 9 months time.

In September 2011, he developed swelling of his left thigh in the trochanteric region (from which 50 cc of grey fluid were drawn) and paresthesias (extending from his left leg to his foot). In February 2011, blood values of Cr and Co were $94.50 \mu\text{g/L}$ and $28.80 \mu\text{g/L}$, respectively. The radiographic control resulted unvaried, and the patient refused a new operation.

In January 2012, 14 months after the previous surgery, because of the persistence of his left hip and lower limb symptoms, the patient agreed on single-stage arthroplasty revision. Blood values of Cr and Co were $102.00 \mu\text{g/L}$ and $29.20 \mu\text{g/L}$, respectively, while their urinary values were $422.00 \mu\text{g/L}$ and $84.50 \mu\text{g/L}$ (Tables 1 and 2). There was no reflex deficit or muscular strength deficit. During surgical preparation, blood tests indicated a hemolysis compatible with autoimmune hemolytic anemia. Non-complement-fixing IgG class autoantibodies were found attached to red blood cells. The study of subclasses revealed the presence of IgG1 and IgG3 at a low titer of 1:1. Anesthesiologist colleagues planned a possible therapy with cortisone drugs and antihistaminergic drugs in case of blood transfusion, which proved unnecessary.

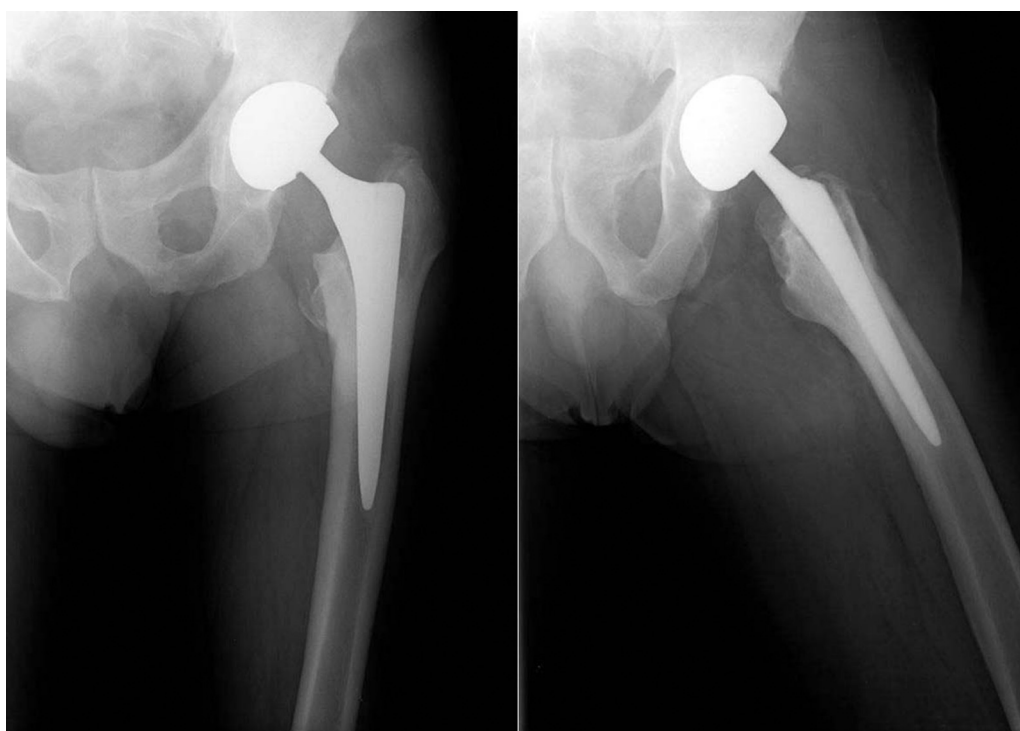


Fig. 2. Osteolysis of the greater trochanter at 2 year X-ray follow-up.

Download English Version:

<https://daneshyari.com/en/article/4288975>

Download Persian Version:

<https://daneshyari.com/article/4288975>

[Daneshyari.com](https://daneshyari.com)