

Contents lists available at [ScienceDirect](http://www.sciencedirect.com)

## International Journal of Surgery Case Reports

journal homepage: [www.casereports.com](http://www.casereports.com)

# Lumbar nerve rootlet entrapment by an iatrogenically spliced percutaneous intra-thecal lumbar cerebrospinal fluid catheter



James J. Yue\*, Carlos A. Castro, David Scott

Department of Orthopaedic Surgery, Yale School of Medicine, 800 Howard Avenue, P.O. Box 208071, New Haven, CT 6520, USA

## ARTICLE INFO

## Article history:

Received 17 September 2014

Received in revised form 6 January 2015

Accepted 7 January 2015

Available online 10 January 2015

## Keywords:

Intra-thecal spinal catheter

Retention

Splicing

Fragmentation

Double dot sign

Complication

## ABSTRACT

**BACKGROUND:** Complications associated with the use of percutaneous intra-thecal lumbar indwelling spinal catheters include infection, hematoma, neurologic dysfunction, and persistent undesired retention among others. A case of iatrogenic splicing associated with neurologic dysfunction with the use of a percutaneous intra-thecal indwelling spinal catheter is presented in this study.

**METHOD:** Single case study review.

**RESULTS:** Review of case materials indicate Y pattern splicing/fragmentation of an indwelling intra-thecal catheter causing neurologic dysfunction and resistance to removal during attempted removal. Pain and weakness were evident soon after insertion of the catheter and were amplified with attempted catheter removal. Computed tomography revealed a double dot sign on axial view and a Y appearance on sagittal view. Surgical findings revealed entrapment of nerve rootlets in the axilla of the spliced catheter.

**CONCLUSIONS:** Splicing/fragmentation causing neurologic dysfunction as well as catheter retention is described as a potential complication of intra-thecal indwelling cerebrospinal fluid catheters. A symptom of fragmentation of a catheter may include neurologic dysfunction including pain and weakness of a lumbar nerve root. If resistance is experienced upon attempted catheter removal, with or without associated neurologic dysfunction, further attempts at removal should not be attempted. In those cases in which pain and/or lumbar weakness are evident post catheter placement and/or following attempted removal, computed tomography should be performed. If fragmentation of a catheter is evident on CT scan, spinal surgical consultation should be obtained. Recommended spinal surgical intervention includes an open durotomy and visualization of catheter fragments and nerve rootlets and removal of catheter fragments.

© 2015 The Authors. Published by Elsevier Ltd. on behalf of Surgical Associates Ltd. This is an open access article under the CC BY-NC-ND license (<http://creativecommons.org/licenses/by-nc-nd/4.0/>).

## 1. Introduction

Intra-thecal cerebrospinal catheters are often used for anesthetic as well as for cerebrospinal decompressive purposes. Complications such as intra-pleural migration, local hematoma, intra-cranial subdural hematoma, cranial nerve dysfunction, placement of catheter in pulmonary vessels, infection, neurologic changes, cerebrospinal fluid leak and associated headaches, pseudo meningocele formation, tip granulomas, complete fracturing, catheter migration and others have been described [1–16]. To the best of our knowledge, the complication of intra-thecal splicing and nerve root entrapment with subsequent neurologic dysfunction and catheter retention has not been described.

## 2. Case presentation

V.M. is an 82 year old female who presented to the emergency department for the worsening of chronic lower back pain over a 3

day period. On the day of admission, her pain was unrelieved with pain medications and the patient remained prostrate.

Subsequent imaging and workup revealed an aneurysm of the aorta from her proximal descending thoracic aortic to her iliac bifurcation with aneurysm of the abdominal aorta (AAA) portion from 8.5 cm to 10 cm. Patient was hemodynamically stable and was admitted to the vascular surgery service.

The patient declined open repair of her aneurysm defects. Instead, she elected endovascular repair with initial repair of the descending thoracic aortic aneurysm (TAA) portion and staged extension with a fenestrated abdominal aortic stent graft.

After admission, the patient was brought to the operating room for endovascular repair followed by placement of a lumbar drain (EDM Lumbar Catheter, Closed Tip Medtronic Neurosurgery, Goleta, CA, USA) at the L3–4 interspace by the anesthesia service to decrease the potential complication of paraplegia increasing the perfusion pressure to the spinal cord [17].

On post-op day 1, the patient noted pain in the right anterior thigh as well as right hip flexor weakness. Neurology was consulted with suspicion for right plexopathy. Her motor exam was notable for 4/5 weakness of right hip flexor (psoas L1–2), 4/5 right

\* Corresponding author. Tel.: +1 203 785 3714; fax: +1 203 785 7132.

quadriceps (femoral nerve L3–4) and 4/5 right hamstring strength (sciatic nerve S1). No clear weakness of adductor of hip (obturator L2–3) or abductor of hip (gluteus medius S1). No weakness of right ankle dorsiflexors, inverters, everters, plantar flexors or right EHL. No weakness of the left leg lower extremity was noted. Pulses were dopplerable bilaterally.

Sensation was normal and symmetric to light touch of both legs L2–S1. Subjective decreased vibration on the right patella. Symmetric vibratory sensation was present on the great toes, medial and lateral ankle malleoli and both shins (proximal and distal).

Computed tomography examination at that time showed no evidence of retroperitoneal or psoas hematoma.

On post-op day 2, the patient's right leg weakness slightly improved but on the morning of post-op day 3, an attempt at catheter removal was unsuccessful due to resistance. During the attempted removal, the patient experienced severe burning down the anterior lateral aspect of her right thigh and lower leg. The right hip flexor weakness also worsened. No further attempts of catheter removal were attempted. Subsequently, the patient began having episodes of bowel and bladder incontinence. No long tract findings were evident.

The spine surgery service was consulted and obtained an MRI that showed no discernible significant epidural hematoma from L3 down to S1 (Fig 1). However from L3 proximal, it was difficult to appreciate due to metal artifact.

A CT scan was ordered and showed a catheter that appeared spliced and coiled within the thecal sac (Fig. 2A and B-3). Axial view of the CT scan revealed a double dot appearance representing a section through a coiled catheter (Fig. 3). On POD 4, the patient was brought to the operating room for removal of the retained lumbar spinal catheter (Fig 4).

An incision approximately 6 cm in length was made proximally and distally centered over the L3–L4 spinous processes, careful dissection down to the intervertebral interlaminar space was performed. The distal aspect of L3 and the proximal aspect of L4 of the spinous process were removed. The ligamentum flavum and lamina were also removed. The catheter was followed down to the dura and a 4 mm durotomy was made in a distal direction below the catheter. A nerve hook placed within the thecal sac and control of the spliced portion of the catheter was obtained. A small nerve rootlet was identified in the Y portion of the spliced catheter. Once the spliced portion of the catheter was released from the rootlet,

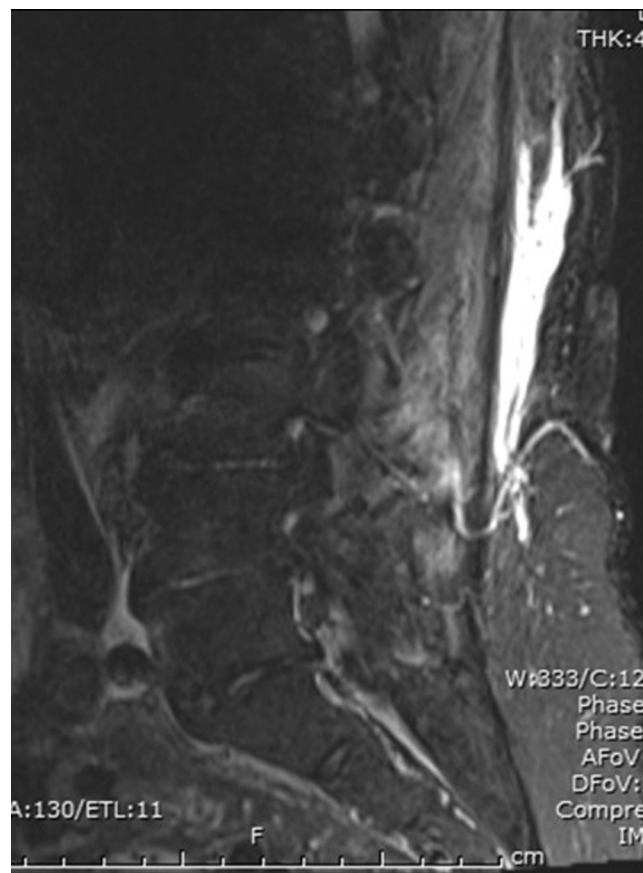


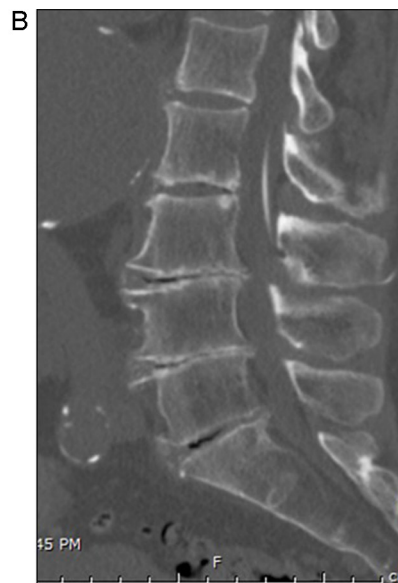
Fig. 1. Sagittal MRI of lumbar spine.

the remaining Y portion and the contiguous distal aspect of the catheter was removed without difficulty (Fig 5). Lastly, the dura was repaired in watertight sealed manner.

Patient was discharged to rehab on 4 days after catheter removed with slight anterior thigh pain and without significant recovery of her right thigh strength. The patient's thigh strength was noted to be normal by 3 months after index surgery with no CSF complications. Patient recovered full motor, sensory as well as

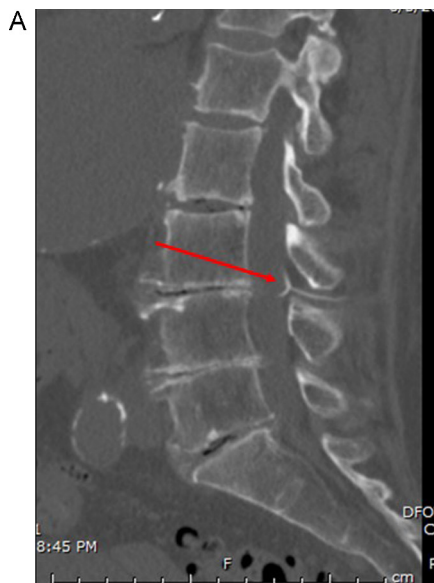

Fig. 2. Sagittal view of lumbar spine.



Note Y slice appearance in Fig. 2A.

Download English Version:

<https://daneshyari.com/en/article/4289145>

Download Persian Version:

<https://daneshyari.com/article/4289145>

[Daneshyari.com](https://daneshyari.com)